

A supplement to

# Ophthalmology Times

EUROPE

November 2009

# Blue laser autofluorescence

The fusion of imaging technology for today and  
tomorrow to assess your patients' retinal health

**HEIDELBERG**  
**ENGINEERING**

bluepeak<sup>TM</sup>



# Blue laser autofluorescence

The fusion of imaging technology for today and tomorrow to assess your patients' retinal health

Over the past decade and a half powerful imaging and diagnostic technology has been revolutionising the clinical practice of the general ophthalmologist, particularly in relation to retina health. Fundus autofluorescence imaging is a fast emerging, non-invasive technique that is set to become available and accessible to the general practitioner rather than just the retinal specialist.

The Fundus Autofluorescence (FAF) phenomenon was identified in the early days of fluorescein angiography, in the late 1960s, but it is only in the last 15 years that ophthalmologists have taken advantage of it for clinical and research purposes.

Today, FAF allows both the general ophthalmologist and the retinal specialist to understand the nature of their patients' macular and retinal disease. By providing more detailed information on the pathophysiology of disease that is above and beyond that provided by more conventional methods such as fundus photography, fluorescein angiography and OCT, ophthalmologists can be more confident in the accuracy of their diagnosis and therefore their treatment choices.

At a more scientific level, "It is an opportunity to visualise the biochemistry of the retinal pigment epithelium," says Dr Frank Holz, at the Department of Ophthalmology at the University of Bonn in Germany, a leading expert into the study of autofluorescence.

## So what is fundus autofluorescence?

FAF imaging is a fast and non-invasive technique developed over the last decade, using the fluorescent properties of a metabolic indicator called lipofuscin to study the health and viability of the retinal pigment epithelium/photoreceptor complex.

Whilst there are other fluorophores in the outer retina that may occur with disease, lipofuscin is the dominant source of intrinsic fluorescence of the ocular fundus which was established by the ground-breaking work of Francois Delori *et al.*<sup>1</sup> Excessive accumulation of lipofuscin granules in the lysosomal compartment of RPE cells represents a common downstream pathogenetic pathway in various hereditary and complex retinal diseases, including age-related macular degeneration (AMD).<sup>2</sup>

## References

1. F.C. Delori *et al.*, *Invest Ophthalmol Vis Sci* 1995;36:718-29.
2. *Retina* 28:385-409, 2008.

# Technology options for FAF

Options for detecting autofluorescence fall mainly into two areas, namely those based on confocal scanning laser ophthalmoscopy (cSLO) and those based on a modified fundus camera

According to Dr Howard F. Fine, MHS, medical director of the Gerster Clinical Research Centre in Vision at Columbia University, US in a recently published article in *EyeNet* magazine: "There is a big divide between autofluorescence systems that are based on fundus cameras and those based on SLO systems."

However, they do share common challenges in that the naturally occurring intrinsic fluorescence of the ocular fundus is quite low – about two orders of magnitude lower than the background of a fluorescein angiogram even at the most intense part of the dye transit, injected into the eye prior to screening.<sup>1</sup> "The advantages of camera-based systems are that they are quicker, easier for the photographer to use and less expensive than the cSLO systems," claims Dr Fine. "The advantage of cSLOs is that they produce very high quality images, focused directly on the target issue of interest," according to Dr Fine.

## Confocal Scanning Laser Ophthalmoscopy

Confocal Scanning Laser ophthalmoscopy (cSLO), first developed by Webb *et al.*,<sup>2</sup> and initially applied by von Ruckmann *et al.*<sup>3</sup> for autofluorescence recordings is a focused low-power laser beam that sweeps across the fundus in a raster pattern.<sup>4</sup> It allows imaging over large retinal areas and by recording a series of several single images it reduces background noise and provides high quality image and contrast. Different cSLOs have been relatively widely used for obtaining FAF images and a study (Bellman *et al.*,<sup>5</sup>) observed significant differences in image contrast and brightness as well as in the range of grey values, which are important indicators for image quality between different cSLO devices.

## cSLO v the modified fundus camera

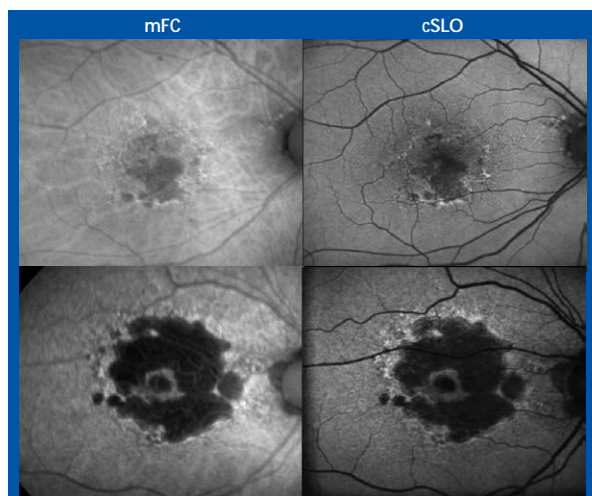
According to Dr Schmitz-Valckenberg: "It remains unclear if FAF findings obtained with cSLO are always comparable with those obtained with the fundus camera based system. For example, the use of different excitation wavelengths and emission filters between both systems may have an impact on the autofluorescence intensity distribution in pathologic conditions. Another possible confounding factor could be the absence of confocal optics in the fundus camera. The fluorescence of the natural lens and light scattering from retinal layers anterior and posterior to the layer of interest could cause large alterations in the detected image."

The cSLO scans the retina continuously and is immediately digitized. The image appears on a computer screen and adjustments can be made in real time. Acquiring images with a modified fundus camera allows for modification of more settings. This means more choice for the operator but it could possibly prove difficult or time-consuming to find the correct settings for an individual patient.

Table 1: Summary of technical differences between the cSLO and the modified fundus camera for fundus autofluorescence imaging.

Confocal Scanning Laser Ophthalmoscopy (cSLO)	Modified Fundus Camera (mFC)
One excitation wavelength (laser source)	Bandwidths filters for excitation and emission
Large emission spectrum (cut-off filter)	
Continuous scanning at low light intensities in a raster pattern	One single flash at maximum intensities
Confocal system	Entire cone of light
Laser power fixed by manufacture, gamma detector sensitivity	Flash light intensity, gain and of detector adjustable.
Automatic real time image processing with averaging of single frames and pixel normalization	Manual contrast and brightness

Standard operation procedures for the cSLO make it easy to acquire FAF images.<sup>6</sup> Dr Schmitz-Valckenberg is confident that "the extensive experience in large multi-centre clinical trials will now carry over to FAF application also in generalist offices on a daily basis."



Examples of Geographic Atrophy in two patients - the images on the left are from a modified fundus camera (mFC). The confocal scanning laser ophthalmoscopy (cSLO) on the right, show greater detail. Photo courtesy of The Bonn Group.

### A new blue perspective

Heidelberg's Spectralis models are a combination of cSLO fundus imaging and Spectral-Domain OCT imaging. There are currently six models and four of these are enabled with blue laser autofluorescence (BluePeak™). The imaging procedure is completely non-invasive without the need to inject any dye into the eye. Use of a pure blue laser can provide clear, high-contrast images of metabolic activity without the scattered light and the low sensitivity inherent in flash photography.

BluePeak – blue laser autofluorescence can be combined with SD-OCT. This fusion of technologies offers multi-modality imaging with BluePeak and SD-OCT and provides ophthalmologists with a new perspective on the structure-function relationship within the retina.

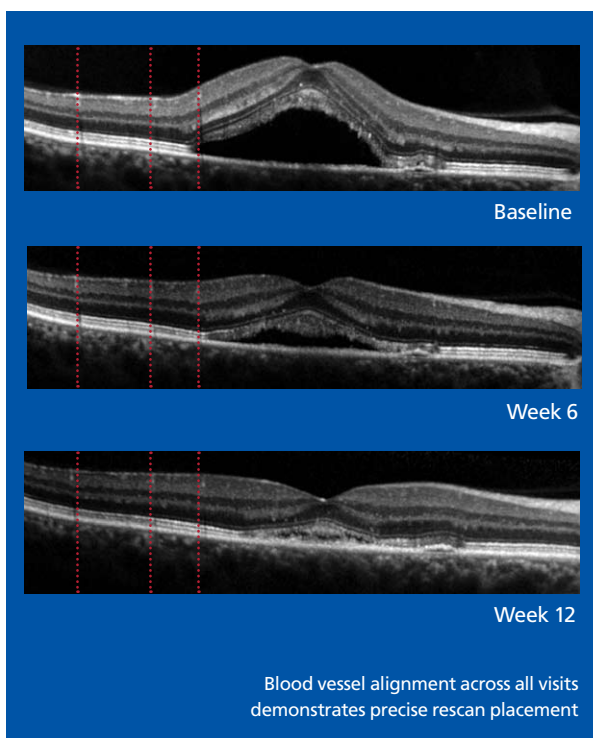
### References

1. S. Schmitz-Valckenberg *et al.*, *American J of Ophthalmology* 2008;146:2:183-192.
2. R.H. Webb *et al.*, *Appl Optics* 1987;26:1492-1499.
3. A. von Ruckmann *et al.*, *Br J Ophthalmol* 1995;79:407-412.
4. F.C. Delori, *Appl Optics* 1994;33:7429-52.
5. C. Bellman *et al.*, *Br J Ophthalmol* 2003;87:1381-6.
6. S. Schmitz-Valckenberg, V. Luong, F. Fitzke, F.G. Holz. How to obtain the optimal fundus autofluorescence image with the cSLO. In: F.G. Holz, S. Schmitz-Valckenberg, R.F. Spaide, A. Bird, *eds.* Atlas of Autofluorescence Imaging. Berlin Heidelberg: Springer, 2007.

# Integrating FAF imaging in daily practice

Confocal scanning laser ophthalmoscopy technology acquires images relatively easily, requires little time and is non-invasive,<sup>1</sup> confirms Dr Holz. "The retina is scanned continuously; the actual image is immediately digitized and appears on a

computer screen. Orientation and position of the laser scanning camera, detector sensitivity and refractive correction can be easily adjusted as the image is being acquired and can be done in real time by the operator. This practical and easy feasible mode of imaging is only possible because of the high sensitivity and the relatively low light levels of the cSLO. Nevertheless, it is important to optimally adjust these three modifiable settings in order to achieve good image quality and to gain reliable information from these recordings. Users of the Spectralis BluePeak models benefit from an automatic sensitivity control which simplifies the image acquisition process."



### Accommodating small and large practices

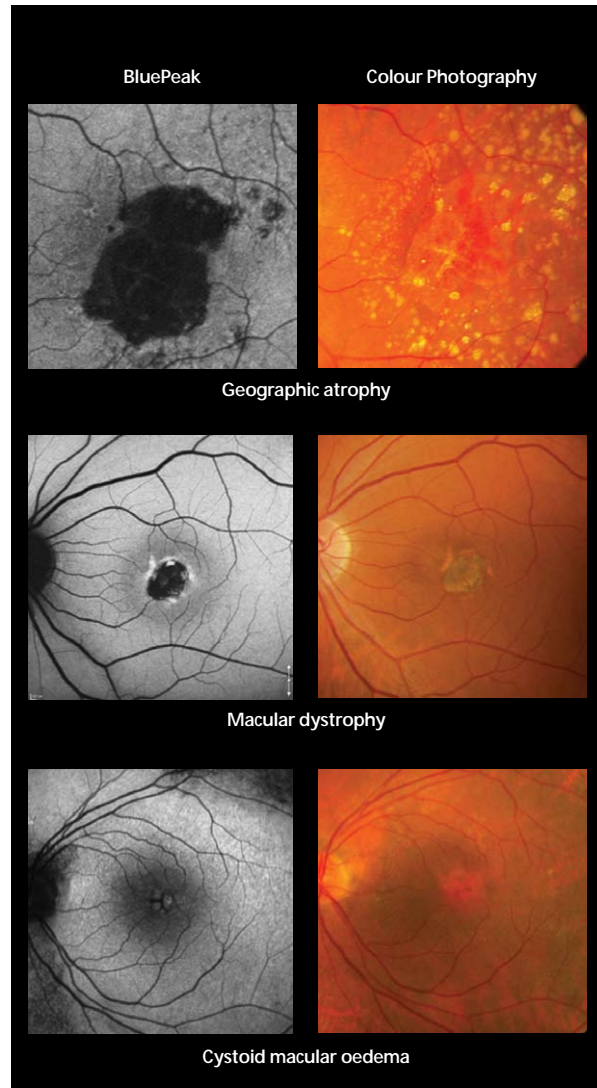
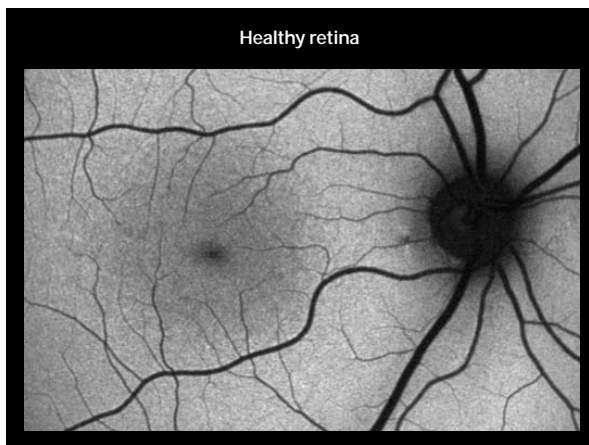
Heidelberg's Spectralis systems are designed to integrate effectively into any clinical setting *i.e.* in just a solo practice or a high volume clinic with multiple satellite offices. It can be networked via a common patient database, Heyex™ that facilitates storage and management of image files from all Heidelberg Engineering imaging devices. Network Viewing software allows easy, reliable access to patient image files on any networked computer. The OCT AutoRescan™ allows tracking of changes over time by automatically placing follow-up scans in precisely the same location. Follow-up scans can be performed at any SD-OCT enabled Spectralis device within a network. This optimizes patient flow and means small changes can be identified with confidence. TruTrack™ Active Eye Tracking enables multiple images to be captured in the exact same location. Images are super imposed, which eliminates "noise" in the fundus and OCT image yielding to high-contrast diagnostic images.

# Interpretation of FAF images

“Unlike OCT images FAF imaging produces a form of metabolic map visualising not just morphology but also metabolic changes. The two imaging modalities serve different purposes,” explains Dr Holz. “One imaging technique does not replace the other. The novel possibility with simultaneous recordings of cSLO FAF images and high-resolution OCT coupled with active eye tracking now offer the opportunity to study the corresponding microstructural changes in the outer retinal layers.”

In contrast to fluorescence angiography such as FA and ICG-angiography where the dynamic of the dye in the blood vessel network is of critical importance, there is no dynamic component to read in blue laser autofluorescence images. This makes these FAF images relatively easy to interpret.

When evaluating a blue laser autofluorescence image, any deviation from a normal recording should be recognized and a potential cause should be sought for the abnormal findings. In essence, abnormal FAF signals derive either from a change in the amount or composition of fluorophores in the RPE cell cytoplasm, for example lipofuscin, or from the presence of absorbing or autofluorescent material anterior to the RPE cell monolayer.



Causes for a reduced FAF signal	Causes for an increased FAF signal
<ul style="list-style-type: none"> <li>• Absence or reduction in RPE lipofuscin density</li> <li>• RPE loss or atrophy (e.g., geographic atrophy)</li> <li>• Absorption from extracellular material, cells, or intraretinal fluid (e.g., macular oedema)</li> <li>• Fresh intraretinal and subretinal haemorrhages</li> <li>• Fibrosis, scar tissue, or borders of laser scars</li> <li>• Retinal vessels</li> <li>• Luteal pigment (lutein and zeaxanthin)</li> </ul>	<ul style="list-style-type: none"> <li>• Excessive RPE lipofuscin accumulation</li> <li>• Lipofuscinoses including Stargardt disease, Best disease, and adult vitelliform macular dystrophy</li> <li>• Age-related macular degeneration (e.g., RPE in the junctional zone preceding enlargement of occurrence of geographic atrophy)</li> <li>• Subretinal fluid leading to separation of the outer segments of the photoreceptors from the underlying RPE, which leads to improper outer segment turnover</li> <li>• Drusen in the sub-pigment epithelial space</li> <li>• Older intraretinal and subretinal haemorrhages</li> <li>• Lack of absorbing material</li> <li>• Optic nerve head drusen</li> </ul>

The identification of abnormalities in the FAF image is very much dependent on the quality of the recorded image. Any opacity in the vitreous, the lens, the anterior chamber or the cornea may affect the detected autofluorescence at the level of the RPE and the neurosensory retina.

For the evaluation and interpretation of a FAF image for an individual patient it may be helpful to correlate the findings with those obtained with reflectance images of the same excitation

wavelength and other imaging methods, including fundus photography, OCT and fluorescein angiography.

Multi-modality imaging with BluePeak and SD-OCT opens up new perspectives to reveal pathophysiologic alterations, potentially showing different underlying defects in cross-sectional as well as longitudinal analyses. This is going to be helpful for diagnostic purposes and phenotyping but also for future therapeutic intervention to investigate treatment responses.

## TESTIMONIALS



**“These distinct autofluorescence abnormalities do not show up on funduscopy or any other imaging method.”**

**“The high-contrast difference between atrophic and non-atrophic retina allows delineating the area of atrophy more precisely and accurately as compared to conventional fund photographs.”**

**“An even more striking finding of autofluorescence imaging in GA patients is the frequent visualisation of high intensity levels surrounding the atrophic patches. The enlargement of existing or the development of new atrophy is spatially confined to retinal areas with previously increased levels of autofluorescence.”**

*Dr Steffen Schmitz-Valckenberg*

**“The analysis of the initial foveal fundus autofluorescence (FAF) in patients with CNV in exudative AMD appears to be an important prognostic factor for distinguishing patients in whom visual function may improve after therapy from those patients in whom retinal damage has already progressed, which limits a positive functional outcome.”**

*Drs Britta Heimes, Daniel Pauleikhoff and Alan Bird*



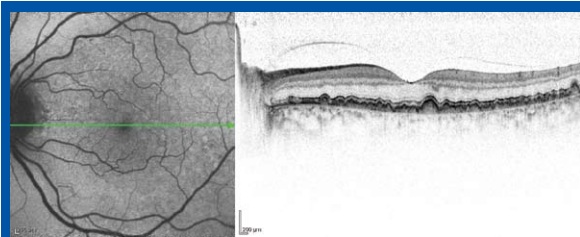
# Improving retinal health — clinical applications

## General retina health check

FAF imaging is a powerful and versatile tool that can be used to quickly and non-invasively diagnose and monitor a number of retinal diseases, most of which are still largely under-diagnosed and therefore under-treated. For example, wet AMD is the leading cause of legal blindness in people over 50 years of age in the western world, affecting around 500 000 people worldwide each year.<sup>1</sup> This figure might, however, be significantly higher, with further research indicating that between 55 and 70% of AMD sufferers are undiagnosed.<sup>2</sup> This clearly indicates an inadequacy in current screening and referral methods and, as such, a certain

level of responsibility lies with the general ophthalmologist to reduce the number of undiagnosed cases of AMD and other debilitating retinal diseases.

FAF imaging has traditionally been regarded as a tool for experienced retinal specialists only; however, this perception is beginning to change as general ophthalmologists are becoming aware of the increasing importance of their role in the ongoing monitoring of their patients' retina health. Early identification is critical in most retina diseases and regular and accurate retina health checks, particularly in high-risk patients, could help minimise future damage and even prevent blindness.

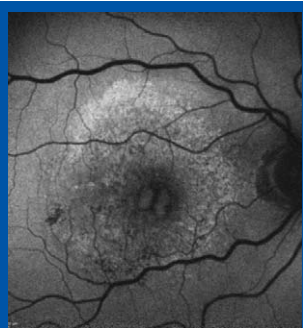


Simultaneous FAF and OCT image for a patient with drusen.

cSLO technology, for the acquisition of FAF images, offers general ophthalmologists a reliable tool for the diagnosis and ongoing monitoring of retina conditions; it can be easily integrated into a clinic and has a simple, well established, standardised protocol. No patient preparation or particular environmental conditions are necessary and the technology provides quick, detailed and reliable scans of the retina.

cSLO technology allows the general ophthalmologist to accurately identify a wide range of retina diseases, including AMD (drusen, geographic atrophy, choroidal neovascularisation), cystoid macular oedema, uveitis and macular hole, as well as a number of hereditary conditions, including retinitis pigmentosa (RP) and Stargardt's disease. The technology produces images of exceptional clarity by identifying distinct patterns for specific conditions, even in the earliest of stages of a disease, thus improving early referral and treatment rates.

With the increasing prevalence of retina diseases, largely owing to the aging population and lifestyle factors, general ophthalmologists are under increasing pressure to ensure that their screening methods are clear and accurate to avoid misdiagnoses and poor referrals. Rising prevalence rates and the availability of novel treatments will also continue to add a great deal of strain onto retina clinics, most of which are already operating above capacity. As more therapeutics are made available, the general ophthalmologist will be increasingly relied upon to be involved in the ongoing monitoring of patients and to track treatment progress. As such, the use of cSLO technology by general ophthalmologists is expected to increase as more demands are placed upon them to diagnose and refer early and to work alongside retina specialists in the ongoing treatment of their retina disease patients.



The classification of CNV is possible with FAF imaging.

### Wet AMD

Much attention has been focused in recent years on the wet or exudative form of AMD, because of the high prevalence of the disease, which is estimated, on average, to exceed 500 new cases per million population in western Europe each year.<sup>3,4</sup> Although much more is known about the pathophysiology of wet AMD than the dry form of

the disease, and therapeutic interventions exist with a growing number in the pipeline, the number of undiagnosed patients remains unacceptably high.

FAF imaging with cSLO technology has been shown to be highly effective in the diagnosis of wet AMD. In order to understand why this is so, one must first understand the nature of the disease process.

Wet AMD is characterised by choroidal neovascularisation (CNV), which develops between Bruch's membrane, RPE and the photoreceptor layer. In studies, it has been shown that all types of CNV are associated with normal, increased, or decreased focal RPE autofluorescence.<sup>5,6</sup> Thus RPE dysfunction has been shown to play a role in the pathogenesis of wet AMD. These studies have also shown an association between FAF pattern and the duration of neovascularisation and visual function, suggesting that FAF imaging may be important in identifying and monitoring CNV secondary to AMD.

In these patients, FAF shows patches of 'continuous' or 'normal' autofluorescence implying that RPE viability is preserved, at least initially, in CNV development.<sup>7</sup> This corresponds with areas of hyperfluorescence on comparative fluorescein angiograms. By contrast, eyes with long-standing CNV typically exhibit more areas of decreased signal, which could be explained by the photoreceptor loss and scar formation with increased melanin deposition that is often seen with CNV progression. Importantly, abnormal FAF intensities visible in eyes with CNV often extend beyond the edge of a lesion defined by fluorescein angiography, which indicates a more widespread disease process, over and above that witnessed on conventional angiograms. It has been speculated that this observation may reflect the proliferation of RPE cells around the CNV.<sup>8</sup>

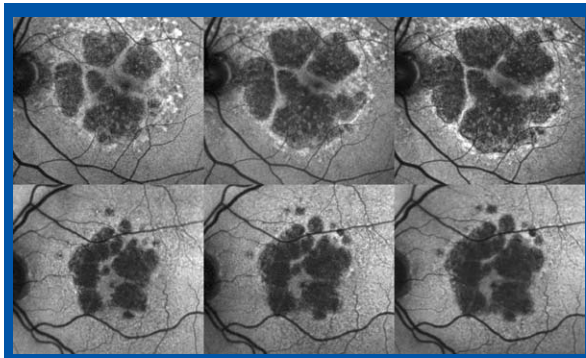
The classification of CNV, as classic or occult, is also possible with FAF imaging; a report by Spital and co-workers found that focal areas of decreased FAF are more prevalent in classical CNV in comparison to larger occult CNVs.<sup>9</sup>

Although the role of the areas with increased FAF intensities due to RPE dysfunction in wet AMD remains unclear, findings from many studies that have shown clear evidence of disease using FAF imaging, underscores its value in the diagnosis and monitoring of wet AMD.

### Geographic atrophy

FAF imaging has also been shown to be effective in the identification of the dry form of AMD. Representing the natural end-stage of AMD, when CNV does not develop, geographic atrophy (GA) is a dynamic disease process, responsible for approximately 35% of all cases of late AMD<sup>10,11</sup> and legal blindness. In spite of advances made in the understanding and treatment of wet AMD, to date, there is still no proven treatment to prevent, halt or slow GA progression.

GA is characterised by the development of areas of outer retinal atrophy that slowly enlarge over time at a median rate of 1.5 to 2.1 mm<sup>2</sup> per year.<sup>12-16</sup> During the natural course of the disease, the fovea may or may not be involved; however patients experience increasing loss of visual function.



Atrophic areas in GA can be detected by FAF as they appear as dark areas. These images represent the progression of GA, over time, in two patients. Photo courtesy of The Bonn Group.

The exact pathophysiological mechanisms underlying the atrophic process are not yet understood. Therefore, in order to identify therapeutic targets and to evaluate therapeutic interventions, a better understanding of the progression of GA is necessary.

Atrophic areas in GA lack RPE lipofuscin and, as such, these areas can be detected easily by FAF because they appear dark; the high-contrast difference between atrophic and non-atrophic retina allows the area of atrophy to be more precisely and accurately identified. Thus, GA can be diagnosed and quantified precisely by cSLO technology,<sup>17,18</sup> which allows the non-invasive monitoring of atrophy progression.

Another important observation with FAF imaging in GA patients is the abnormally high levels of FAF in the areas immediately surrounding the atrophic patches, the so-called junctional zone between the atrophic and the normal retina.<sup>19</sup> This is particularly interesting as these FAF abnormalities immediately precede cell death and, therefore, absolute scotoma. These distinct abnormalities do not show up on funduscopy or with any other imaging method, thus highlighting the importance of FAF imaging in GA. In particular, longitudinal observations further suggest that the enlargement of this area of FAF accumulation that surrounds atrophy has a strong positive correlation with atrophy progression rate over time.<sup>15</sup> Hence, not only is FAF imaging important in the identification of GA, it is also useful in tracking the progress of the disease.

Based on this knowledge, the nature of GA has been extensively studied using FAF. In order to build upon the understanding of the disease, with a view to developing effective interventions and to assist in the classification of the stages of the disease, large patient cohorts have enabled researchers to establish distinct patterns of abnormal elevated FAF in the junctional zone of GA.<sup>20</sup>

More recently, a team of researchers in collaboration with the Fundus Autofluorescence in Age-related Macular Degeneration (FAM) study group has developed the classification of FAF patterns observed in the junctional zone of patients with GA, secondary to AMD.<sup>15</sup> The report indicates that eyes with the banded (median 1.81 mm<sup>2</sup>/year) and the diffuse FAF pattern (1.77 mm<sup>2</sup>/year) showed a more rapid enlargement of atrophy

compared with eyes without FAF abnormalities (0.38 mm<sup>2</sup>/year) and the focal FAF pattern (0.81 mm<sup>2</sup>/year). Within eyes demonstrating a diffuse FAF pattern, the researchers identified eyes with extremely rapid atrophy progression showing distinct FAF features around atrophy that had not been previously observed. The team thus introduced the term “diffuse trickling” for this pattern, which is associated with a significantly faster atrophy enlargement compared with all other diffuse eyes.

Importantly, these identified patterns of FAF abnormalities were shown to have a much stronger impact on atrophy progression than any other risk factor that has been addressed in previous studies on progression of GA due to AMD. Although the large database of the FAM study shows that localised FAF is not automatically associated with localised occurrence of new atrophy or enlargement of existing atrophy, the different FAF patterns around atrophy do have an overall impact on atrophy progression. Consequently, the FAF pattern classification is useful in daily practice for the estimation of GA progression in patients.

Interestingly, recent research by Holz and colleagues<sup>21</sup> showed that the progression of GA in bilateral atrophic AMD is, in fact, a highly symmetrical process, even though the size of the GA might differ substantially between eyes. The researchers also noted a high degree of intra-individual symmetry with respect to GA progression rate. This fascinating finding points to genetic and/or environmental factors, rather than non-specific ageing processes, as potential determinants for the rate of GA progression.

The presence of abnormal FAF intensities around atrophy and the pathophysiological role of increased RPE lipofuscin accumulation in patients with GA attributable to AMD has, therefore, been adequately demonstrated. Thus the value of FAF imaging in these patients is accepted.

## Hereditary retina diseases

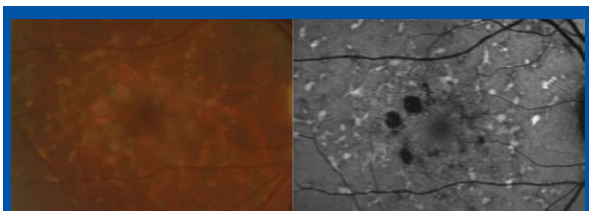
Although AMD is the most widely researched, understood and publicised of the retina diseases, the effective diagnosis and management of rare retina disease must also be understood, particularly because the prevalence of these rarer conditions continues to increase. Hereditary retina diseases affect a small portion of retina disease patients; however, the conditions, which include retinitis pigmentosa (RP), cone and cone-rod dystrophies, Best’s disease, Stargardt’s disease and vitelliform macular dystrophy, are visually debilitating.

As with AMD, these conditions manifest themselves with changes in metabolic activity of the RPE-photoreceptor complex and, as such, can be effectively detected using FAF imaging.

In patients with RP, for example, rings and lines of increased FAF have been identified.<sup>22</sup> Interestingly, further testing using microperimetry and electrophysiology, have revealed that these rings mark an area of preserved photoreceptor function, which constrict progressively over time.<sup>22-24</sup>

Ring-like forms of increased autofluorescence, which may enlarge with time, are also evident in patients with cone or cone-rod dystrophy.<sup>25</sup> In these hereditary diseases, the increased autofluorescence is associated with reduced rod and cone





FAF imaging (right) is able to highlight Stargardt's disease clearly, compared to colour photography (left). Photo courtesy of the Bonn Group.

sensitivity, rather than photoreceptor cell death.

Meanwhile, in Stargardt's disease, the most common form of inherited juvenile macular degeneration, areas of atrophy and abnormal fluorescence obtained using FAF have been clearly demonstrated.<sup>26</sup>

In general, FAF imaging is able to highlight abnormalities in these hereditary and other complex retina diseases, even in patients where there are no manifest visual or functional abnormalities. Hence, FAF imaging is not only useful in diagnosis and monitoring, but it may also help identify viable areas of retina amenable to future therapeutic intervention.

### Prognostic value for treatment outcome

Whilst it is hoped that FAF imaging will assist in the discovery of new targets for therapeutic agents, it is also believed to play a role in assessing the effectiveness of drug therapy in retina disease.

Of all known retina diseases, approved therapeutic agents are only currently available for the treatment of wet AMD. As such, FAF imaging has been investigated to assess the prognostic value of autofluorescence in relation to the therapeutic outcome of anti-VEGF (vascular endothelial growth factor) therapy in wet AMD.

As discussed earlier, FAF imaging is a valuable tool in the diagnosis and monitoring of wet AMD; RPE dysfunction plays a role in the pathogenesis of wet AMD and the changes in FAF intensity visible in wet AMD (due to RPE dysfunction) can diagnose the sub-type, stage and severity of disease. It therefore stands to reason that FAF could be a useful tool in predicting wet AMD patients' response to treatment.

Heimes and co-workers have in fact recently demonstrated a possible predictive value of FAF imaging in the determination of anti-VEGF therapy success.<sup>27</sup>

In their study, in which FAF images were obtained from 95 eyes with exudative macular lesions and associated drusen before anti-VEGF therapy with bevacizumab (Avastin), the team demonstrated that changes in FAF were significantly associated with decreased visual acuity initially. Interestingly, eyes that showed changed FAF activity before anti-VEGF treatment were less likely to respond well to therapy, *i.e.* the possibility of increasing visual acuity post-therapy was significantly reduced. The authors hypothesised that this may be related to the reduced initial photoreceptor function associated with stressed RPE, often apparent in wet AMD. This reduced photoreceptor function would of course explain the lower visual acuity, but it also explains the lower chance of visual recovery, even after treatment. Specifically, the study group demonstrated that the

development of visual acuity is less favourable in eyes with initially increased central FAF.

Overall, it was concluded that analysis of the initial FAF in patients with CNV in wet AMD was found to be an important prognostic factor for distinguishing patients in whom visual function may improve after therapy from those patients in whom retinal damage has already progressed and thus will be less likely to respond positively to anti-VEGF therapy. Of note, Professor Pauleikhoff, in a presentation given at the recent meeting of the American Society of Retina Specialists in New York, US,<sup>28</sup> referred to this group as "cannot-responders" to anti-VEGF therapy.

FAF provides a comprehensive "health check" of the RPE / photoreceptor complex for all retina conditions, and will have prognostic importance for the patient in predicting rate of disease progression, time to visual loss and therapy success.<sup>29</sup> Based on the available treatment options, this prognostic power of FAF in predicting the outcome and success therapy is particularly important in the management of wet AMD. Once the RPE is gone or the metabolism of the RPE / photoreceptor complex is severely affected the patient can no longer respond to anti-VEGF therapy.

### References

1. AMD Alliance International. Impact of AMD. [www.amdalliance.org](http://www.amdalliance.org), accessed 29 September 2009.
2. Practice management in the era of anti-VEGF therapy. A supplement to *Ophthalmology Times Europe*; 2006(2)4:S1-8.
3. W.F. Schrader. *Ophthalmology* 2006;103(9):74208.
4. AMD Alliance UK. Left to pay their own way. October 2006.
5. S.S. Dandekar, *et al. Arch. Ophthalmol.* 2005;123(11):1507-1511.
6. C. Framme, *et al. Ophthalmic Surg. Lasers Imaging* 2006;37(5):406-414.
7. V. Vacklavik, *et al. Ophthalmology* 2008;115(2):342-346.
8. V.A. McBain, *et al. Br. J. Ophthalmol.* 2007;91:491-496.
9. G. Spital, *et al. Klin. Monatsbl. Augenheilkd* 1998;213:23-31.
10. R. Klein, *et al. Ophthalmology* 2007;114:253-262.
11. C.A. Augood, *et al. Arch. Ophthalmol.* 2006;124:529-535.
12. J.S. Sunness. *Mol. Vis.* 1999;5:25.
13. P. Maguire & A.K. Vine. *Am. J. Ophthalmol.* 1986;102:621-625.
14. H. Schatz & H.R. McDonald. *Ophthalmology* 1989;96:1541-1551.
15. F.G. Holz, *et al. Am. J. Ophthalmol.* 2007;143:463-472.
16. J. Sunness, *et al. Ophthalmology* 2007;114:271-277.
17. A. Deckert, *et al. BMC Ophthalmol.* 2005;5:8.
18. S. Schmitz-Valckenberg, *et al. Graefes Arch. Clin. Exp. Ophthalmol.* 2002;240:73-78.
19. F.G. Holz, *et al. Arch. Clin. Exp. Ophthalmol.* 1999;237:145-152.
20. A. Bindewald, *et al. Br. J. Ophthalmol.* 2005;89:874-878.
21. F.G. Holz, *et al. Invest. Ophthalmol. Vis. Sci.* In press.
22. A.G. Robson, *et al. Doc. Ophthalmol.* 2008;116:79-89.
23. P. Popovic, *et al. Graefes Arch. Clin. Exp. Ophthalmol.* 2005;243:1018-1027.
24. M. Fleckenstein, *et al. Eye* 2009;23:567-575.
25. A.G. Robson, *et al. Br J Ophthalmol.* 2008;92:95-102.
26. N.L. Gomes, *et al. Invest. Ophthalmol. Vis. Sci.* 2009;50:3953-3959.
27. B. Heimes, *et al. Graefes Arch. Clin. Exp. Ophthalmol.* 2008;246(9):1229-1234.
28. D. Pauleikhoff. Predictive factors for the long-term efficacy of anti-VEGF therapy in exudative AMD. Presentation given at the annual meeting of the American Society of Retina Specialists, 30 Sept. – 4 Oct. 2009; New York, US.
29. S. Schmitz-Valckenberg, *et al. Am. J. Ophthalmol.* 2008;146:183-192.

# Getting the full picture

## The combination of FAF with SD-OCT

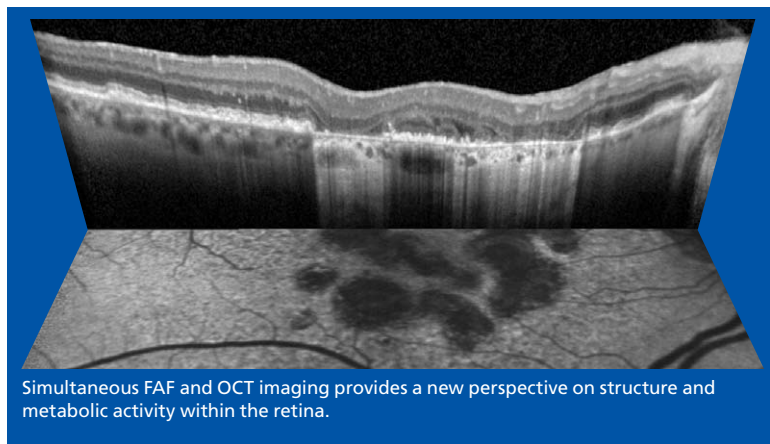
The Spectralis® models are a fusion of confocal scanning laser fundus imaging and Spectral Domain OCT (SD-OCT). Actively guiding the OCT scan in real-time creates a new type of imaging modality, which Heidelberg calls, Tracking Laser Tomography. Any of the five fundus imaging modalities (see **Table 2**) available on the system can be used to direct the SD-OCT to an area of interest or across the entire posterior pole.

"The simultaneous recording of cSLO and SD-OCT images in one instrument with an exact topographic overlay during image acquisition now allows for accurate orientation of cross-sectional SD-OCT scans at anatomic sites of interest and, furthermore, serial examinations at the same location over time," confirmed Dr Frank Holz.

"Combining blue laser autofluorescence technology with OCT imaging has the potential to further improve our understanding of the pathogenesis of several macular pathologies and may prove to be useful for diagnosis and management," he explained.

### Active eye tracking

Two separate beams of light are used to capture two images simultaneously. "Volume scanning is the real power of SD-OCT. Since very few patients can keep their eyes still during a volume scan, active eye tracking is essential to get accurate SD-OCT scans," says Dr Alexander Walsh of Doheny Eye Institute, University of Southern California, Los Angeles, CA, USA. A beam constantly tracks and images the fundus and also acts as a reference, guiding the OCT beam. The active eye tracking locks the OCT to the fundus. The precise alignment of blood vessels from the fundus image to the corresponding OCT scan provides the proof.<sup>1-6</sup> This tracking is critically important in 3D volume scans which are susceptible to eye motion artifact.



### Tracking changes over time

Knowing where the scan is taken the first time is important; knowing where it's taken at a follow-up scan is critical. Using the fundus image like a fingerprint, AutoRescan™ automatically places follow-up scans in precisely the same location.

### In vivo optical histology

The automatic real time combination of images allows for effective discrimination between image "noise" and true signals from real tissue structures. With Heidelberg's Noise Reduction™ technology noise is effectively been eliminated and the results are images of high contrast and detail.

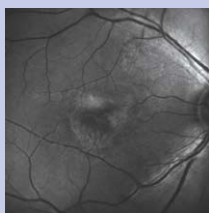
"With Spectral-Domain OCT imaging, the specific histopathologic bands between the different retinal layers are visible in most patients. It's like getting a non-invasive retinal biopsy," explains Dr David Brown of Vitreoretinal Consultants, Houston, TX, USA. "The images show increased resolution across all retinal layers, especially at the RPE where subtle differences are especially meaningful," adds Dr Jeff Heier of Ophthalmic Consultants of Boston, Boston, MA, USA.

### References

1. M. Fleckenstein *et al.*, *Arch Ophthalmol.* 2008;126:1461-1463.
2. M. Fleckenstein *et al.*, *Invest Ophthalmol Vis Sci.* 2008;49:4137-4144.
3. A. Hassenstein & C.H. Meyer. *Clin Experiment Ophthalmol* 2009;37:130-143.
4. H.M. Helb *et al.*, *Acta Ophthalmologica* (2009), (in press).
5. S. Schmitz-valckenberg *et al.*, *Invest Ophthalmol Vis Sci.* 2009;50:3915-3921.
6. P. Charbel Issa *et al.*, *Invest Ophthalmol Vis Sci.* 2009 doi:10.1167/iov.09-3541

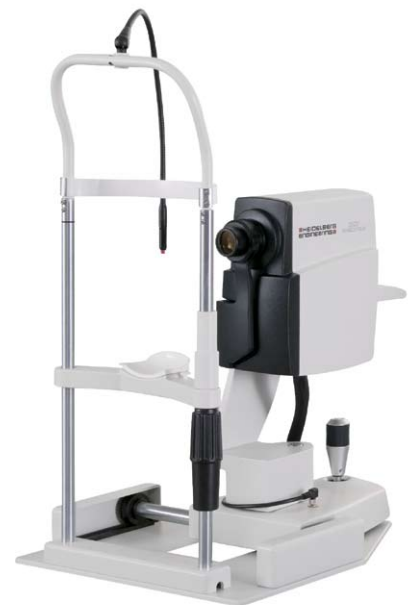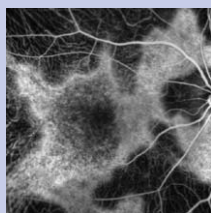


Table 1: Spectralis product family- the multi-modality imaging platform.



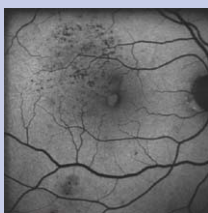
#### Red Free Imaging

Blue light is used to create a 'red-free' image highlighting specific structures such as the nerve fibre layer, epiretinal membranes, retinal folds and cysts.



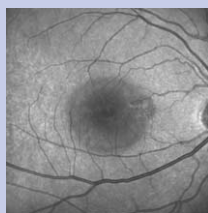
#### ICG Angiography

Confocal laser ICG angiography reveals the details of the choroidal circulation and may help the ophthalmologist better understand cases unresponsive to anti-VEGF therapy. Dynamic imaging can distinctly reveal RAP (RCA) lesions that may not be visible with FA.



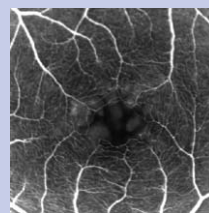
#### Blue Laser Autofluorescence

Without the need for any dye, blue laser autofluorescence takes advantage of the fluorescent properties of lipofuscin. The characteristic patterns of autofluorescence can reveal, non-invasively, the extent of geographic atrophy or hereditary diseases such as Best's or Stargardt's.



#### Infrared Imaging

Using only long wavelengths of laser light, infrared imaging captures fundus images in fine detail even without dilation. The deeper penetration of light, combined with the confocal principle, provides more distinct detail of intra-retinal lesions such as CME or CSCR. The lower level of light is better tolerated by elderly patients who may experience discomfort with flash photography.



#### Fluorescein Angiography

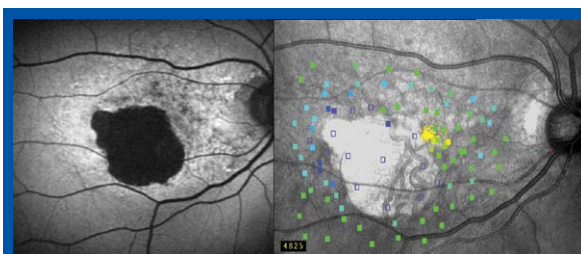
Confocal laser angiography adds new dimensions to traditional fundus photography, providing dynamic imaging as the dye flows through the vasculature. The confocal principle enables much finer detail by blocking scattered light.

# Correlation of FAF imaging with photoreceptor function

Blue laser autofluorescence images lend themselves to further study by allied systems. Whilst these innovations mean that the general ophthalmologist is able to detect early retinal changes the challenge to correlate subjective alterations or clinical changes with visual function still remain. Microperimetry offers the option to test retinal sensitivity while directly observing the fundus.<sup>1</sup>

Combined microperimetry and imaging studies have demonstrated an exact correlation between fundus changes and functional impairment.<sup>2-5</sup> For example, Steffen Schmitz-Valckenberg *et al.*,<sup>6</sup> investigated abnormal FAF and retinal sensitivity in the junctional zone of GA in patients with AMD. Their findings demonstrated that elevated FAF outside of GA areas is associated with functional impairment of the neurosensory retina. This may reflect the relevance of lipofuscin accumulation in RPE cells in the context of developing advanced atrophic AMD.

Successful diagnosis and treatment decisions cannot be based on novel technologies, like FAF imaging, alone but correlation with allied systems, knowledge and experience all combined can only serve to assist and help push the boundaries



Correlation of a FAF image (left) with photoreceptor function (right) in a GA patient. Photo courtesy of The Bonn Group.

of ophthalmic medicine thereby promoting improvements to medical practice and ultimately patient health.

#### References

1. K. Rohrschneider *et al.*, *Prog Retin Eye Res.* 2008;27:5:536-48.
2. K. Rohrschneider *et al.*, *Graefes Arch Clin Exp Ophthalmol* 1995;233:743-749.
3. K. Rohrschneider *et al.*, *Am J Ophthalmol* 2000;129:27-32.
4. K. Rohrschneider *et al.*, *Br J Ophthalmol* 1997;81:568-573.
5. J.S. Sunness *et al.*, *Invest Ophthalmol Vi Sci* 1995;36:1863-1874.
6. S. Schmitz-Valckenberg *et al.*, *Invest Ophthalmol Vi Sci* 2004;45:4470-4476.

