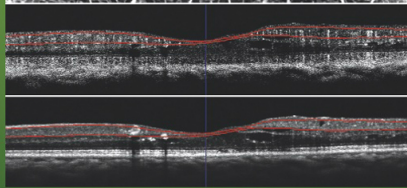
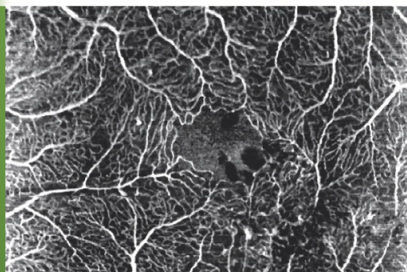


OCT-ANGIOGRAPHY  
*in Diabetic Maculopathy*

ATLAS  
OCT-ANGIO  
IN DIABETIC MACULOPATHY



*Gabriel Coscas*

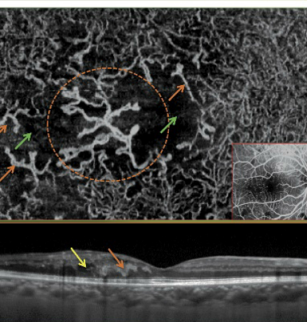
*Marco Lupidi*

*Florence Coscas*

.....  
(Paris, Créteil, Pérouse)

# ATLAS OF OCT-ANGIOGRAPHY

*in Diabetic Maculopathy*



**Gabriel Coscas**

*Marco Lupidi*

*Florence Coscas*

(Paris, Créteil, Pérouse)

**Optical Coherence Tomography Angiography (OCT-A)** is a new method of non-invasive examination, which allows visualizing the entire retinal and choroidal vasculature thanks to a novel technique of conventional OCT imaging analysis.

**This diagnostic approach** is rapidly spreading among the largest part of the ophthalmologists. It consists of a new step forward on OCT technology, which will allow each clinician to easily have a snapshot of the vessels and the retinal capillaries and / or choroidal vasculature.

**This imaging modality** is coupled with the traditional OCT images, which can highlight lesions of outer retinal layers and fluid accumulations. In this way both functional and morphological information are obtained with a single examination. OCT-A is a new «instant imaging»: since it is easy, quick and non-invasive, it seems very promising for all retinal and choroidal vascular diseases.

**Diabetic retinopathy (DR)** is the leading cause of visual impairment in working-age adults worldwide. Early detection of DR is crucial for prevention of vision loss. Among the retinal changes, such as microaneurysms, intraretinal hemorrhages, hard exudates, macular ischemia is a striking feature leading to decreased perifoveal capillary blood flow and, in turn, causing chronic ischemia of the retinal tissue. Macular ischemia is now considered an important predictor of poor functional outcome in patients with diabetes mellitus (DM).

**The OCT-Angiography (OCT-A)** allows a clear, depth-resolved visualization of the retinal and choroidal microvasculature. OCT-A is based on the concept that in a static eye, the only moving structures in the eye-fundus are blood cells, flowing in the vessels. OCT-A does not require administration of intravenous dye as fluorescein or indocyanine green, avoiding, in this way, potential risks which can result in rare adverse events.

**In this Atlas**, we aimed to show the contribution of OCT-A in detecting, grading the severity and orienting the treatment decision in case of Diabetic Maculopathy

ISBN 978-2-91-628774-4



9 782916 287744

**ATLAS**

**OCT-ANGIOGRAPHY**

**in Diabetic Maculopathy**

**COMPARISON WITH MULTIMODAL IMAGING**

*Published with the generous help of  
"FONDATION PAULETTE DARTY" - Fondation de France.*

*With the support of HEIDELBERG ENGINEERING,  
And confidential agreement for the use of their OCT-Angraphy software Prototype.*



---

**ATLAS**  
**of**  
**OCT-ANGIOGRAPHY**  
**in**  
**Diabetic Maculopathy**

**COMPARISON WITH MULTIMODAL IMAGING**

**Gabriel COSCAS**

**Marco LUPIDI, Florence COSCAS**

**(Paris, Créteil, Perugia)**

---

# **Authors**

## **Gabriel COSCAS**

Professeur Emérite des Universités  
Hôpital de Créteil. Département d'Ophtalmologie de Créteil  
Université Paris XII, Val de Marne - France  
Centre d'Exploration Ophtalmologique de l'Odéon, Paris  
*Email: gabriel.coscas@gmail.com*

## **Marco LUPIDI**

Medical Retina Research Fellow  
Centre d'Exploration Ophtalmologique de l'Odéon, Paris  
Department of Biomedical and Surgical Sciences, Section of Ophthalmology  
"S.Maria della Misericordia" Hospital  
University of Perugia, Perugia, Italy  
*Email: dr.marco.lupidi@gmail.com*

## **Florence COSCAS**

Praticien Hospitalier  
Hôpital de Créteil. Département d'Ophtalmologie de Créteil  
Université Paris XII, Val de Marne - France  
Centre d'Exploration Ophtalmologique de l'Odéon, Paris  
*Email: coscas.f@gmail.com*

---

## Table of contents

<b>CHAPTER I :</b> INTRODUCTION .....	7
<b>CHAPTER II :</b> CONVENTIONAL IMAGING IN DIABETIC MACULOPATHY .....	13
<b>CHAPTER III :</b> OCT-ANGIOGRAPHY : TECHNICAL ASPECTS .....	21
<b>CHAPTER IV :</b> OCT-ANGIOGRAPHY : HOW TO ACQUIRE IMAGES .....	29
<b>CHAPTER V :</b> OCT-A-SCREEN VIZUALIZATION .....	35
<b>CHAPTER VI :</b> OCT-ANGIOGRAPHY : HOW TO OBTAIN IMAGES .....	43
<b>CHAPTER VII :</b> OCT-ANGIOGRAPHY IN HEALTHY SUBJECTS .....	53
<b>CHAPTER VIII :</b> OCT-ANGIOGRAPHY IN DIABETIC PATIENTS : THE SUPERFICIAL AND DEEP CAPILLARY PLEXUSES .....	67
<b>CHAPTER IX :</b> OCT-ANGIOGRAPHY IN DIABETIC PATIENTS : THE CHORIOCAPILLARIS AND CHOROID.....	85
<b>CHAPTER X :</b> OCT-ANGIOGRAPHY IN DIABETIC PATIENTS : MACULAR EDEMA.....	97
<b>CHAPTER XI :</b> OCT-ANGIOGRAPHY IN DIABETIC PATIENTS : MACULAR ISCHEMIA.....	115
<b>CHAPTER XII :</b> OCT-ANGIOGRAPHY IN DIABETIC PATIENTS : QUANTITATIVE IMAGE ANALYSIS AND FOLLOW-UP .....	131





## **CHAPTER I**

# **Introduction**



## Introduction

---

Optical Coherence Tomography Angiography (OCT-A) is a **new method** of non-invasive examination, which allows visualizing the entire retinal and choroidal vasculature thanks to a novel technique of conventional OCT imaging analysis.

This diagnostic approach is rapidly spreading among the largest part of the ophthalmologists. It consists of a new step forward on OCT technology, which will allow each clinician to easily have a snapshot of the vessels and the retinal capillaries and / or choroidal vasculature.

**This imaging modality** is coupled with the traditional OCT images, which can highlight lesions of outer retinal layers and fluid accumulations. In this way both functional and morphological information are obtained with a single examination.

OCT-A is a new «instant imaging» : since it is easy, quick and non-invasive, it seems very promising for all retinal and choroidal vascular diseases.

**Diabetic retinopathy (DR)** is the leading cause of visual impairment in working-age adults worldwide.<sup>1-3</sup>

The disease is characterized by microaneurysms, capillary non-perfusion, and ischemia within the retina, ultimately leading to neovascularization and/or macular edema, both of which can severely compromise visual function. **Early detection of DR** is crucial for prevention of vision loss.

Among the **retinal changes**, such as microaneurysms, intraretinal hemorrhages, hard exudates, **macular ischemia** is a striking feature leading to decreased perifoveal capillary blood flow and, in turn, causing chronic ischemia of the retinal tissue.<sup>4</sup>

Several studies from the 1970s defined the functional importance of macular ischemia,<sup>4-6</sup> which is now considered an important predictor of poor functional outcome in patients with diabetes mellitus (DM).

Retinal imaging is widely used by ophthalmologists and primary care physicians to screen and follow-up for epidemic eye diseases such as DR and DME.

Color fundus photography (CF) was initially the leading examination in DR.

## IMAGING THE FUNDUS

### FLUORESCEIN ANGIOGRAPHY

**Fluorescein Angiography (FA)** is from 50 years, the imaging method of choice («*Gold standard*») for the analysis of the vascular and capillary bed.

While FA provides a high sensitivity for a wide range of diabetic retinal changes two-dimensionally, OCT raster scanning offers important cross-sectional information about the retinal layers.<sup>7,8</sup>

### OPTICAL COHERENCE TOMOGRAPHY

Optical coherence tomography (OCT), and in particular the Spectral Domain OCT (SD-OCT), has recently entered the field of retinal imaging in clinical daily routine.

**From 20 years, the OCT** is tremendously developed as a noninvasive imaging method and medical diagnostics, a real «Optical Biopsy» of retinal microstructures.

SD-OCT is able to identify several aspects of DR and its exudative consequences such as fluid accumulation or retinal thickening (or thinning).

SD-OCF will thus provide a test of therapeutic efficacy, easy to follow-up and interpret, which has a proven reliability.<sup>9</sup>

**In this Atlas, we aimed to show the contribution of OCT-A in detecting, grading the severity and orienting the treatment decision in case of Diabetic Maculopathy**

### OCT-ANGIOGRAPHY

**The OCT-Angiography (OCT-A)** is a new revolutionary technique, that allows a clear, depth-resolved visualization of the retinal<sup>10</sup> and choroidal microvasculature.<sup>11</sup> The method was brilliantly presented in its clinical approach by David Huang, James Fujimoto and their colleagues in several<sup>11</sup> publications and on the occasion of the Imaging Conference that preceded the ARVO meeting in Orlando in 2014.

OCT-A is based on the **concept** that in a static eye, the only moving structures in the eye-fundus are blood cells, flowing in the vessels. By calculating the *decorrelation of signal amplitude* from repeated consecutive B-scans at the same section, a contrast between static and non-static tissue is generated.

This will determine a vascular decorrelation **signal** that enables visualization of three-dimensional retinal and choroidal vasculature, of a variable intensity signal according to the speed of blood flow.<sup>11</sup>

OCT-A does not require administration of intravenous dye as fluorescein or indocyanine-green, avoiding, in this way, potential risks which can result in rare adverse events.

## REFERENCES

1. **Chen L, Magliano DJ, Zimmet PZ.** The worldwide epidemiology of type 2 diabetes mellitus—present and future perspectives. *Nat Rev Endocrinol.* 2012;8:228–236.
2. **Kempner JH, O'Colmain BJ, Leske MC, et al.** The prevalence of diabetic retinopathy among adults in the United States. *Arch Ophthalmol.* 2004; 122:552–563.
3. **Yau JWY, Rogers SL, Kawasaki R, et al.** Global prevalence and major risk factors of diabetic retinopathy. *Diabetes Care.* 2012; 35: 556–564.
4. **Arend O, Wolf S, Jung F, et al.** Retinal microcirculation in patients with diabetes mellitus: dynamic and morphological analysis of perifoveal capillary network. *Br J Ophthalmol.* 1991; 75 (9): 514-518.
5. **Sakata K, Funatsu H, Harino S, Noma H, Hori S.** Relationship between macular microcirculation and progression of diabetic macular edema. *Ophthalmology.* 2006;113(8):1385-1391.
6. **Kohner EM, Henkind P.** Correlation of fluorescein angiogram and retinal digest in diabetic retinopathy. *Am J Ophthalmol.* 1970; 69(3):403-414.
7. **Geitznauer W, Hitznerberger CK, Schmidt Erfurth UM.** Retinal optical coherence tomography: past, present and future perspectives. *Br J Ophthalmol.* 2011;95:171–177.
8. **Chalam KV, Bressler SB, Edwards AR, et al.** Retinal thickness in people with diabetes and minimal or no diabetic retinopathy: Heidelberg Spectralis optical coherence tomography. *Invest Ophthalmol Vis Sci.* 2012; 53:8154–8161.
9. **Yeung L, Lima VC, Garcia P, et al.** Correlation between spectral domain optical coherence tomography findings and fluorescein angiography patterns in diabetic macular edema. *Ophthalmology.* 2009; 116(6):1158-1167.
10. **Spaide RF, Klancnik JM Jr, Cooney MJ.** Retinal vascular layers imaged by fluorescein angiography and optical coherence tomography angiography. *JAMA Ophthalmol.* 2015 Jan 1; 133(1): 45-50.
11. **Jia Y, Bailey ST, Wilson DJ, et al.** Quantitative optical coherence tomography angiography of choroidal neovascularization in age-related macular degeneration. *Ophthalmology* 2014; 121(7): 1435-44.
12. **Yannuzzi LA, Rohrer KT, Tindell LJ, et al.** Fluorescein angiography complication survey. *Ophthalmology.* 1986 May; 93(5): 611-7.



**CHAPTER II**

**CONVENTIONAL IMAGING**

**IN**

**DIABETIC MACULOPATHY**





## DIABETIC MACULOPATHY

**Currently, Ophthalmologists** are facing a worldwide epidemic of diabetes mellitus (DM). In the year 2000, more than 176 million people throughout the world suffered from DM.

The World Health Organization has estimated that by the year 2030, there will be **370 million people** affected with DM in the world, and every one of them will be at risk of developing retinopathy.

**The degree and duration** of hyperglycemia, as well as hypertension and hyper-lipidemia are **risk factors** that increase the severity and development of diabetic retinopathy (DR).

**The first report of DR**, specifically *diabetic macular edema (DME)*, appeared in 1856. Prior to the advent of **Pan Retinal Photocoagulation**, (PRP), proliferative diabetic retinopathy (PDR) was the main culprit of diabetic blindness.

**Diabetic Macular Edema (DME)** has become the most common cause of visual loss in diabetic patients in the developed world, since the development of laser photocoagulation. It is estimated that in the United States alone there are 500,000 patients with DME, with *95,000 new cases every year*.

### Pathogenesis

**Hyperglycemia**, by a poorly understood mechanism, causes leukostasis, which leads to

endothelial dysfunction and progressive retinal ischemia.

In fact, DR is the prototype for the **ischemic retinopathies** where ongoing retinal ischemia causes up-regulation of vascular endothelial growth factor (VEGF).

**Diabetic macular edema** is characterized by the accumulation of intraretinal fluid, which is modulated by the balance between oncotic and hydrostatic pressures as described by Starling's law.

**Vascular endothelial growth factor**, also known as vascular permeability factor (VPF), plays a central role in the pathogenesis of DME.

Disruption of the **blood-retinal barrier**, which results in an increase of vascular permeability, is caused by VEGF. As the intraocular levels of VEGF increase, its angiogenic properties promote retinal neovascularization and its sequelae.

### Classification

Although the modified *Airlie House Classification* used in the Early Treatment of Diabetic Retinopathy Study (**ETDRS**) is considered to be the gold standard classification scheme for DR, most Ophthalmologists and even retinal specialists shunt its use in their daily clinical work.

It is an excellent tool in the research setting but its clinical applicability is limited due to its complexity.

At the 2002 Joint Meeting of the American Academy of Ophthalmology and the Pan-American Association of Ophthalmology, a new classification was unveiled.

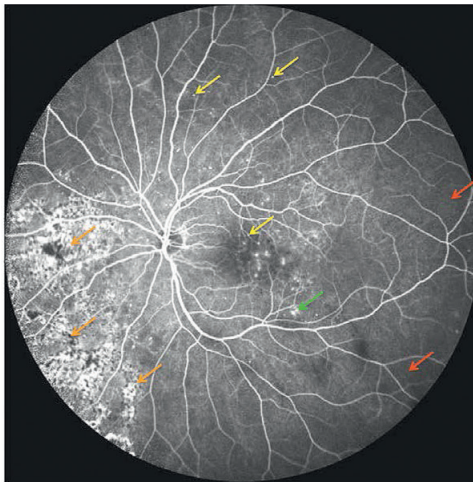
The **International Clinical Diabetic Retinopathy Disease Severity Scale**, which is based on the findings of the Wisconsin Epidemiologic Study of Diabetic Retinopathy and the ETDRS.

**It consists of five levels:**

1. No DR.
2. Mild non proliferative diabetic retinopathy (NPDR).
3. Moderate NPDR.
4. Severe NPDR. and
5. PDR.

In addition, the presence or absence of **macular edema** should be noted. If edema is present, then one should note if:

- the edema involves the center (severe DME),
- threatens the center (moderate DME), or is
- far from the center (mild DME).



**Figure 1: Diabetic Retinopathy**

Fluorescein angiogram during venous phase of a patient affected by diabetic retinopathy. This examination clearly shows microaneurysms (*yellow arrows*), intraretinal microvascular abnormalities (IRMA, *green arrow*), and areas of capillary non-perfusion (*red arrows*). Moreover some signs of laser burns are also appreciable (*orange arrows*).

- *Mild non proliferative diabetic retinopathy (NPDR)*, consists solely of micro aneurysms.

- In *moderate NPDR*, the findings fall in between mild and severe NPDR.

- The diagnosis of *severe NPDR* is based on the "4:2:1" rule of the ETDRS.

One can easily diagnose severe NPDR by mentally dividing the fundus into four quadrants centered on the optic nerve and examining the four mid peripheral quadrants with slit-lamp biomicroscopy.

If hemorrhages of at least the magnitude of standard photograph are present in all four quadrants, then by definition severe NPDR is present.

If two quadrants or more have venous beading of the same magnitude or greater than standard photograph, then by definition severe NPDR is present.

If one or more quadrant has intraretinal microvascular abnormalities (IRMAs) of the same magnitude or greater than standard photograph, then by definition severe NPDR is present.

### CLINICAL FINDINGS

Diabetic retinopathy represents a **spectrum of disease** that can be broadly divided into a non proliferative stage and a proliferative stage.

**The first clinical sign of NPDR** is the appearance of micro aneurysms. With increasing severity, intra-retinal hemorrhages start to appear.

These hemorrhages may be flame shaped or round dot blots. If the retinal ischemia persists, cotton-wool spots, venous beading, tortuosity of the retinal veins, and IRMAs will develop.

**As the degree of ischemia increases, PDR** develops. It is characterized by all the prior, in addition to neovascular and fibro-vascular proliferation.

It may appear at the disc (neovascularization of the disc [NVD]) or **at the junction** of perfused and non perfused retina (neovascularization elsewhere [NVE]).

Partial posterior **vitreous detachment** caused tangential and antero-posterior traction that leads to vitreous hemorrhage, rhegmatogenous, and tractional retinal detachment.

**Diabetic macular edema** may be present at any stage of DR and may be *focal or diffuse*. In the *focal type*, usually there are micro aneurysms surrounded by a ring of hard exudates. In the *diffuse type*, usually there are neither hard exudates nor micro aneurysms. In a small number of eyes, one may observe a glistening, taut, and thickened posterior hyaloid that exerts vitreo-macular traction.

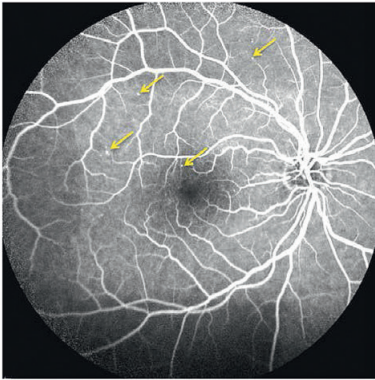
## FLUORESCIN ANGIOGRAPHY

**Micro aneurysms** appear as pinpoint hyperfluorescent lesions that fade in the later phases of the angiogram.

The hypofluorescence dot and blot **hemorrhages** distinguishes them from the hyperfluorescent micro aneurysms.

Areas of **capillary nonperfusion** are seen as homogeneous dark patches.

**Neovascularization** usually occurs at the border of perfuse and non perfused retina. Prior to the appearance of typical neovascularization, IRMA develops.

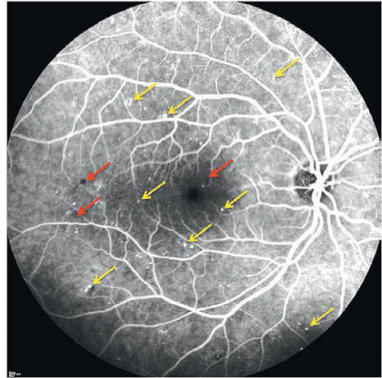


**Figure 2: Mild Non-proliferative Diabetic Retinopathy**

Fluorescein angiogram of a mild non-proliferative diabetic retinopathy.

This examination only shows micro aneurysms (*yellow arrows*).

No other clinical or angiographic findings are appreciable at this stage.

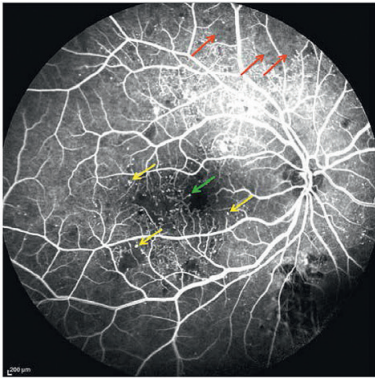


**Figure 3: Moderate Non-proliferative Diabetic Retinopathy**

Fluorescein angiogram of a moderate non-proliferative diabetic retinopathy.

The number of micro aneurysm (*yellow arrows*) is higher than mild non-proliferative cases.

Flame and dot hemorrhages are visible as tiny hypofluorescent areas (*red arrows*).



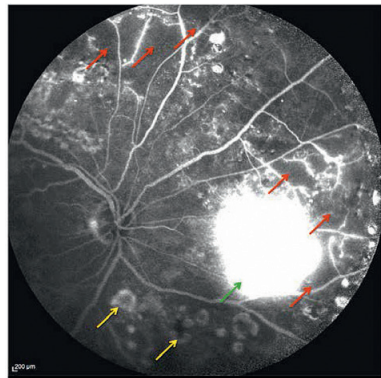
**Figure 4: Severe Non-proliferative Diabetic Retinopathy**

In case of severe non-proliferative diabetic retinopathy several findings may be shown on fluorescein angiograms:

Micro aneurysms and hemorrhages diffusely involve the four quadrants.

Intraretinal microvascular abnormalities (*IRMA*; *green arrow*) develop at the edges of non-perfused areas.

Capillary dropout, determining retinal ischemia is also visible (*red arrows*).



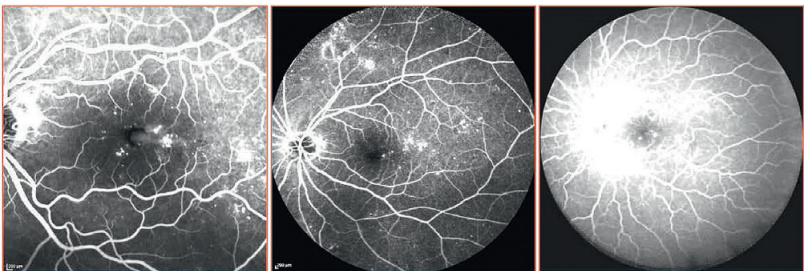**Figure 5: Proliferative Diabetic Retinopathy**

Proliferative diabetic retinopathy is characterized by the presence of retinal or papillary neovascularization.

New-vessels are visible on fluorescein angiography as highly hyper fluorescent areas (*green arrow*) since the early venous phase.

They are topographically correlated with areas of capillary non-perfusion (*red arrows*).

Laser scars are also visible in the image (*orange arrows*).



**Figure 6: Different types of Fluorescein Angiography**

Fluorescein angiography remains the gold standard in evaluating the evolution of diabetic retinopathy. The modern technologies allow varying the width of imaging field. In the images above are reported three examples of DR patients analyzed on 30° (left image), 55° (middle image) and 102° (right image). This is useful because of the possibility of obtaining a detailed comprehensive assessment with a limited numbers of images

The angiographic appearance of IRMA is of collateral vessels that do not leak.

On the other hand, neovascularization is characterized by hyperfluorescent leaking areas that increase in size and intensity as the examination progresses.

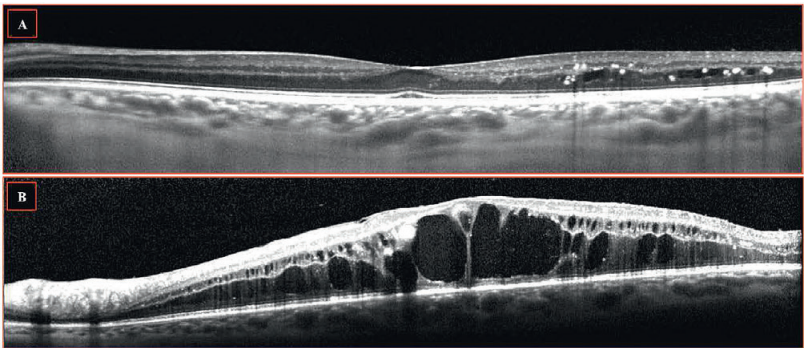
**The earliest change in diabetics** is an increased vascular permeability, which is seen as late hyperfluorescence emanating from the retinal vessels.

If the macula is not clinically edematous (thickened), this hyperfluorescence should not be interpreted as macular edema.

### OPTICAL COHERENCE TOMOGRAPHY

Optical coherence tomography (OCT) has come to revolutionize the management of macular diseases because it can **objectively measure** retinal thickness, which correlates better with visual acuity rather than fluorescein leakage.

Normal fovea thickness as measured by OCT has been reported to be  $152 \text{ \AA} \{ 21\mu\text{m}$ . Diabetic macular edema is imaged as a zone of low reflectivity in the outer retinal layers. The low reflectivity is due to the accumulation of intraretinal fluid.



**Figure 7: Diabetic macular edema on OCT**

Optical coherence tomography (OCT) allows a clear visualization of the macular involvement in case of diabetic retinopathy.

Mostly in case of diabetic macular edema it is able to show and quantify the amount of exudation.

In the images above (A) Very limited parafoveal exudation is visible, associated with hard exudates (intraretinal hyper reflective spots with dark back shadowing).

In image B, a severe macular edema is shown: it entirely involves the macular area, with large intraretinal cystoid spaces, which are mainly located at the level of the inner and outer nuclear layers.

**CHAPTER III**

**OCT-ANGIOGRAPHY**

**TECHNICAL ASPECTS**





## OCT-ANGIOGRAPHY : TECHNICAL ASPECTS

**THE OCT-ANGIOGRAPHY (OCT-A)** is a promising new method to visualize the retinal vasculature and choroidal vascular layers in the macular area.

A key advantage of OCT-A over traditional Fluorescein Angiography (FA) is that it provides depth resolved functional information of the blood flow in the vessels.

In comparison, FA only provides a bi-dimensional (2D) image that superimposes all perfused layers of retinal and choroidal blood vessels.

OCT-A images, in C-scan visualization, often appear similar to FA images, but with additional information. Then, for correct interpretation of the images, it is important to understand the differences between the two modalities.

### Genesis of OCT-Angiograms

The OCT-A is based on the concept that in a static eye, the *only moving structure* in the eye-fundus is blood, flowing in the vessels.

### Signal

A contrast is generated by the difference between moving cells in the vasculature and static surrounding tissue.

### Signal quality

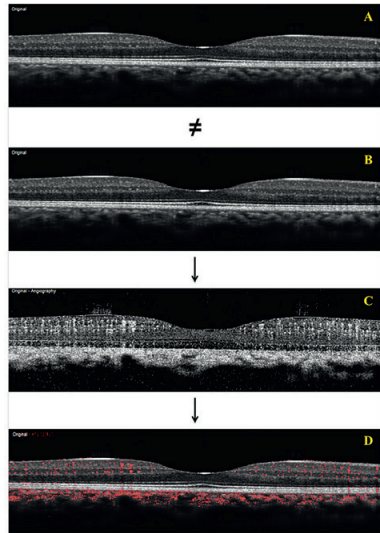
Different contributing factors need to be considered. When performing OCT scans of the retina, the main sources of motion are bulk motion and motion caused by circulating blood.

**Bulk motion** refers to any movement of tissue with respect to the OCT device, such as head movements or eye movements. If bulk motions are sufficiently compensated, the blood circula-

tion is the predominant source of temporal changes between OCT scans.

### Motion caused by circulating blood

OCT scans can then be used to visualize blood flow based on the detection of temporal changes in a sequence of OCT scans.



**Figure 1: Principles of OCT-Angiography**

A and B. The difference between an acquired B-scan (Figure A) and a second one, taken exactly in the same retinal location (Figure B), is computed in order to obtain a decorrelation signal.

C. This decorrelation signal, which mainly due to blood cells flowing in the vessels, is used to achieve an OCT B-scan angiogram (Figure C).

D. The two information, morphological (structural OCT) and functional (OCT-A), may be simultaneously shown in an overlapped mode (Figure D).

## Artifacts

**In order to avoid that any artifacts** arise, a sequence of OCT B-scans has to be taken to detect flow, exactly at the same retinal location (**Figure 1**).

**Artifacts** can be due to scan positioning errors caused by normal ocular micro-saccades.

They commonly occur once every 300 ms (while a typical acquisition time of OCT volume scans, with a reasonable resolution and field of view, takes at least 2-3 seconds to acquire).

## EYE-TRACKING SYSTEM

Therefore an active Eye-Tracking (TruTrack™) presents a very reliable method to acquire OCT volume scans *without motion artifacts*. This eye-tracking method is based on the simultaneous acquisition of fundus and OCT images.

It makes it possible to perform a continuous real-time quality check of the OCT data during the exam. This process ensures that only accurate OCT-images are stored.

**Then, in clinical routine**, the physician (and/or the technician or photographer) will not need to schedule a reexamination of the patient if eye movement or blinking occurred during the acquisition. This TruTrack™ system significantly helps to improve the signal to noise ratio.

## LAYERS SEGMENTATION

**En face OCT-Angiography images** show information about flow detected in a C-scan (en face) section. To visualize blood flow in the different retinal and choroidal anatomic layers, the layered structures have to be identified and *segmented*.

## Full spectrum amplitude decorrelation algorithm

The Eye Tracking System also allows the use of a full spectrum amplitude decorrelation algorithm.

This guarantees a clear differentiation between blood flow and static tissue without sacrificing axial resolution (i.e. depth resolution) of the OCT images.

In this way, **very thin layers** of the vascular network in C-scan section become distinguishable.

**The effect of axial motion** (e.g. the patient is moving towards the camera) must be compensated as well. Our approach is to geometrically align the successive B-Scans before performing the analysis of temporal changes. This is done during the OCT scan acquisition.

In this case, blood flow can be identified, even if strong bulk motion occurred during acquisition.

**Overall, OCT-Angiography** with active eye tracking and proper B-scan alignment yields the desired high definition and geometrical accuracy.

To achieve high resolution OCT angiographies, dense OCT volume scans have to be acquired and each single B-scan of the volume protocol has to be of consistent high quality.

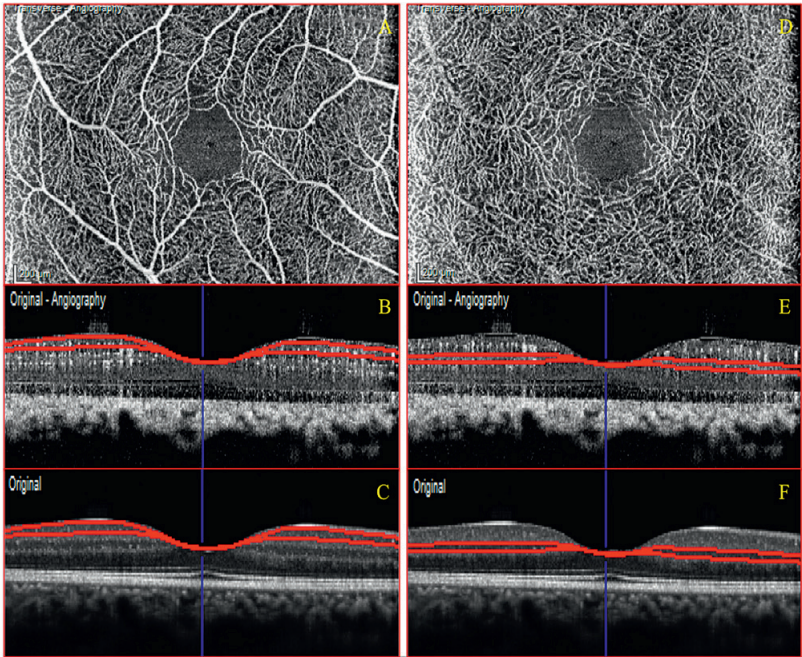
The C-scans sections may be selected with variable thickness. They can be moved at different depths within an OCT volume scan in order to analyze the entire retinal and choroidal tissue in the scanned area.

**Accuracy of layer segmentation** is crucial to produce reliable OCT-A images (obtained with high resolution OCT B-scans).

This can be achieved through *automated* or *manual* layer segmentation. (**Figure 2 and 3**).

## AUTOMATED LAYER SEGMENTATION

The **automated layer segmentation** provides to the clinician a fast way to evidence the presence of a decorrelation-signal, due to perfused vascular structures, in any OCT-Angiograms.



**Figure 2: Automated segmentation on OCT-Angiography.**

(A): **Superficial capillary plexus (SCP)** shown in C-scan OCT-A visualization. This vascular layer is typically identified at the level of the *ganglion cell layer* in macular area.

(B and C). The B-scans show, both in OCT-A (B) and conventional OCT (C), the exact level where the C-scan (A) is taken.

(D): **Deep capillary plexus (SCP)** shown in C-scan OCT-A visualization. This vascular layer is typically identified at the level of the *inner nuclear layer*.

(E and F). The B-scans show, both in OCT-A (E) and conventional OCT (F), the exact level where the C-scan (A) is taken.

**This automated segmentation** is based on the different levels of reflectivity, which are mainly visible on conventional OCT B-scan.

**Each retinal layer** is clearly distinguished from the others due to a different degree of reflectivity that allows the identification of its borders.

### Potential segmentation errors

Nevertheless, this automated segmentation could suffer from potential segmentation errors. These errors especially occur in accentuated macular diseases, which significantly alter the profile and the reflectivity of the neuro-retina.

**The automatically segmented C-scan sections** of the OCT-A are therefore taken at the reported exact histological site, and guided by conventional structural OCT.

**Since there is no clear-cut** in between the different choroidal layers (choriocapillaris, Sattler's layer, Haller's layer), the distinction is commonly done taking in account the mean thickness of each one (OCT and histopatholog-

*The histopathologic findings* allocate the retinal superficial capillary plexus (SCP) in the *ganglion cell layer* (GCL) and the deep capillary plexus (DCP) in the *inner nuclear layer* (INL).

This automated segmentation allows a prompt analysis of different vascular layers.

ic findings) and the vessel's diameter, clearly visible on enhanced depth imaging (EDI-OCT). The software in these cases might be no more capable of correctly **distinguishing the borders** of each retinal layer. It often happens that different layers converge into a single one.

**These errors** cause that, on C-scan, several structures are shown as coplanar, when in fact belong to different layers.

Nevertheless, in case of segmentation errors, the provided software (*Spectralis Software Version 6.0, Heidelberg Engineering, Heidelberg, Germany*) **allows a manual correction** of all the boundaries

### Manual segmentation

**The manual segmentation** allows a fully customizable analysis. It is usually not so much more time consuming than the automated one.

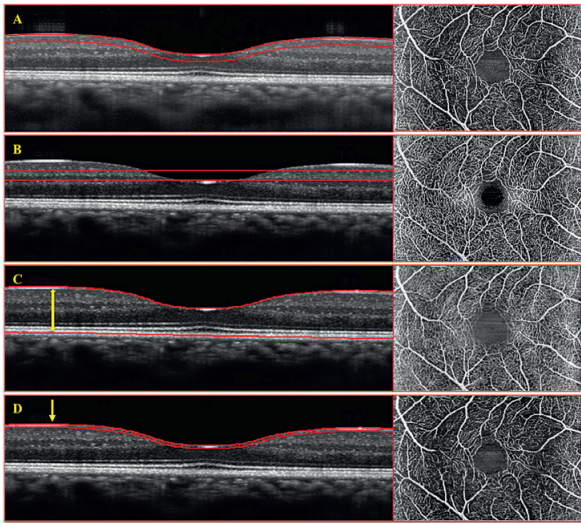
This manual segmentation is based both on the possibility of selecting the C-scan section thickness and on shaping the section on the most suitable profile.

The thickness of any section, in case of manual processing, is very important.

- A thin C-scan section allows distinguishing the finest details of a vascular structure: since, the risk of superimposed image is minimum.

- On the other hand, a thick section might still be useful to analyze a certain layer or lesion in its entire thickness. A thick section may also be a suitable choice to compare a given OCT-angiogram to a conventional, bi-dimensional (2D) FA examination, (in which all the structures are overlapped). (**Figure 3**).

## MANUAL SEGMENTATION in OCT-A



**Figure 3: Manual segmentation on OCT-Angiography.** Each figure (A - D) shows the manual selection of shape and thickness on conventional OCT (left) and the corresponding image in C-scan visualization (right).

(A): **50- $\mu$ m-thick section aligned on the Inner limiting membrane (ILM) profile.** The conventional B-scan OCT shows the exact localization of the section (left). On the right the resulting C-scan OCT-Angiogram.

(B): **50- $\mu$ m-thick horizontal section (right) and the corresponding C-scan in Angiographic mode (left).**

(C): **Thick section (yellow double-arrow) involving the entire neuro-retina between the ILM and the RPE.** The two profiles bordering the section are shaped on the ILM and Ellipsoid Zone (EZ) profile. Such a thick section might be useful when comparing the OCT-A with conventional fluorescein angiography but all the vascular layers as superimposed.

(D): **Thin section (yellow arrow) shaped on the ILM profile.** This approach is useful when needing to distinguish the finest details of a vascular structure.

**The selected profile for the shape** of the different C-scan section significantly impacts the aspect of the obtained images.

In our experience, the most frequently used profiles are **ILM, RPE and BM**. These, because of their high reflectivity, less suffer from potential segmentation errors.

**The ILM profile** is mostly used in case of evaluation of retinal vascular layers, while RPE and BM are useful for outer retina and choroid.

In case of CNV, the neovascular tissue is frequently attached at the back surface of the RPE.

**The horizontal section** is also frequently used in segmenting retinal and choroidal layers. This has the remarkable advantage that does not suffer of potential segmentation errors.

The disadvantage is not being aligned on the concavities or convexities of the eye. In this way different structures, even if at different depth, appear as coplanar.

### CONCLUSION

**The OCT Angiography is a promising addition to multi-modal retinal imaging. OCT-A provides additional functional flow information to the structural detail seen on regular OCT.**

**For a comprehensive assessment, OCT-A associated with regular OCT scans, should be simultaneously viewed in a B-scan and C-scan view.**

**CHAPTER IV**

**IMAGING ACQUISITION PROTOCOL**

**OCT-ANGIOGRAPHY SPECTRALIS\*.**



**HOW TO ACQUIRE IMAGES**





## ACQUISITION PROTOCOL

### Spectralis OCT-Angiography: how to acquire images

**The concept underlying OCT-A** is that in a static eye, the only moving structure in the fundus is blood, flowing in the vessels.

OCT-A generates contrast in a full depth-resolved data set by differentiating between moving cells in the vasculature and static surrounding tissue without requiring dye injection.

The image obtained allows visualization of the channel of perfused vessels. This **signal** returning from moving features and its amplitude vary rapidly over time.

**This signal is obtained by calculating the amplitude of decorrelation** from repeated consecutive B-scans at the same cross-section.

A contrast between static and non-static tissue is created and generates a vascular decorrelation **signal** that enables visualization of three-dimensional retinal and choroidal vasculature<sup>1-2</sup>.

**The prototype “Spectralis OCT2” device** (*Spectralis, Heidelberg Engineering, Heidelberg, Germany*) has been used to acquire the images.

This prototype is able to acquire 85,000 A-scans per second, with a resolution of 7  $\mu\text{m}$  axially and 14  $\mu\text{m}$  laterally, and a bandwidth of 50 nm.

The ocular light power exposure was within the *American National Standards Institute safety limit*.<sup>3</sup>

**An amplitude decorrelation algorithm** developed by Heidelberg Engineering (Heidelberg, Germany) is applicable to a volume scan, on a 15 x 5° or 15 x 10° area (4.3 x 1.5 mm or 4.3 x 2.9 mm), which is composed of a variable number of B-scans (ranging from 131 to 261 respectively) at a distance of 11  $\mu\text{m}$  each (this value is very near to the limit of the eye resolution).

The prototype device, by the use of the **Automated Real Time (ART)** mode allows varying the number of frames per scan, in order to average the image, increase the quality of each single B-scan and improve the signal-to-noise ratio.

**The B-scan OCT-A** is generated by computing the decorrelation in between successive standard B-scans that are sequentially acquired at the same location. The **decorrelation** between each acquired B-scan and a second one taken in the same location is assessed in order to obtain an *OCT B-scan angiogram*.

**The C-scan (en-face)** visualization of this OCT-A is automatically derived from these OCT B-scan angiograms. The ART mode associated to the limited distance in between two consecutive B-scans (11  $\mu\text{m}$ ) allowed obtaining the best high-resolution C-scan angiogram.

Every OCT-A is simultaneously achieved with the corresponding standard OCT B-scan; in this way, the *visualization of both retinal/choroidal functional and morphological aspects* are acquired.

## AUTOMATED SEGMENTATION ALGORITHM

An automated segmentation algorithm for both retinal and choroidal layers is provided with the OCT-A software (*Heyex Software Version 1.9.201.0, Heidelberg Engineering, Heidelberg, Germany*).

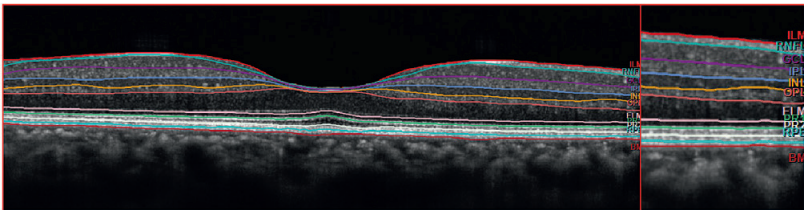
**This algorithm** is capable of identifying *eleven different retinal layers*, from the ILM to the RPE, including the external limiting membrane (ELM), the ellipsoid zone (EZ - "PR1") and the outer segment (OS - "PR2").

The possibility of having a precise distinction between the different layers is a useful function in conventional structural mode, because it easily allows to define the axial extension of a given lesion in retinal tissue.

**Moreover, in OCT-Angiography**, it acquires an essential role because rapidly shows an exact morpho-functional correspondence: a given decorrelation signal, due to a perfused structure, is topographically localized.

Since the vascular and avascular layers are well known, the presence (or absence) of perfusion in a location may significantly help in distinguishing a normal condition from an abnormal one, aiding not only in diagnosis, but also in treatment decision.

In case of accentuated macular retinal/choroidal disruptions, causing potential segmentation errors, a specific manual correction allows to modify the shape and the localization of each layer.



**Figure 1: Automated Segmentation Algorithm:** Eleven different layers are identified by the automatic segmentation.

They represent respectively the inner limiting membrane (ILM), the retinal nerve fiber layer (RNFL), the ganglion cells layer (GCL), the inner plexiform layer (IPL), the inner nuclear layer (INL), the outer plexiform layer (OPL), the external limiting membrane (ELM), the ellipsoid zone (PR1), the outer segment (PR2), the retinal pigmented epithelium (RPE) and the Bruch's membrane (BM).

The possibility of having a precise distinction between the different layers is a useful function both in conventional and in angiographic mode: it easily allows defining the localization, the axial extension of a given lesion and the eventual presence of a perfused structure in the examined tissue.

In case of manual segmentation, **the thickness of every C-scan** may be modified in order to have a given constantly thick “slice of tissue” at different retinal or choroidal levels. Therefore, this approach allows a detailed analysis of all the structures included in a certain “slice of tissue”, obtained in “en-face” visualization.

As already described the manual selection of the C-scans at different depth may be obtained both with horizontal or variably shaped sections.

A **horizontal** section (not aligned to any retinal layer) might be chosen with aim to reduce artifacts due to segmentation errors.

The different shapes, according to our experience, may be chosen on the base of several parameters:

*First of all the presence of segmentation errors:* when the profile of the C-scan is not perfectly aligned on the structure taken as reference (i.e. ILM, RPE, BM), it is better to avoid this approach, in order not to have risks of superimposition or missing structures in the C-scan.

*Secondarily it is important to consider the layer or the lesion* that will be analyzed. For example, when imaging a CNV lesion, it might be important to have a C-scan shaped on the RPE profile, since the neovascular tissue is often attached at the back surface of the RPE.

### OCT-ANGIOGRAPHY: B-SCAN AND C-SCAN

Almost all the OCT-A images reported in the different manuscripts are **C-scans**. This is mainly done to have both an excellent “*en face*” visualization of the examined structure. The image is, at least partially, *comparable to* the conventional dye-angiography.

*Finally, the concavity or convexity of the scanned area* should be considered. In some conditions, such as high myopia or dome shaped macula a section aligned on RPE or BM may be more suitable than an horizontal one, since the latter would show different structures (far one to the other) in the same C-scan.

**In this Atlas**, the Authors selected case-by-case the most appropriate shape and thickness of the C-scan section, in order to provide the best image quality in the most significant C-scan.

In case of retinal vascular disease, such as artery/vein occlusion or, as in this “*Atlas of diabetic retinopathy*”, it is important to analyze the entire retinal thickness.

This procedure is necessary not only to have a comprehensive assessment of the scanned tissue, but also to exclude potential artifacts, which might condition the diagnostic process.

Therefore, mostly in case of non-automated segmentation, the **selected C-scan was manually fine-tuned** (by the Authors) to be located at the level of the inner limiting membrane (ILM), and then moved progressively deeper, with steps, corresponding to the same thickness of the section, up to the RPE.

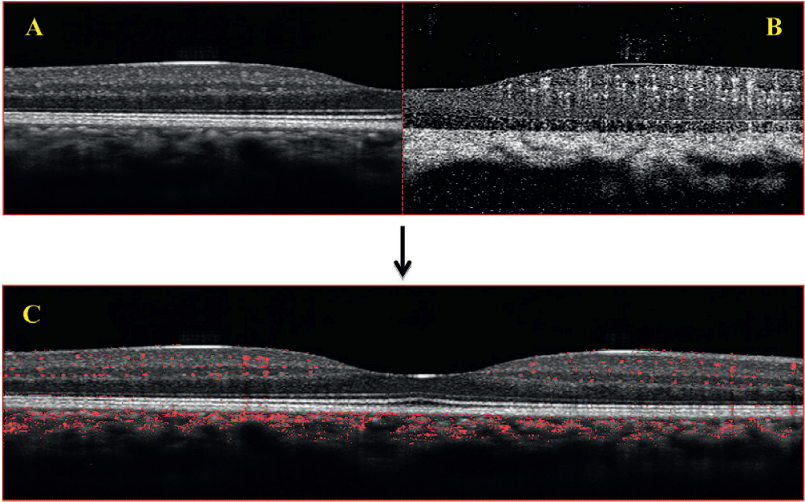
In case of simultaneous outer retinal or RPE-BM changes, the entire choroidal thickness (up to the choroidal-scleral interface) was evaluated.

Nevertheless also the B-scan visualization on OCT-A may give useful information.

It provides, in fact, a clear depth-resolved visualization of a given decorrelation signal.

Since the conventional B-scan is simultaneously obtained with the OCT-A one, it is possible to correlate a precise anatomical position (conventional structural B-scan) with the presence of a perfused structure.

This OCT-A B-scan is important in case of pathological conditions: as it allows to rapidly co-localize functional and morphological information in the same B-scan, both the presence and the activity of a given disease are provided.



**Figure 2: OCT-Angiography B-scan**

A and B: OCT B-scan passing through the center of the foveal depression is simultaneously shown in conventional (Figure A) and in angiographic mode (Figure B).

B: In the OCT-A B-scan (Figure B) are shown as hyper intense only perfused structures, such as retinal vascular layers, choriocapillaris and choroid. Highly hyper-reflective layers such as ILM, EZ or RPE on conventional B-scan are characterized by a clear hypo-intense signal, since, in healthy subjects, there are no perfused structures at this level.

C: Example of morpho-functional examination in B-scan. The background is made by the conventional morphological OCT finding in macular area of a healthy subject, **while in red is shown (as superimposed)** the signal coming from the perfused structures which are only appreciable in angiographic mode.

## REFERENCES

1. Jia YI, Bailey ST1, Wilson DJ1, et al. Quantitative optical coherence tomography angiography of choroidal neovascularization in age-related macular degeneration. *Ophthalmology*. 2014 Jul;121(7):1435-44.

2. Moul E, Choi W, Waheed NK, Adhi M et al. Ultrahigh-speed swept-source OCT angiography in exudative AMD. *Ophthalmic Surg Lasers Imaging Retina*. 2014 Nov-Dec;45(6):496-505.

3. American National Standards for safe use of Lasers, ANSE Z136. Orlando, FL: laser Institute of America; 2007:1-2007.

## **CHAPTER V**

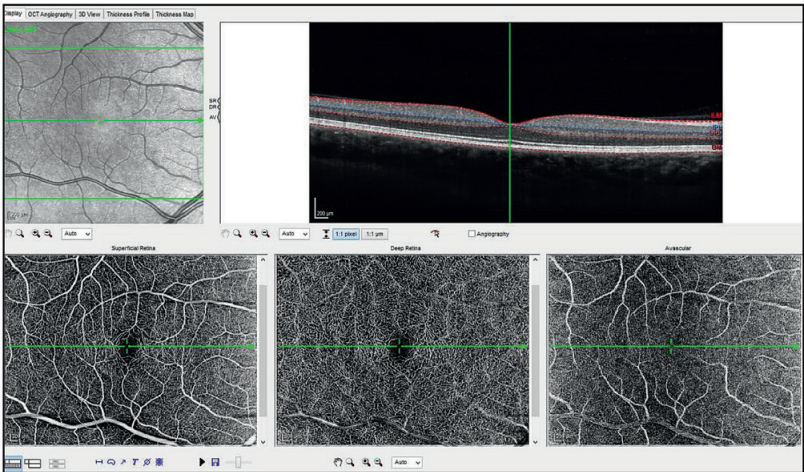
# **OCT-A-SCREEN VIZUALIZATION**



## OCT-A SCREEN VISUALIZATION

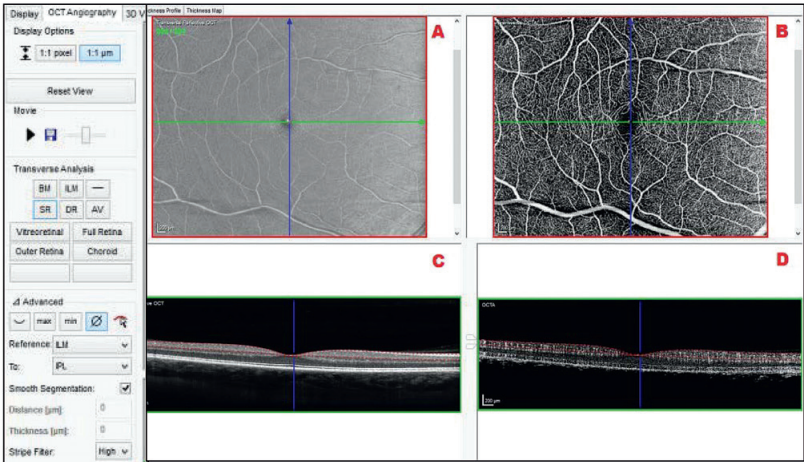
The image above shows the aspect of a Spectralis OCT Angiography in Heyex Software

(Heyex Software Version 1.9.201.0, Heidelberg Engineering, Heidelberg, Germany).



This “Display” view simultaneously shows the reference image in infra-red (*top left image*), the B-scan in structural or in Angio-mode (*top right image*), the superficial capillary plexus

(*bottom left image*), the deep capillary plexus (*bottom middle image*) and the avascular retina, from outer nuclear layer to Bruch’s membrane; (*bottom right image*).



The **OCT-Angiography** screen is a combined visualization of the **structural** (A, C) and the **angiographic** images of a given slab.

This image is a morpho-functional assessment of a C-scan (or B-scan) section.

- **Image A** is the “En Face” visualization of the structural OCT

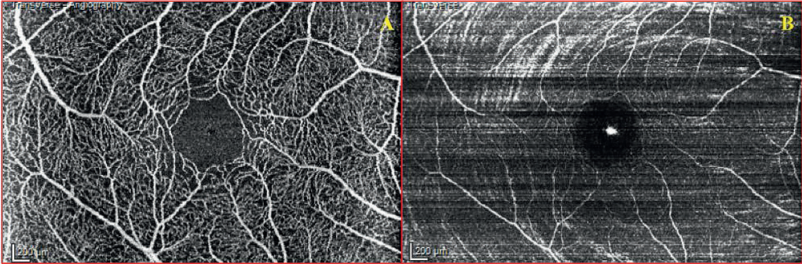
- This case is taken at the level of the ganglion cells layer.
- **The two lines**, one horizontal (green) and one vertical (blue) identify the exact position of two cross sectional B-scans (*green ones shown in C and D*).

- **Image B** is the angiographic visualization of a C-scan section taken at the same level of depth of Figure A (ganglion cells layer). [It shows the superficial capillary plexus of an healthy subject.]

- **Image C** (structural B-scan; *green line in Figures A and B*) is useful to evaluate the level of depth of the C-scans above and the quality of the segmentation algorithm. (Red lines)

- **Image D** (Angio-mode B-scan; *green line in Figure A and B*) is the corresponding B-scan in Angio mode of Figure C. (It is extracted from a volume scan on a  $15 \times 10^\circ$  centered in macular area).

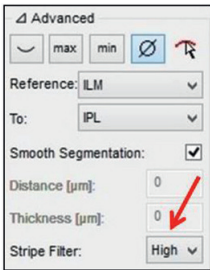




**Figure 1: Comparison OCT-A versus Conventional OCT C-scans**

- A The OCT-A C-scan ( ) allows a clear "en face" visualization of the different vascular layers, which are well defined and distinguished from the avascular areas.
- B On the contrary the conventional C-scan, shows only the larger trunks of retinal vessels, as hyper reflective structures.

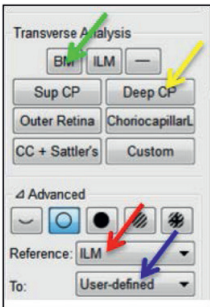
*This image is not fully interpretable also due to the reflectivity of the retinal nerve fiber layer that partially masks the image of the deeper structures.*



The red arrow highlights the "Anti Stripes Filter", a useful tool to reduce the noise.

The image quality in OCT-Angiography is fundamental to obtain exams of sufficient high resolution to be interpreted both qualitatively and quantitatively.

- To achieve this aim it is necessary to increase the **signal-to-noise ratio**.
- This parameter is automatically set to "high" level.



The possibility of selecting manual segmentation (green arrow) rather than an automated one (yellow arrow), is evidenced in this picture.

- Different C-scan sections (i.e. Superficial Capillary Plexus, Deep Capillary Plexus, Outer retinal layers, Choriocapillaris) can be provided by the automated segmentation.
- Different others can be obtained by the operator in a fully customizable context.
- This could be done by selecting a reference line (red arrow).
- A second plan (blue arrow) may be obtained by the automated segmentation algorithm.

## IN CASE OF MANUAL SEGMENTATION

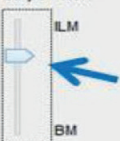
Smooth Segmentation:	<input checked="" type="checkbox"/>
Distance [ $\mu\text{m}$ ]:	20
Thickness [ $\mu\text{m}$ ]:	45
Stripe Filter:	High $\downarrow$

- The **Distance** from a given structure (*red arrow*) and
- The **Thickness** of a C-scan (*green arrow*) can be selected by the clinician in order to clearly visualize in each C-scan, every element included in a pre-established B-scan.

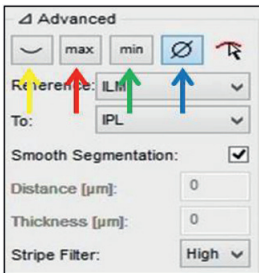
- The **“Distance”** is an evaluation (in micron [ $\mu\text{m}$ ]) of how far is a given section from a reference plan (i.e. RPE, BM, ILM,...). When a C-scan section is not linear, but has its own thickness, the “Distance” value means how far is the middle point of the C- scan from the reference plan: Its value is positive when moved toward the vitreous cavity or negative when moved toward the sclera.
- The **“Thickness”** expresses the exact thickness value (in micron [ $\mu\text{m}$ ]) of a given C-scan. It could be manually selected and range from “0”, in case of linear section, to “500” in case of the thickest section.

Smooth Segmentation:	<input checked="" type="checkbox"/>
Distance [ $\mu\text{m}$ ]:	0
Thickness [ $\mu\text{m}$ ]:	0
Stripe Filter:	High $\downarrow$

- **In order to achieve** a better segmentation
  - the “smooth segmentation” is normally turned on.
  - It automatically realigns the consecutive segmented B-scans.
  - It is possible to switch it off in to obtain non-modified segmentation

Smooth Segmentation:	<input checked="" type="checkbox"/>
Rel. Position [%]:	29
Thickness [ $\mu\text{m}$ ]:	40
Stripe Filter:	High $\downarrow$
	

- The **thickness** of a given section could be modified by moving the cursor from ILM to Bruch’s membrane (*blue arrow*).
- The analyzed plan varies both on structural and angiographic images.



- **The advanced functions,**
  - give the possibility to modify the *contrast of a given C-scan,*
  - in order to highlight structures with a high decorrelation signal,
  - or the surrounding hypo-intense ones.
- **This function is only applied to the structural C-scan and not to the one in Angio-mode.**

- **The Yellow arrow** is the standard contrast in case of line scan (*C-scan thickness equal to 0*).
- **The Red arrow** indicates the “*Maximum Intensity Projection*” function, which highlights **all the hyper-reflective signals** coming from hyperreflective structures.
- **The Green arrow** indicates the “*Minimum Intensity Projection*” function, which highlights **all the hypo-reflective signals** coming from hypo reflective structures.
- **The Blue arrows** indicate different pre-set levels of “*Mean Intensity Projection*”, function, which take simultaneously in account **both hyper and hypo-reflective signals** and average their different degrees in order to highlight the distinction between different reflectivity.

## QUALITY INDEX

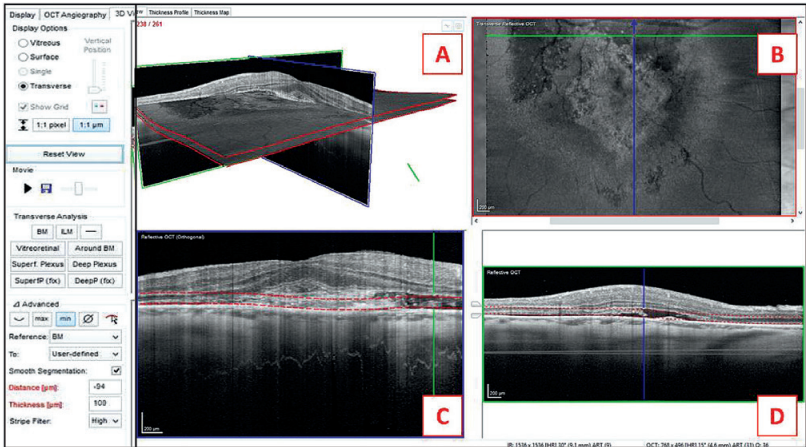
The **Spectralis Software** (*Heidelberg Engineering, Heidelberg, Germany*) measures the signal strength by a “Quality Index” (QI) and assigns a number expressed in decibel (dB), ranging from 0 (low quality) to 50 (excellent quality).

**This quality index (QI)** is influenced by several elements, such as media opacities or the photographer experience.

**In this type of examination, both for the qualitative and quantitative approaches, the nearer the QI value is to its maximum, the more the fine details of the lesion will be visible and therefore able to be analyzed and interpreted.**

In a former version of the software there was:

- A screen «3D View» useful to analyze images in structural mode



**Image A** is a combined visualization of the three other plans (B, C, D). This image is useful to analyze the spatial relationship between them.

**Image B** is the “En Face» visualization of the structural OCT:

- **The two lines**, one horizontal (green) and one vertical (blue) identify the exact position of the two B-scans shown in image C and D.

**Image C** (orthogonal structural B-scan; blue line in Figure B) is useful to evaluate the quality of the segmentation algorithm. (Red lines)

**Image D** (original structural B-scan; green line in Figure B) is one single B-scan extracted from the volume scan on a  $15 \times 10^\circ$  centered in macular area.

## **CHAPTER VI**

### **OCT-Angiography :**

### **HOW TO OBTAIN IMAGES**



## HOW TO OBTAIN IMAGES

The potential technical approaches, which allow obtaining the most representative OCT-A images, may be very numerous.

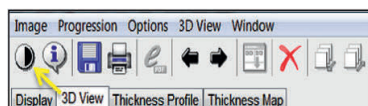
*images*, which might result suitable, in case of choroidal and retinal vascular diseases and in case of *Diabetic Maculopathy*.

*The Authors*, with this specific chapter would like to provide *one possible way of selecting*

The following steps in OCT-A images analysis may be performed in variable order.

### 1) CONTRAST SELECTION

#### FIRST STEP:

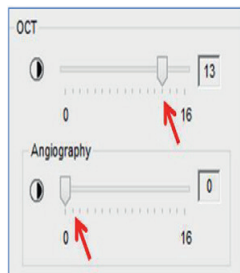


- In the upper bar, the first icon on the left, represents the access menu for the general contrast selection of the image (*yellow arrow*).

- Both the “Infrared” (IR) and “OCT image” contrast may be adjusted with this option. (In this case, we are only interested in the OCT image, because the IR reference image is not shown in the Screen)

#### SECOND STEP:

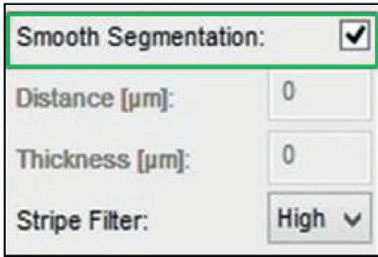
- The **OCT contrast** setting may assume different values ranging from 0 to 16. It could be modified by moving the cursor along the scale (*red arrows*).



- The contrast may be separately varied for the structural OCT and the OCT-Angiography.
- In case of **Angio-mode (OCT-A images)**, the Authors generally use the 0 value: in this way the contrast between perfused (hyper-intense) and non-perfused (hypo-intense) structures is *maximum*
- In case of **conventional OCT** (when the Angio-mode is not selected), the contrast should be set on *higher value*. This, in the largest part of the cases, varies between 9 and 12.

## 2) SMOOTHING SEGMENTATION LINES

THE NEXT STEP is to flag the “Smooth segmentation lines” function.

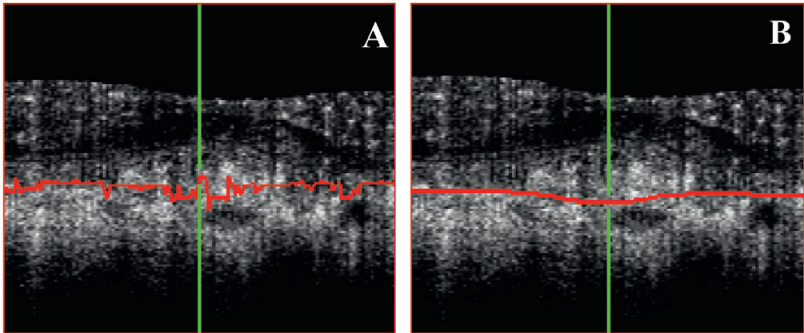


The **segmentation process** may suffer of potential errors due to severe retinal changes in case of pathological conditions.

The *Heyex Software* (Heyex Software Version 1.9.201.0, Heidelberg Engineering, Heidelberg, Germany) provides a “smoothing” mode, which re-aligns all the different layers averaging the level and excluding the most misaligned ones.

### ANALYSE OF SEGMENTATION ERRORS

**Figure A** shows numerous (micro-) misalignments of the Bruch’s Membrane (BM) in the “orthogonal” section. These segmentation errors have been solved in **Figure B** after having turned on the “smoothing” mode (**Figure 1**).



**Figure 1: Automated correction of segmentation errors**

A: The “*orthogonal*” visualization shows numerous (micro-) misalignments of the red line, which should in fact exactly follow the profile of the Bruch’s membrane (BM).

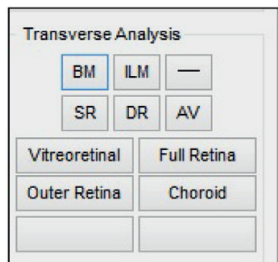
B: The automated correction of these segmentation errors is provided with the “*Smooth segmentation lines*” function: when turned on, all the points, composing the red line, are re-placed and will define the exact position of the BM.



### 3) SELECTION OF THE SECTIONS OF INTEREST

The selection of the different sections of interest may start from the “automatically” provided scheme.

The main sections in case of retinal vascular diseases are:



- **Superficial Retina (SR) or “Superficial Capillary Plexus”** (SCP), which includes the ganglion cells layer.
- **Deep Retina (DR) or “Deep Capillary Plexus”** (DCP), which is analyzed in a C-scan showing the entire inner nuclear layer.
- **Avascular Retina (AV)**, which includes all the different layers between outer nuclear layer and Bruch’s membrane.

In case of **outer retinal - RPE - choroidal disease**, a section set “around Bruch’s Membrane” (**around BM**) might be useful because often able to show, as in case of choroidal neovascularization (CNV), both pre-epithelial and sub-epithelial component of the lesion.

All the different sections, especially for the outer retina and choroidal layers (where borders are not clearly distinguishable), could be adapted in a fully customizable way by the operator.

#### POTENTIAL SEGMENTATION ERRORS

In case of evident **residual segmentation errors** (sometimes the “smoothing” mode is not sufficient to compensate them) a manual segmentation may be preferred.

Then, **using manual segmentation**, a reference plan can be aligned on the more “correctly

segmented” retinal layer or it may be a horizontal section.

BM, RPE, or ILM profiles are also often chosen **as reference shape** in manual segmentation: this because, they are generally better identified by the OCT software and less suffer from potential segmentation errors, due to their high reflectivity on conventional OCT.

The **horizontal section** is useful because does not suffer from segmentation errors.

Nevertheless, in case of accentuated concavity or convexity of the scanned area, it may show in the same C-scan (therefore as coplanar) structures belonging to different levels of depth. This risk tends also to increase when enlarging the horizontal diameter (X-axis) of the scanned area: 30° or 20° are less indicated than 15° when using a horizontal section.

#### 4) SELECTION OF SECTION THICKNESS (MANUAL SEGMENTATION)

Reference: ILM ▼

To: User-defined ▼

Distance [µm]: 47

Thickness [µm]: 25

- The **thickness of the section** should be established, once selected the most suitable section shape, in case of manual segmentation,

- In this example, aligned on ILM, (user defined), the **distance** may be adjusted as previously explained.

- The **section thickness** may substantially vary on the base of the structure to be analyzed.

A **thin C-scan section** (up to 30 µm) is generally used to detect the finest details of a given lesion or of a vascular layer.

A **thicker C-scan section** gives a more comprehensive visualization of the analyzed tissue

and the image may result more smooth

**But tiny** structures are less visible mainly because different layers are superimposed in a unique thick section.

#### ANALYSIS OF RETINAL VASCULAR LAYERS WITH MANUAL SEGMENTATION

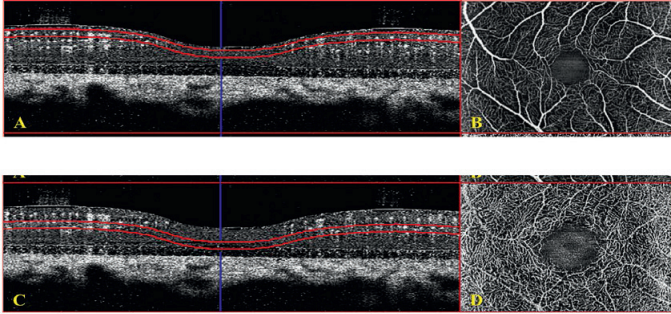
When **analyzing (manual segmentation) retinal vascular layers**, such as superficial or deep capillary plexuses, it is not possible to precisely establish the thickness of the C-scan.

Different pathological conditions may substantially vary the morphology of the retinal layers in which the vascular structures are included.

The operator should therefore carefully examine the B-scan section, both in conventional and in Angio-mode.

Then select the most suitable thickness, reducing the risk of including in a single C-scan, different vascular layers. (**Figure 2**)

## MANUAL SELECTION OF C-SCAN THICKNESS



**Figure 2: Two examples of manual selection of C-scan thickness.**

The two capillary plexa (superficial and deep) should be shown as well-distinguished entities.

A- The two borders of the C-scan (*red lines*) are aligned on the ILM profile and separated by a distance of  $40\ \mu\text{m}$  (this thickness allowed to include the ganglion cell layer and some part of the inner plexiform layer in healthy subjects).

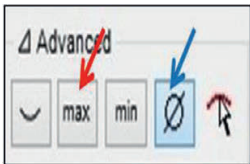
B- Even if the ganglion cells layer is not perfectly outlined, in the "en face" visualization, almost all the structures belonging to the SCP including the perifoveal capillary arcade, are clearly visible.

C- The two borders of the C-scan (*red lines*) are aligned on the ILM profile and separated by a distance of  $40\ \mu\text{m}$  (this thickness allowed to include the inner nuclear layer and some part of the outer plexiform layer in healthy subjects).

D- Even if the inner nuclear layer is not perfectly outlined, in the "en face" visualization, the DCP is clearly shown, although some poorly defined images of large retinal vessels remain visible.

### 5) SELECTION OF C-SCAN INNER CONTRAST

The *Heyex Software* gives also the possibility to vary the inner contrast of each selected C-scan section in structural OCT.



- **RED ARROW:** A "Maximum Intensity Projection" function highlights **all the hyper-reflective signals** in a given C-scan.
- **BLUE ARROW:** A "Mean Intensity Projection" function takes simultaneously in account **both hyper-reflective and hypo-reflective signals** and averages their different degrees in order to highlight the distinction between different degrees of reflectivity.

In the Author's experience, the two described (*Maximum Intensity Projection* and *Mean Intensity Projection*) **are the most useful ones.**

As specified in the previous chapter, there are also other different functions, which may be selected. (See Chapter III)

## 6) IMAGE SELECTION

Once all the previous steps have been achieved, it is possible to start the **selection of the different images**

**In case of automated segmentation**, this procedure is obviously not necessary since the image of the section of interest has already been provided when choosing the different options.

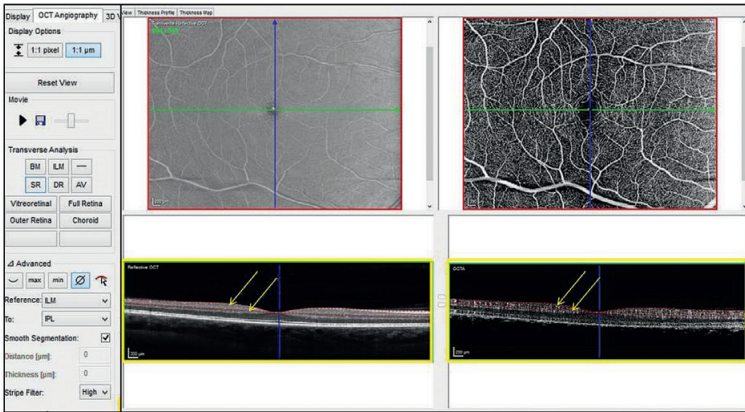
**In case of manual segmentation**, this procedure is needed because only the shape (alignment) of the section is selected, but not its depth in tissue.

The most rapid way to move the C-scan, is to drag the two *red lines* in the “Original Angiography” quadrant (*bottom right B-scan*,

*Figure 4*) upward (toward the vitreous cavity) or downward (toward the choroid) until the decorrelation signal to be investigated is included in the section. (**Figure 4**). This procedure may also be guided by the structural OCT B-scan (*bottom left image*).

**A given retinal or choroidal layer can be selected** in order to be sure that the borders of the C-scan are perfectly aligned on the ones of the investigated layer.

The importance of this method is due to the capability of **rapidly identify an abnormal perfusion** since the exact localization of normal retinal and choroidal vessels is well known.



**Figure 4: Selection of the image depth in tissue**

The bottom images (*yellow squares*) of the screen show the B-scans both in structural (*bottom left*) and angiographic (*bottom right*) mode, which form the volume scan. To scroll from one level of depth to another is sufficient to turn up (or down) the mouse wheel.

The two *red lines* (*yellow arrows*) represent the borders and the thickness of the C-scan section shown in the top images (*top left*: structural C-scan; *top right*: OCT-A C-scan). These may be dragged upward or downward till the layer or the structure to be examined is completely included in between the two.

This approach is very fast and useful, but may be not sufficiently precise because the large shifts of the *red lines*. Micrometric shifts of the *red lines* may also be obtained by locating the cursor on the top right image (C-scan) and then turning up (or down) the mouse wheel.

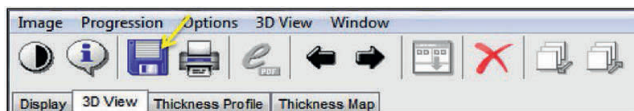
This function allows to carefully positioning the C-scan in order to show the most reliable image.

The manual segmentation may be a valid choice both in case of retinal and choroidal vascular diseases.

Sometimes, in the Author's experience, the entire retina and choroid should be segmented step by step, from the ILM to the choroidal-scleral interface and in these cases the manual segmentation is obviously the only possible approach.

## 7) IMAGE EXPORT

THE FINAL STEP to obtain the image is to export the image



- In the upper bar, the third icon (*yellow arrow*) on the left, represents the **access menu** for the image export.
- When the desired image is shown on the screen, it is sufficient to access the export function and choose the folder and the preferred format.
- The Authors export the image, both in conventional and in angio-mode, for each patient.

This procedure is done with the aim to simultaneously have the morphological and functional information for each C-scan.

- *In case of retinal vascular diseases*, the minimum number of images to be exported is 2: one for the superficial capillary plexus and another one for the deep capillary plexus.

- *In case of outer retinal - RPE - choroidal diseases*, the number of images that have to be

selected could be higher because lesions may be both above and below the RPE.

- Moreover, to avoid the risk of superimposition, more than one thick section should be taken.

In some cases, such as chorio-retinal anastomoses, the entire retinal and choroidal thickness might be evaluated to have a **comprehensive analysis of the lesion**.



**CHAPTER VII**

**OCT-ANGIOGRAPHY  
IN HEALTHY SUBJECTS**





## SPECTRALIS OCT-ANGIOGRAPHY IN NORMAL SUBJECTS

**The traditional multimodal imaging**, such as fluorescein angiography (FA), indocyanine green angiography (ICGA), and spectral-domain optical coherence tomography (SD-OCT), was leading to a better understanding of the pathophysiologic features of retinal and choroidal diseases<sup>1</sup>

It allowed to obtain information about the normal retinal and choroidal anatomy, nearly comparable to histological findings.

**Moreover, the angiographies** (both FA and ICGA) provided essential dynamic information on the perfusion of different retinal and choroidal vascular layers, including the transit time from arm to the eye.

This resulted absolutely fundamental in the evaluation of all retinal and choroidal vascular diseases and, added to the morphological data, allowed the clinician to detect diseases and define the correct diagnosis.

**Fluorescein angiography** has become generally accepted as the "*gold standard*" in imaging the fundus, due to the fact that FA is the best, if not the unique, method to visualize the retinal capillary bed, its dilation or perfusion, particularly in macular area.

Moreover, FA will allow the clinician to detect and analyze one main clinical sign: *leakage* from abnormal and/or (retinal or choroidal) new-vessels.

Although fluorescence of the injected dye enabled improved visualization of retinal capillaries, it was well known that not all the differ-

ent layers of the retinal capillary network could be visualized in this bi-dimensional examination.

It was reported that fluorescein angiographic images of the retina corresponded to the anatomical arrangement of the superficial retinal vessels, whereas the deeper retinal capillaries were not visualized in the angiogram.<sup>2,3</sup>

**Comparable histo-pathological correlations** in humans are not been reported, but comparative findings suggest the deeper capillary network in the retina is not visualized well by fluorescein angiography, possibly because of light scattering of the retina.<sup>4</sup>

Therefore, even if the FA is the gold standard for the visualization of retinal vessels, one of the two major capillary networks do not appear to be imaged well, despite the retina appear a nearly transparent structure.<sup>5</sup>

**Optical coherence tomography angiography (OCT-A)**, allows a clear, depth-resolved visualization of the retinal<sup>5</sup> and choroidal microvasculature<sup>6</sup>, by calculating the decorrelation of signal between static and non-static tissue.

Given that the main moving elements in the eye fundus are contained in vessels, determining a vascular decorrelation signal enables visualization of three-dimensional retinal and choroidal vascular network.

<sup>7</sup>Moreover OCT-A does not require administration of intravenous dye, reducing the risk of potential adverse events.<sup>8</sup>

## RETINAL AND CHOROIDAL VASCULAR ANALYSIS IN HEALTHY SUBJECTS

### Retinal Vascular Anatomy

**Generally, the blood-supplying artery** to the inner retina is the central retinal artery that following the inferior margin of the optic nerve enters the eye at the level of the optic nerve head.

**The central retinal artery** divides to form two main branches and each of these divides again to form the superior nasal and temporal and the inferior nasal and temporal arteries that supply the four quadrants of the retina.

**The retinal venous vessels** are distributed in a similar pattern.

**Many anatomical variations** in this division and distribution may be observed in the normal fundus. The major arterial and venous branches and the successive divisions of the retinal vasculature are present in the Retinal Nerve Fiber Layer (RNFL) close to the Internal Limiting Membrane (ILM).

**The retinal arterial circulation** is a terminal system with no arterial-venous communication with other arterial systems.

Thus, the perfusion of a specific retinal quadrant comes exclusively from a given retinal artery and vein that supply that area (in the most frequent normal distribution of the vessels).

Any impairment or blockage in blood supply therefore causes an ischemia or infarction. As the large arteries extend within the retina toward the periphery, they divide to form successive level of arteries with progressively smaller diameters until they reach the ora serrata.

**The retinal arteries** branch dichotomously or at right angles from the original vessel.

The arterioles coming from the retinal arteries form an extensive capillary network in the inner retina as far as the external border of the Inner Nuclear Layer (INL), either toward the periphery and/or in the macular area.

**Many macular arterioles**, branching from the temporal (superior and inferior) retinal arteries, dive into the retina forming the macular capillary bed with two distinct capillary plexus:

- one in the Ganglion Cell Layer (GCL) (*Superficial Capillary Plexus, SCP*) and
  - the other in the INL (*Deep Capillary Plexus, DCP*).
- An *intermediate capillary plexus* is also described between the inner plexiform layer and the inner nuclear layer.

Since the difference between the intermediate capillary plexus and the inner component of the deep capillary plexus is difficult to establish, they are commonly considered as a unique entity.

Generally, no vessels extend deeper than the inner nuclear layer. The outer retinal layers and photoreceptors receive their blood supply not from the retinal capillary bed, but from the Choriocapillaris.

**A cilio-retinal artery**, originating from the short posterior ciliary artery, enters, in less than 20% of the cases, the retina on the temporal side of the optic nerve and reaches the macular area, ending in a capillary plexus, in the retinal vasculature.

## FLUORESCEIN ANGIOGRAPHY IN HEALTHY SUBJECTS

Fluorescein Angiography images, in the current Atlas, were obtained by the use of a confocal imaging system (*Spectralis HRA2, Heidelberg Engineering, Heidelberg, Germany*).

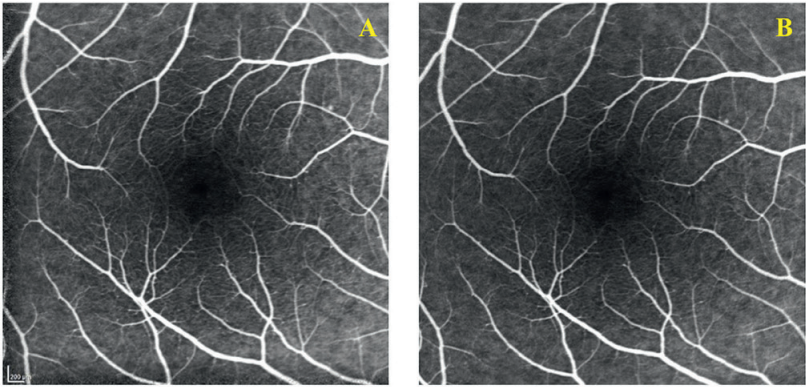
This system captures only light emitted in a predetermined plane and consequently eliminates artifacts (due to reflection and diffraction) and superimposed images.

**The macular capillary bed**, including the delicate peri-foveal anastomotic arcade, may be visualized in case of clear media and good con-

trast. This arcade will precisely delimitate the **Foveal Avascular Zone (FAZ)**.

A **very fine and specific focusing** in some rare cases, could help to distinguish some differences between *Superficial Capillary Plexus, (SCP)* and *Deep Capillary Plexus, (DCP)*.

Imaging them may require successive focusing. Fine structures, including pathologic condition as neovascularization, are then, clearly visualized.



**Figure 1:** Fluorescein angiography in early artero-venous phase.

**(A):** Both retinal vein and arteries and macular branches are fully perfused: there is no evidence of any filling impairment. The *superficial capillary plexus* is mainly visible in perifoveal area. The perifoveal arcade is not completely appreciable

**(B):** Fluorescein angiography in early arterial-venous phase focused deeper than in (A) to obtain information of deep retinal vessels. The *deep capillary plexus*, although the focusing process, remains not appreciable because of retinal light scattering.

## RETINAL OPTICAL OCT-A IN HEALTHY SUBJECTS

All the OCT-A examinations were performed by the use of a Spectralis OCT2 Angiograph prototype (Heidelberg Engineering, Heidelberg, Germany) that was able to acquire 85,000 A-scans per second with a resolution of 7  $\mu\text{m}$  axially at an imaging depth of 1.9 mm in tissue. The ocular light power exposure was within the American National Standards Institute safety limit.<sup>9</sup>

The C-scan allows the visibility of arteries clearly distinguishable from veins by the presence of the *surrounding hypo-intense halo* due to the absence of efferent vessels directly out-coming from the walls.

The **superficial capillary plexus (SCP)** appears as a fine capillary network with an intense signal. The perfoveal arcade is well visible on 360°. (Figure 3 A, B, C).

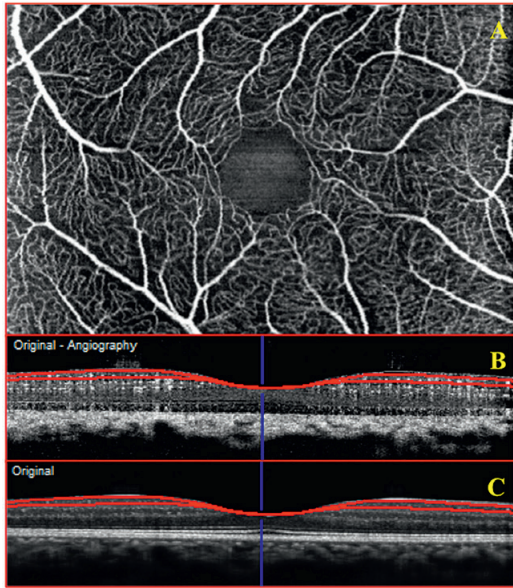


Figure 3: Automatically obtained OCT-A C-scan, which exactly outlines the Ganglion Cells Layer profile.

(A) **Superficial Capillary Plexus (SCP)**. Arteries are clearly distinguishable from veins by the presence of the surrounding hypo-intense halo due to the absence of efferent vessels directly out-coming from the walls. It is shown a fine capillary network, which corresponds to the superficial capillary plexus (SCP). The perfoveal arcade is well visible on 360°.

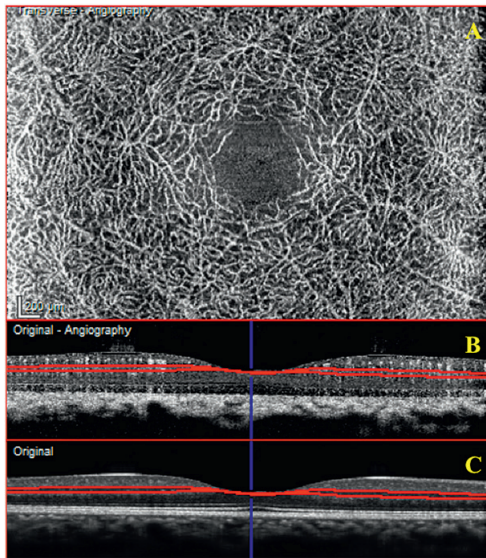
(B and C) **The corresponding B-scans** show regularly aligned hyper-intense dots stratified in two main lines (*deep and superficial*) and an intermediate one, corresponding to the interconnections between the two plexa. The Superficial Capillary Plexus is shown in the C-scan taken at the level of the ganglion cells layer [red line in figure 3B and 3C].

The **Deep Capillary Plexus** is shown in the C-scan taken at the level of the inner nuclear layer (INL) (Figure 4 A, B, C). A dense capillary network, different than the superficial one, becomes clearly visible and it develops all around the perifoveal area.

This is the **first in-vivo** examination that could allow a fine visualization of the deep capillary plexus (DCP).

It appears as a very dense, regularly anastomosed network, with sinuous arborization. Arterioles and venules are not distinctly visible.

The corresponding B-scans show regularly aligned hyper-intense dots stratified in two main lines (deep and superficial) and an intermediate one, corresponding to the interconnections between the two plexa. [red line in figure 4B and 4C].



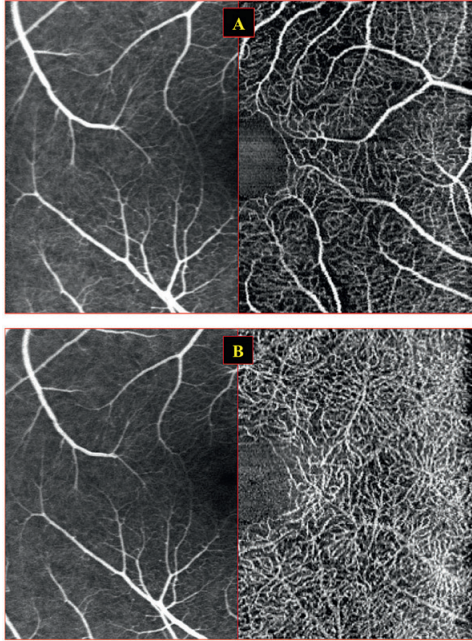
**Figure 4:**Automatically obtained OCT-A C-scan, shaped on the Inner Limiting Membrane (ILM) profile.

(A): *Deep Capillary Plexus, (DCP)*. Clearly distinguishable dense capillary network, developing all around the perifoveal area, which corresponds to the deep capillary plexus (DCP). This is the first in-vivo examination that could allow a fine visualization of the DCP.

(Band C) *The corresponding B-scans* show regularly aligned hyper-intense dots stratified in two main lines (deep and superficial) and an intermediate one, corresponding to the interconnections between the two plexa. The Superficial Capillary Plexus is shown in the C-scan taken at the level of the ganglion cells layer) [red line in figure 3B and 3C].

The conventional fluorescein angiography and the OCT-A cannot be perfectly compared. This is mainly due to the bi-dimensional (2D) aspect of the FA in which, all the vascular structures included in the whole retinal thickness are

simultaneously showed. Therefore this type of imaging suffers of some limitations due to the superimposition of different layers and light scattering.



**Figures 5A and 5B:** Comparison between fluorescein angiography (left) and OCT- angiography (right) in visualization of the *Superficial Capillary Plexus* (SCP, 5A) and the *Deep Capillary Plexus* (DCP, 5B).

The **OCT-angiography** (OCT-A), for the same nature of a depth-resolved examination, allows a clear visualization of different structures (as appreciable in figure 5 A and 5B), and makes the clinician able to evaluate layer by layer the entire retinal and choroidal tissues for a detailed vascular analysis, in a limited but useful area (in this case  $15 \times 10^\circ$ , Figure 5A and 5B).

A significant difference is evident between the traditional FA (on the left) and the OCT-A (on the right).

The FA image, does not allow to clearly distinguish the SCP (Figure 5A) nor the DCP (Figure 5B), while on OCT-A, the two plexa are well visible and distinct.

## CHOROIDAL VASCULAR ANATOMY

**Large part of the blood supply** of the eye comes from the choroid, which originates from the ophthalmic arteries. The left and right ophthalmic arteries, in the widest part of the individuals, arise as the first major branch of the internal carotid, usually where the latter breaks through the dura mater to exit the cavernous sinus.

**The posterior ciliary arteries**, which form the blood supply to the choroid, and the central retinal artery, which enters the eye via the optic nerve, are branches of the ophthalmic artery. Other branches of the ophthalmic artery supply the lacrymals gland, extra-ocular muscles, and lids.

**The choroid** is vascularized by two arterial systems: the short posterior ciliary arteries, which supply the posterior choroid and the long posterior ciliary arteries, which supply the anterior portion of the choroid (as well as the iris and ciliary body).

**Short posterior ciliary arteries** (approximately 16 – 20) penetrate the sclera in a circular pattern surrounding the optic nerve, with the distance between these vessels and the nasal side of the nerve being closer than that on the temporal side.

**The circle of Zinn**, an annular artery surrounding the optic nerve, is formed with the anastomoses of these arteries within the sclera. The branches from the circle of Zinn contribute to the pial circulation, the optic nerve at the level of the lamina cribrosa, and the nerve fiber layer of the optic disk.

**The short posterior ciliary** (other branches originating from the circle of Zinn) enter the choroid to provide the arterial blood supply to the posterior uvea. These arteries divide rapidly to terminate in the **choriocapillaris**, an exceptionally dense capillary bed that nourishes the posterior choroid up to the level of the equator of the eye.

**The two long posterior ciliary arteries** penetrate the sclera on either side of the optic nerve. The long posterior ciliary arteries begin to branch just anterior to the equator and contribute to the circulation of the iris and ciliary body.

Just anterior to the equator, some branches of these vessels course down into the choroid and branch to terminate in the choriocapillaris from the ora serrata back to the equator of the eye.

### Choriocapillaris layer

These arteries continue to branch and ultimately form the extensive choriocapillaris layer adjacent to the a-cellular Bruch's membrane located on the basal side of the RPE.

Their lumen diameter is nearly 20  $\mu\text{m}$  in the macular region and 18 – 50  $\mu\text{m}$  in the periphery.

### Venous vessels

Large draining vessels collect blood from the entire choroid (posterior to the equator). The drainage is generally toward 4 quadrants. But sometime some prevalence of one onto the others may be seen with large vessels in macular area

**Venous collecting vessels** from the choriocapillaris, emerge the eye through the vortex veins (generally present in number of 4 to 7). In addition to the choroid, the vortex veins also drain the ciliary body and iris circulation.

**The vortex veins** usually exit the sclera at the equator or up to 6 mm posterior to this location after forming an ampulla near the internal sclera.

The vortex veins drain into the superior and inferior ophthalmic veins, which leave the orbit and enter the cavernous sinus.

## INDOCYANINE GREEN ANGIOGRAPHY IN HEALTHY SUBJECTS

Indocyanine Green Angiography (ICGA) has dramatically advanced our understanding and interpretation of choroidal imaging in ophthalmology.

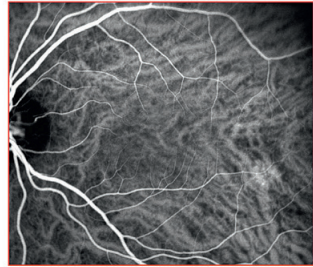
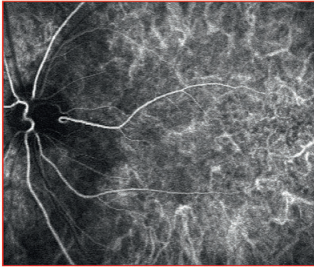
**Normal angiogram** is difficult to define because of the numerous changes that can occur with aging or that related to differences in pigmentation.

**Anatomical variants** are common in the arrangement and distribution of choroidal blood vessels, and of the circulatory dynamics: filling and drainage.

**Arteries may emerge** from different sites, usually peri macular and peripapillary, with variable intervals (**Figure 6**).

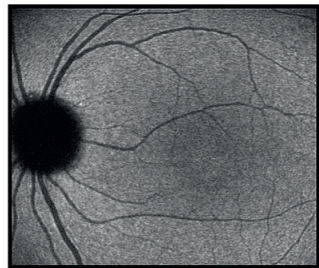
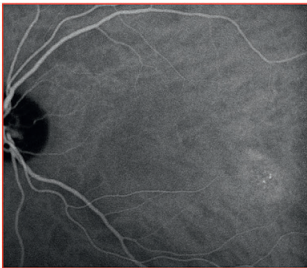**Veins show an unusual path** even more frequently, sometimes draining into posterior pole (**Figure 7,8**)

**However vascular branches** are usually no longer visible over their entire length due to the *undulating nature of their pathways*, the layered distribution and the variable caliber of vessels within choroidal tissue, therefore imaging them may require successive focusing.



**Figure 6: ICGA during arterial phase.** The dye is first seen in choroidal arteries with their initial distinctive loop and their oblique path towards the periphery. Note the simultaneous filling of a cilio-retinal artery.

**Figure 7: Early venous phase of ICGA without significant changes in large vessels choroidal network.** Clear predominance of the venous network, with difficultly distinguishable arterials pattern. Asymmetrical arrangement of venous drainage, which is mainly directed towards superior and inferior temporal periphery.



**Figure 8: Mid venous phase of ICGA.** The choroidal vessels are faintly visible

**Figure 8bis: Late phase of ICGA.** Inversion phase: the choroidal vessels are no more visible



## OCT-A OF THE CHOROID IN HEALTHY SUBJECTS

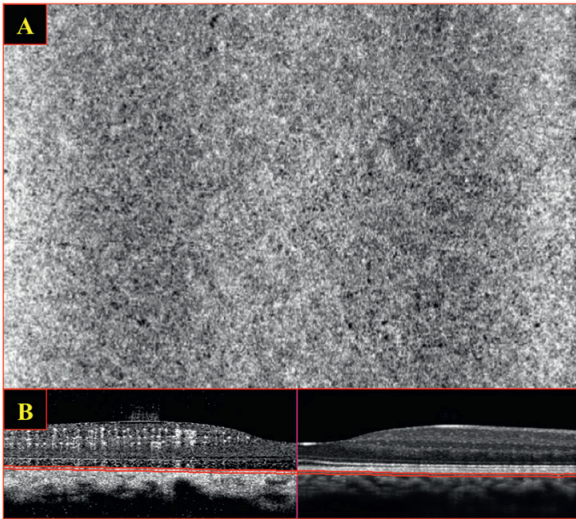
OCT-A, in addition to the depth-resolved information of retinal vessels, may provide further insight into choroidal flow.

The information given by segmenting different levels deeper than Bruch's Membrane are still limited and not fully understood.

## Choriocapillaris

Starting from the Bruch's membrane for a 20  $\mu\text{m}$  distance, toward the choroidal-scleral interface, different C-scans shaped on BM pro-

file show a relatively **homogenous grayish aspect**



**Figure 9A and 9B: Choriocapillaris (CC)** A 20- $\mu\text{m}$ -thickness OCT-A C-scan (9A), shaped on the Bruch's membrane (BM) profile. The C-scan is taken at 10  $\mu\text{m}$  below the BM [as shown in 9B]. Diffuse hyper-intense signal without a fine capillary network appreciable. Relatively homogenous grayish image that seems composed by a large number of tiny dots either hyper or hypo-intense. This pattern could correspond to the very richly anastomosed vascular layer of the choriocapillaris.

This aspect seems composed by a large number of tiny dots either hyper or hypo-intense. A few of them are moderately bigger. This homogenous pattern could correspond to the very

richly anastomosed vascular layer of the choriocapillaris.

No vascular channels are clearly detectable at this level (**Figure 9 A and 9B**)

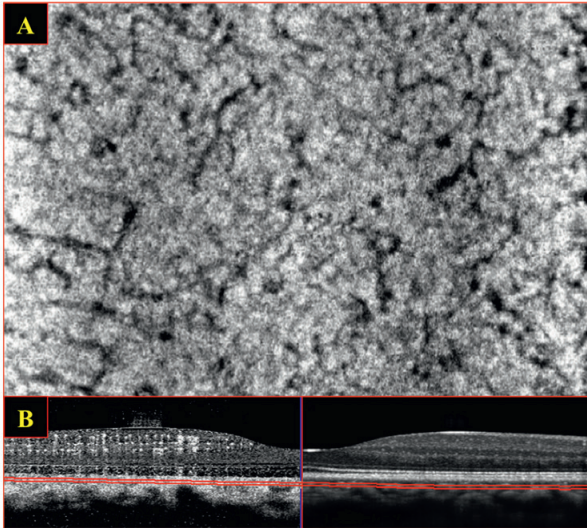
### Choroid (Sattler's Layer)

Different thin C-scans of 30  $\mu\text{m}$  thickness each, deeper than choriocapillaris, allow the analysis of the so-called **Sattler's layer** (medium choroidal vessels layer).

This layer is clearly visible on the Angio B-scan with quite continuous hyper intense signal, which is mixed with some hypo-intense structures.

The C-scan shows many hypo-intense, linear (black, tubular) entities resembling the medium vessels network in an almost continuous hyper-intense grayish background. (**Figure 10, A and B**)

The reason why we are not able to distinguish a fine hyper-intense vascular network, is the *attenuation* of its own signal induced by the structures above.



**Figure 10 A and 10B: Sattler's Layer (medium choroidal vessels).** 20- $\mu\text{m}$ -thickness OCT-A C-scan shaped on the Bruch's membrane (BM) profile. The C-scan is taken at 70  $\mu\text{m}$  below the BM [as shown in 10B]. The diffuse hyper-intense signal due to the choriocapillaris does not allow a clear visualization of medium choroidal vessels.

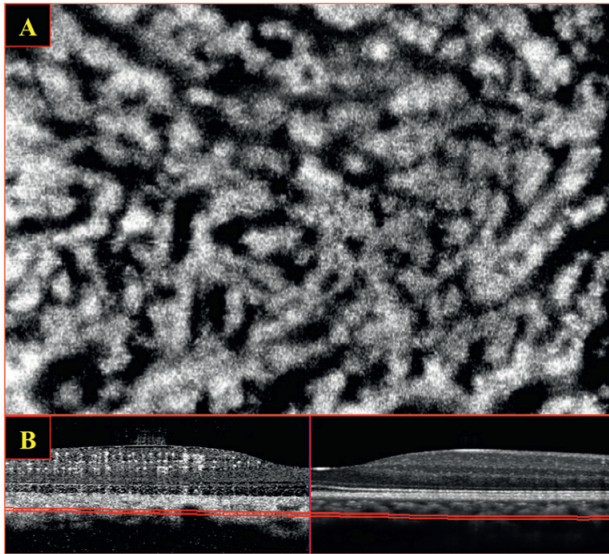
Several hypointense (black) linear structures on a greyish background are appreciable in this C-scan section, probably representing the choroidal vessels present at this level, partially masked by the hyper-intense signal diffusing from the choriocapillaris.

### Choroid (Haller's Layer)

Deeper again, the C-scan segmentation allows the visualization of large choroidal vessels (so called **Haller's layer**). The B-scan section shows alternative areas of hypo (black, tubular) and hyper intense (greyish, diffuse) signal corresponding to these vessels whose caliber is much more larger than the Sattler's layer (**Figure 11A and B**).

The C-scan shows that the signal in this layer is discontinuous with multiple interruptions.

Even in this case this aspect is due to the signal attenuation is due to the structures above (mainly choriocapillaris, but also Sattler's layer).



**Figure 11A and 11B: Haller's Layer (large choroidal vessels).** 20- $\mu$ m-thickness OCT-A C-scan shaped on the Bruch's membrane (BM) profile. The C-scan is taken at 140  $\mu$ m below the BM [as shown in 11B]. Numerous hypo-intense linear structures (black, tubular) are evident on a greyish background.

This is related to the presence of large choroidal vessels at this level. As it was for the Sattler's layer, the decorrelation signal coming from these vessels is masked by influence of the structures above (mainly choriocapillaris, but also Sattler's layer)

## REFERENCES

- 1. Sulzbacher F, Kiss C, Munk M, et al.** Diagnostic evaluation of type 2 (classic) choroidal neovascularization: optical coherence tomography, indocyanine green angiography, and fluorescein angiography. *Am J Ophthalmol* 2011; 152(5): 799-806 *et al.*
- 2. Snodderly DM, Weinhaus RS, Choi JC.** Neural-vascular relationships in central retina of macaque monkeys (*Macaca fascicularis*). *J Neurosci*. 1992; 12 (4): 1169-1193.
- 3. Weinhaus RS, Burke JM, Delori FC, Snodderly DM.** Comparison of fluorescein angiography with microvascular anatomy of macaque retina. *Exp Eye Res*. 1995; 61 (1): 1-16.
- 4. Mendis KR, Balaratnasingam C, Yu P, et al.** Correlation of histologic and clinical images to determine the diagnostic value of fluorescein angiography for studying capillary detail. *Invest Ophthalmol Vis Sci*. 2010; 51 (11): 5864-5859.
- 5. Spaide RF, Klancnik JM Jr, Cooney MJ.** Retinal vascular layers imaged by fluorescein angiography and optical coherence tomography angiography. *JAMA Ophthalmol*. 2015 Jan 1; 133 (1): 45-50.
- 6. Moulton E, Choi W, Waheed NK, et al.** Ultrahigh-speed swept-source OCT angiography in exudative AMD. *Ophthalmic Surg Lasers Imaging Retina*. 2014 Nov-Dec; 45 (6): 496-505.
- 7. Jia Y, Bailey ST, Wilson DJ, et al.** Quantitative optical coherence tomography angiography of choroidal neovascularization in age-related macular degeneration. *Ophthalmology* 2014; 121 (7): 1435-44.
- 8. Yannuzzi LA, Rohrer KT, Tindel LJ, et al.** Fluorescein angiography complication survey. *Ophthalmology*. 1986 May; 93(5): 611-7.
- 9. American National Standard for Safe Use of Lasers, ANSI Z136.** Orlando, FL: Laser Institute of America; 2007:1–2007.

**CHAPTER VIII**

**SPECTRALIS OCT-ANGIOGRAPHY**

**IN**

**DIABETIC PATIENTS:**

**SUPERFICIAL AND DEEP**

**CAPILLARY PLEXUSES**



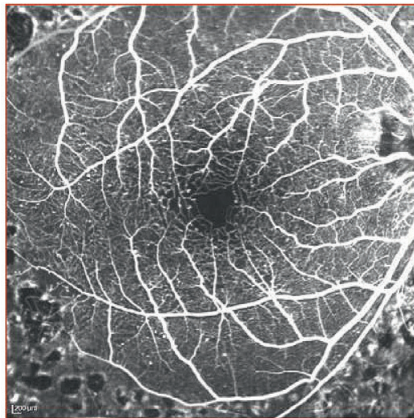
## SPECTRALIS OCT-ANGIOGRAPHY IN SUPERFICIAL AND DEEP CAPILLARY PLEXUSES

**Optical Coherence Tomography Angiography (OCT-A)** is a new, non-invasive, dye-less imaging modality, which can visualize moving blood cells within retinal vessels.

Several studies of retinal vasculature have relied on fluorescein angiography to provide important details about the retinal microvasculature.

Fluorescein angiography is an invasive two-dimensional examination that cannot adequately resolve the deeper retinal networks.

The major advantage of OCT-A is the capability to resolve the vascular layers of the retina with a tri-dimensional (3D) approach.



**Figure 1: Fluorescein angiography of Diabetic Maculopathy**

The early venous phase of fluorescein angiography is useful to highlight retinal vascular impairment due to diabetic retinopathy.

It is clearly shown the foveal avascular zone, partially associated with an evident disruption of the peri-foveal capillary arcade.

Tiny non-perfused areas and micro aneurysms are also visible. The *superficial capillary plexus* may be evaluated, but *the deep one* is not distinguishable due to light scattering.

Most of the in-built software of the different OCT-A devices have distinguished the retinal vasculature into two plexuses:

- a *superficial capillary plexus (SCP)* and
- a *deep capillary plexus (DCP)*.

However, there are some studies in which it is reported the evidence of a third capillary plexus,

- the *middle capillary plexus (MCP)*,

which is generally not revealed in current OCT-A segmentation approach, that incorporates the MCP into either the SCP or DCP angiograms.<sup>1</sup>

The inner component of the DCP has been often termed *intermediate capillary plexus*.

A recent article demonstrated the importance of the inner component of the DCP. But, at the same time sentenced how it is actually impossible to separate the intermediate from the deep capillary plexus using presently available OCT-A technology.<sup>2</sup>

**In diabetic maculopathy**, macular ischaemia and enlargement of the FAZ can differentially affect the SCP and the DCP.<sup>3</sup>

**Moreover, disorganization** of the retinal inner layers<sup>4</sup> and para-central acute middle maculopathy (PAMM),<sup>2</sup> commonly occur in diabetic retinopathy.

They are likely manifestations of ischaemia at the level of the SCP and DCP, respectively.

**Capillary non-perfusion** can be associated also with photoreceptor and outer retinal disruption on OCT, which could be a specific manifestation of deep ischaemia at the DCP.<sup>5</sup>

**Micro aneurysms** are generally visible as roundish or fusiform focal vessel's dilations.

In some cases, due to the inconstant and non-laminar blood flow inside these structures, they might result not appreciable on OCT-A.

It has been demonstrated that the capability of OCT-A to detect micro aneurysms is substantially inferior to FA.<sup>3</sup>

**Aim of this chapter** is to show *different degrees* of macular involvement in case of diabetic retinopathy and how a *depth-resolved analysis* is a useful tool to determine the SCP and DCP impairment.



## SUPERFICIAL AND DEEP CAPILLARY PLEXUSES IN DIABETIC PATIENTS

### 1. Without biomicroscopic signs of diabetic maculopathy

Diabetic retinopathy (DR) is the leading cause of blindness in working-age individuals in the developed world, affecting approximately 75% of patients with diabetes mellitus after 15 years.

One of the **early changes in diabetic eyes** is loss of pericytes and proliferation of endothelial cells leading to the development of microaneurysms. Pericytes loss impairs the blood-retinal barrier, thereby leading to venous dilation and beading.

**The gold standard to screen for DR** is dilated biomicroscopic fundus examination, where microaneurysms in the posterior pole are typically the first sign on ophthalmoscopy.

Although **fluorescein angiography** is more sensitive than examination to detect early DR, it is invasive, and time consuming, and therefore, is not appropriate as a screening test for DR.

**Optical coherence tomography angiography** (OCT-A) is a fast, noninvasive imaging technique that uses motion contrast to create OCT-Angiograms by comparing the decorrelation signal among sequential OCT B-scans.

In a recent study, De Carlo et al.<sup>7</sup> demonstrated that the **Foveal Avascular Zone** was increased in diabetic eyes compared with control eyes. Remodeling of the FAZ was also more prevalent in diabetic eyes. Additionally, areas of capillary non-perfusion were noted more commonly in diabetic eyes.

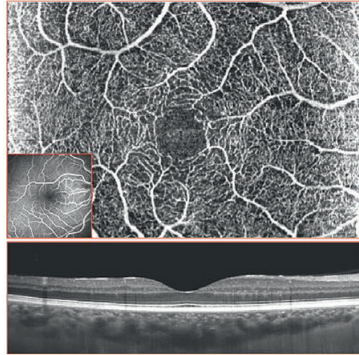
Although 21% of diabetic eyes demonstrated vascular tortuosity, this micro-vascular abnormality was noted in 25% of control eyes as well, suggesting that some degree of vascular tortuosity may be a variant of normal and will probably not be useful as an OCTA-screening parameter for diabetic retinal vascular changes.

OCT-A was able to **detect micro-vascular changes** in diabetic eyes *before* visualization on clinical examination.

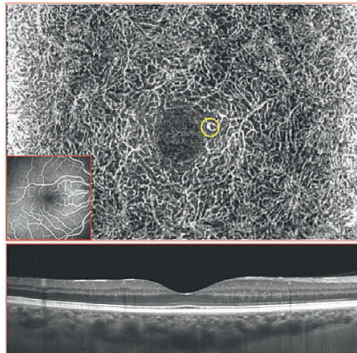
Remodeling and enlargement of the FAZ and areas of capillary non-perfusion were commonly noted in these eyes even before microaneurysms, which are currently believed to be the first clinical sign of DR.

**Optical coherence tomography angiography** may be a valuable screening tool for DR, useful as a clinical trial endpoint, and efficient in guiding early treatment decisions in the future.

**"CLINICAL CASES OF DIFFERENT DEGREES OF MACULAR INVOLVEMENT"**  
**CASE N° 1 : No evidence of macular impairment**

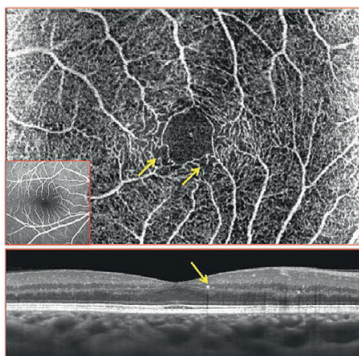


**Figure 2: CASE I – Superficial Capillary Plexus (SCP) on OCT-A, diabetic patient, without biomicroscopic signs of diabetic maculopathy : No evidence of macular impairment.**  
The SCP and the perifoveal vascular arcade appear well defined.  
No areas of non-perfusion, nor focal dilations (micro aneurysms) are clearly visible.  
The extension of the Foveal Avascular Zone is within the normal range.  
No evidence of macular impairment is appreciable on structural OCT (*bottom image*).



**Figure 3: CASE I – Deep Capillary Plexus (DCP) on OCT-A of a diabetic patient, without biomicroscopic signs of diabetic maculopathy**  
The DCP seems to be well perfused in the entire scanned area.  
No areas without decorrelation signal are visible.  
One focal vessel dilation (*yellow circle*), probably due to a micro aneurysm, is detectable.  
The Foveal Avascular Zone is within the normal range.

**CASE N° II : Few perifoveal areas of nonperfusion**

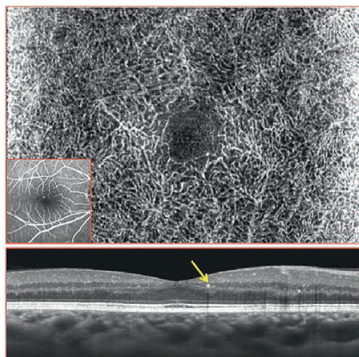


**Figure 4: CASE II – Superficial Capillary Plexus (SCP) on OCT-A (diabetic patient, without biomicroscopic signs of diabetic maculopathy: few perifoveal areas of non-perfusion)**

The SCP and the perifoveal vascular arcade appear well defined.

A few perifoveal areas of non-perfusion (yellow arrows) are visible: in these areas the vascular network seems rarefied. The extension of the Foveal Avascular Zone is within the normal range.

Focal hyperreflective dots are visible on structural OCT (bottom image) probably due to intraretinal exudation (hard exudates; yellow arrow).



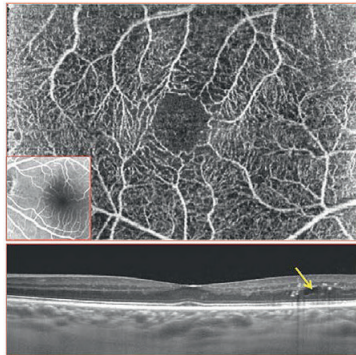
**Figure 5: CASE II – Deep Capillary Plexus (DCP) on OCT-A (diabetic patient, without biomicroscopic signs of diabetic maculopathy).**

The DCP seems to be well perfused in the entire scanned area.

No areas without clear decorrelation signal are visible. No focal vessel dilation are detectable.

The Foveal Avascular Zone is within the normal range. Focal hyper reflective dots are visible on structural OCT (bottom image) probably due to intraretinal exudation (hard exudates; yellow arrow).

**CASE N° III : Focal hyper-reflective dots and cystoid spaces.**

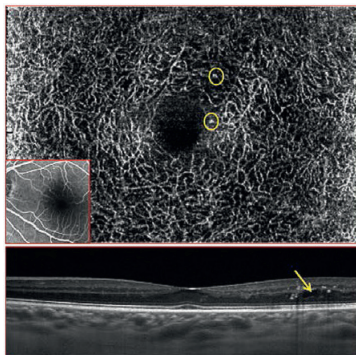


**Figure 6: CASE III – Superficial Capillary Plexus (SCP) on OCT-A (diabetic patient without biomicroscopic signs of diabetic maculopathy)**

The SCP and the perifoveal vascular arcade appear well defined. No areas of non-perfusion, nor focal dilations (micro aneurysms) are clearly visible.

The extension of the Foveal Avascular Zone is within the normal range.

Focal hyper-reflective dots and cystoid spaces are visible in extra-foveal area on structural OCT (*bottom image*) probably due to intraretinal exudation (*yellow arrow*).



**Figure 7: CASE III – Deep Capillary Plexus (DCP) on OCT-A**

**(diabetic patient without biomicroscopic signs of diabetic maculopathy).** A few focal vessel dilations are detectable

The DCP seems to be well perfused in the entire scanned area. No areas without clear decorrelation signal are visible.

A few focal vessel dilations are detectable (*yellow rings*). The Foveal Avascular Zone is within the normal range.

Focal hyperreflective dots and cystoid spaces are visible in extra-foveal area on structural OCT (*bottom image*) probably due to intraretinal exudation (*yellow arrow*).

### Mild non-proliferative diabetic maculopath.

## SUPERFICIAL AND DEEP CAPILLARY PLEXUSES IN DIABETIC PATIENTS WITH

### 2. Mild non-proliferative diabetic maculopath.

Mild non-proliferative diabetic retinopathy is a pathological condition that is mainly characterized by the presence of micro aneurysms (**Figure 8**).

**OCT-Angiography** may allow to identify some sub clinical retinal lesions, such as non-perfused areas, that can be hidden on biomicroscopic examinations of the eye fundus.

**The superficial capillary plexus (SCP)** and the perifoveal vascular arcade may appear rarefied and discontinuous. (**Figures 8, 10, 12**)

**A few macular areas of non-perfusion**, of variable size, both at the level of the superficial and deep capillary plexus (DCP), can be visible.

In these areas, the decorrelation signal coming from the vascular network is less intense or absent.

**Micro aneurysms**, which are the typical lesion of mild non-proliferative diabetic retinopathy, are appreciable on OCT-Angiography as roundish or fusiform decorrelated structures.

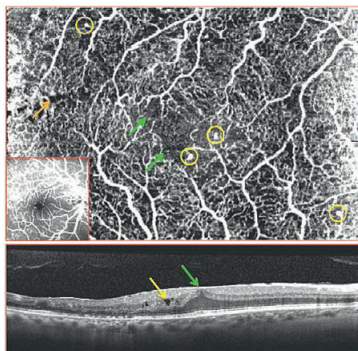
As already described, not all the micro aneurysms are visible on OCT-A.<sup>4</sup>

This phenomenon is mainly due to the slow, non-laminar blood flow that is present inside the same lesion.

**Tiny cystoid spaces** are also sometimes shown as hypo-intense roundish, black areas (**Figures 8 and 9**).

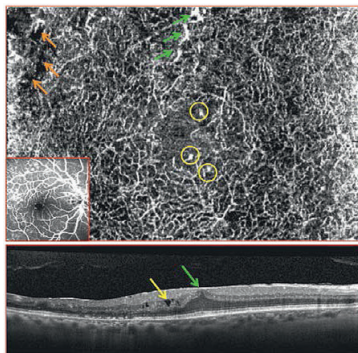
They have a different distribution from the superficial to the deep capillary plexuses.

**CASE N° IV : A few perfoveal areas of non-perfusion**



**Figure 8: CASE IV – Superficial Capillary Plexus (SCP) on OCT-A (diabetic patient, with mild nonproliferative diabetic maculopathy):** A few perfoveal areas of non-perfusion. The SCP and the perfoveal vascular arcade appear mildly rarefied.

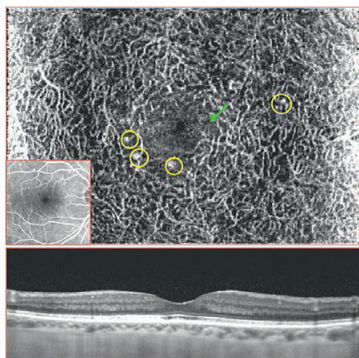
A few perfoveal areas of non-perfusion (*green arrows*) are visible: in these areas the vascular network seems rarefied. Microaneurysms (*yellow circles*) and tiny cystoid spaces (*orange arrow*) are also appreciable. Cystoid spaces (*yellow arrow*) are visible on structural OCT (bottom image) due to intraretinal exudation. A fine epiretinal membrane (*green arrow*) is also shown.



**Figure 9: CASE IV – Deep Capillary Plexus (DCP) on OCT-A (diabetic patient, with mild nonproliferative diabetic maculopathy) :** Small cystoid spaces. The DCP seems substantially well perfused in the entire scanned area.

No areas without clear decorrelation signal are visible. A few focal vessel dilations (*green arrows*) and microaneurysms (*yellow rings*) are detectable. Small cystoid spaces (*orange arrows*) are present at the border of the scanned area. Cystoid spaces (*yellow arrow*) are visible on structural OCT (bottom image) due to intraretinal exudation. A fine epiretinal membrane (*green arrow*) is also shown.

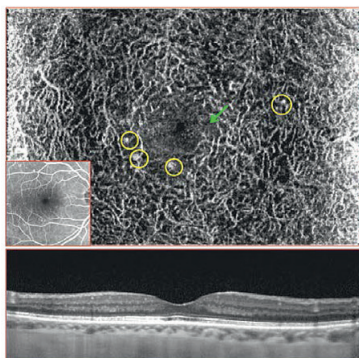
**CASE N° V : A few perifoveal areas of non-perfusion.**



**Figure 10: CASE V – Superficial Capillary Plexus (SCP) on OCT-A (diabetic patient with mild non-proliferative diabetic maculopathy) :** A few areas of non-perfusion. The SCP and the perifoveal vascular arcade appear well defined.

A few areas of non-perfusion (*green arrows*) are visible: in these areas the vascular network seems rarefied. One micro aneurysm (*yellow circles*) is also appreciable.

No evidence of macular impairment is shown on structural OCT (*bottom image*).

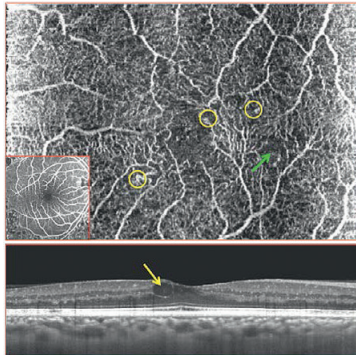


**Figure 11: CASE V – Deep Capillary Plexus (DCP) on OCT-A (diabetic patient with mild non-proliferative diabetic maculopathy) :** enlargement of the foveal avascular zone. The DCP appears mildly rarefied, mainly in perifoveal area, showing an enlargement of the foveal avascular zone (*green arrow*).

Several micro aneurysms (*yellow rings*) are detectable.

No evidence of macular impairment is shown on structural OCT (*bottom image*).

**CASE N° VI : A few micro aneurysms.**

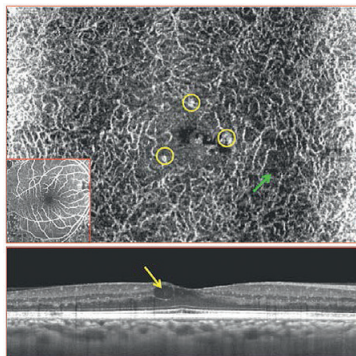


**Figure 12: CASE VI – Superficial Capillary Plexus (SCP) on OCT-A (diabetic patient with mild non-proliferative diabetic maculopathy).** A few micro aneurysms

The SCP appears slightly rarefied around the foveal avascular zone.

A few micro aneurysms (*yellow circles*) and small non-perfused areas are visible (*green arrow*).

Cystoid spaces (*yellow arrow*) are visible on structural OCT (*bottom image*) due to intraretinal exudation



**Figure 13: CASE VI – Deep Capillary Plexus (DCP) on OCT-A (diabetic patient with mild non-proliferative diabetic maculopathy).**

A few areas without clear decorrelation signal are visible (*green arrow*).

Microaneurysms (*yellow rings*) are detectable in perifoveal area.

Cystoid spaces (*yellow arrow*) are visible on structural OCT (*bottom image*) due to intraretinal exudation.



### SUPERFICIAL AND DEEP CAPILLARY PLEXUSES IN DIABETIC PATIENTS WITH: 3. Severe non-proliferative diabetic maculopathy

**Severe, non-proliferative diabetic retinopathy** is a pathological condition characterized by:

The presence of more than 20 intraretinal hemorrhages in each of the four quadrants, definite venous beading in two quadrants, prominent intra-retinal micro-vascular abnormalities in one quadrant and no signs of proliferative retinopathy. (Figures 14 and 15).

**Intraretinal hemorrhages** may block or attenuate the signal coming from decorrelated structures resulting therefore in a sort of *masquerading process* onto perfused vessels.

**The venous beading** is clearly visible on OCT-A as contiguous focal dilations of retinal vessels. In some cases the blood flow may substantially vary when venous beading occur, causing the partial visualization of vascular dilations, since they're not homogeneously perfused.

**Intra-retinal micro-vascular abnormalities (IRMA)** (Figure 15 and 21) are highly decorrelated vascular complexes characterized by

the presence of focal or diffuse dilations, completely disrupted vascular architecture, in proximity to non-perfused areas.

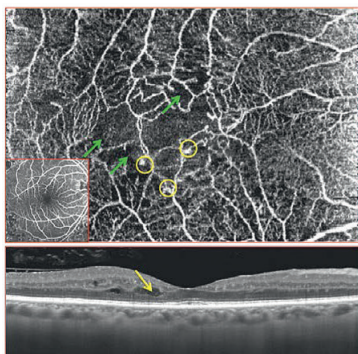
They may extend from the inner to the outer retinal vascular layers, and sometimes exceed the borders of the inner nuclear layer, as true intraretinal neo vascularization.

All these features may be clearly identified on **OCT-Angiography**, which can also highlight the presence of non-perfused areas at different levels of depth.

These **non-perfused areas** can be of different size and may involve both the superficial or deep vascular layers (Figures 14 to 21).

A careful analysis of the macular pathological features in case of severe non-proliferative diabetic retinopathy could reveal the very **initial signs of a proliferative retinopathy** and therefore to a prompt treatment.

**CASE N° VII : Non-perfusion areas**



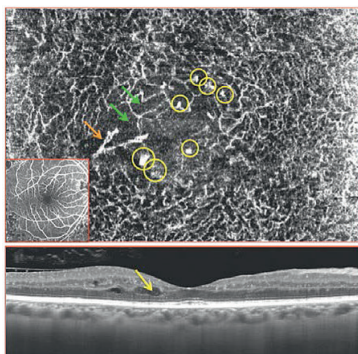
**Figure 14: CASE VII – Superficial Capillary Plexus (SCP) on OCT-A (diabetic patient with severe non-proliferative diabetic maculopathy).** Non-perfusion areas (*green arrows*) are visible

The SCP and the perifoveal vascular arcade are severely impaired.

Non-perfusion areas (*green arrows*) are visible: in these areas the vascular network is not detectable.

Micro-aneurysms (*yellow circles*) and vessel's dilations are also appreciable.

Cystoid spaces (*yellow arrow*) are visible on structural OCT (*bottom image*) due to intraretinal exudation.

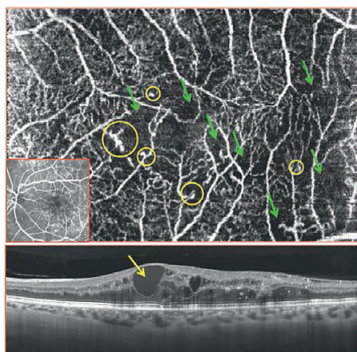


**Figure 15: CASE VII – Deep Capillary Plexus (DCP) on OCT-A (diabetic patient with severe non-proliferative diabetic maculopathy).** An evident enlargement of the foveal avascular zone

An evident enlargement of the foveal avascular zone is visible at the level of the DCP. Numerous areas without clear decorrelation signal are visible (*green arrows*). A few focal vessel dilations (*orange arrows*) probably due to intraretinal micro-vascular abnormalities (IRMA) and micro-aneurysms (*yellow rings*) are detectable.

Cystoid spaces (*yellow arrow*) are visible on structural OCT (*bottom image*) due to intraretinal exudation.

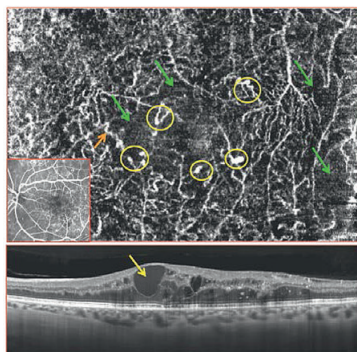
**CASE N° VIII : Large, confluent areas of non-perfusion.**



**Figure 16: CASE VIII – Superficial Capillary Plexus (SCP) on OCT-A (diabetic patient with severe non-proliferative diabetic maculopathy).** Large, confluent areas of non-perfusion

Large, confluent areas of non-perfusion (*green arrows*) are visible: in these areas the superficial capillary plexus seems rarefied. Isolated or clusters of micro-aneurysms (*yellow circles*) are shown: these lesions are mainly located at the borders of non-perfused areas.

Cystoid spaces (*yellow arrow*) are visible on structural OCT (*bottom image*) due to intraretinal exudation.



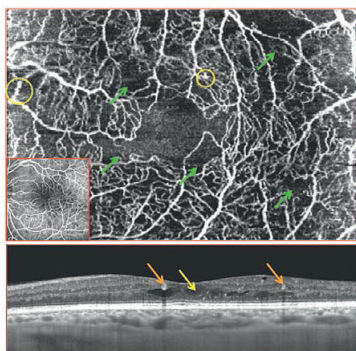
**Figure 17: CASE VIII – Deep Capillary Plexus (DCP) on OCT-A (diabetic patient with severe non-proliferative diabetic maculopathy).** The DCP is clearly rarefied in the entire scanned area.

Several areas without clear decorrelation signal are visible.

Focal vessel dilations (*orange arrow*) and micro-aneurysms (*yellow rings*), generally located at the edges of non-perfused areas are detectable.

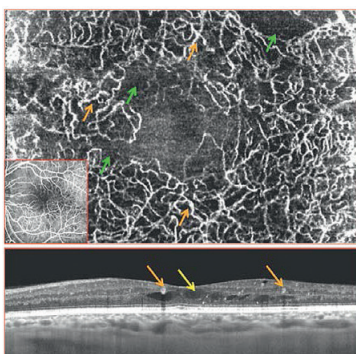
Cystoid spaces (*yellow arrow*) are visible on structural OCT (*bottom image*) due to intraretinal exudation.

**CASE N° IX : Perifoveal vascular arcade disruption.**



**Figure 18: CASE IX – Superficial Capillary Plexus (SCP) on OCT-A (diabetic patient with severe non-proliferative diabetic maculopathy).** *The perifoveal vascular arcade is disrupted.*

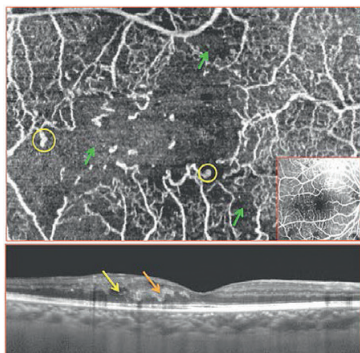
The perifoveal vascular arcade is disrupted with a clear enlargement of the foveal avascular zone. Numerous areas of non-perfusion (*green arrows*) are visible: in these areas the vascular network seems rarefied. Micro-aneurysms (*yellow circles*) are also appreciable. Cystoid spaces (*yellow arrow*) and microaneurysms (hyperreflective intraretinal roundish lesions at the level of the inner nuclear layer; *orange arrows*) are visible on structural OCT (*bottom image*).



**Figure 19: CASE IX – Deep Capillary Plexus (DCP) on OCT-A (diabetic patient with severe non-proliferative diabetic maculopathy).** *Evident enlargement of the foveal avascular zone.*

Large areas without clear decorrelation signal are visible: these are probably due to capillary dropout, determining also an evident enlargement of the foveal avascular zone. Several focal vessel dilations (*orange arrows*) are shown mainly at the edges of non-perfused areas. Cystoid spaces (*yellow arrow*) and microaneurysms (hyperreflective intraretinal roundish lesions at the level of the inner nuclear layer; *orange arrows*) are visible on structural OCT (*bottom image*).

**CASE N° X : extensive area of non-perfusion.**

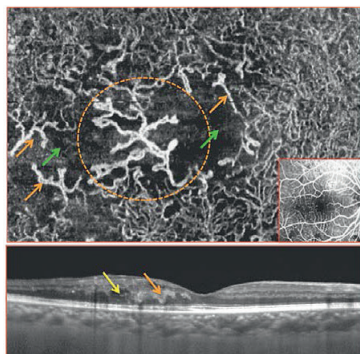


**Figure 20: CASE X – Superficial Capillary Plexus (SCP) on OCT-A**

**(diabetic patient with severe non-proliferative diabetic maculopathy).** Extensive area of non-perfusion. An extensive area of non-perfusion involves the central part of the figure (*green arrows*), including the foveal avascular zone.

In this area vessels are dilated and micro-aneurysms (*yellow circles*) are also visible.

Cystoid spaces (*yellow arrow*) and IRMA (hyper reflective intraretinal lesions involving the inner and outer retinal layers; *orange arrow*) are visible on structural OCT (*bottom image*).



**Figure 21: CASE X – Deep Capillary Plexus (DCP) on OCT-A**

**(diabetic patient with severe non-proliferative diabetic maculopathy).** Large central area of capillary dropout.

The large central area of capillary dropout (*green arrows*) shows the presence of a large intraretinal hyper-intense structure (*orange dashed line*), which is referred to the presence of an intraretinal micro vascular abnormality (IRMA).

Several focally dilated capillaries (*orange arrows*) are also appreciable at the borders of the non-perfused area.

## REFERENCES

- 1. Park JJ, Soetikno BT, Fawzi AA.** Characterization Of The Middle Capillary Plexus Using Optical Coherence Tomography Angiography In Healthy And Diabetic Eyes *Retina*. 2016. 0:1–12.
- 2. Nemiroff J, Kuehlewein L, Rahimy E, et al.** Assessing Deep Retinal Capillary Ischemia in Para-central Acute Middle Maculopathy by Optical Coherence Tomography Angiography. *Am J Ophthalmol*. 2016 Feb;162:121-132.)
- 3. Yu PK, Balaratnasingam C, Cringle SJ, McAllister IL, Provis J, Yu DY.** Microstructure and network organization of the microvasculature in the human macula. *Invest Ophthalmol Vis Sci*. 2010;51(12): 6735-6743.
- 4. Ishibazawa A, Nagaoka T, Takahashi A, et al.** Optical coherence tomography angiography in diabetic retinopathy: a prospective Pilot study. *Am J Ophthalmol* 2015;160:35–44.
- 5. Sun JK, Lin MM, Lammer J, et al.** Disorganization of the retinal inner layers as a predictor of visual acuity in eyes with center-involved diabetic macular edema. *JAMA Ophthalmol* 2014;132:1309–1316.
- 6. Scarinci F, Nesper PL, Fawzi AA.** Deep Retinal Capillary Non-perfusion is Associated with Photoreceptor Disruption in Diabetic Macular Ischemia, *American Journal of Ophthalmology* (2016), doi: 10.1016/j.ajo.2016.05.002.

**CHAPTER IX**

**SPECTRALIS OCT-ANGIOGRAPHY**

**IN**

**DIABETIC PATIENTS:**

**CHORIOCAPILLARIS AND**

**CHOROID**





## SPECTRALIS OCT-ANGIOGRAPHY IN DIABETIC MACULOPATHY:

### A TRUE CHORIOCAPILLARIS INVOLVEMENT

The **high oxygen demand** of the retina is supplied by two different vascular layers.

The *inner retinal layers* are exclusively nourished by the retinal circulation, while the *outer retinal ones*, which are completely avascular, obtain their oxygen supply mainly via diffusion from the choroidal tissue and only minimally from the retinal circulation.<sup>1,2</sup>

The **choroid** provides oxygen and nutrients to the outer third of the retina and consists of the following three vascular layers: the *choriocapillaris layer*, the choroidal layer composed of medium-sized vessels (*Sattler's layer*), and the large-vessel choroidal layer (*Haller's layer*).<sup>3-5</sup>

Given that the choroid is involved in many diseases of the posterior segment, an analysis of changes in its morphological features and vas-

culature in chorioretinal diseases may be of clinical relevance.

It has already been shown the presence of choroidal angiopathy in diabetic retinopathy<sup>6-7</sup>, both from a histological and tomographic point of view. With this study, the Authors aim to characterize **the functional features of the choriocapillaris** in patients with diabetic maculopathy by using OCT-Angiography.

Kohner et al.<sup>8</sup> suggested that the most important pathology in diabetic retinopathy is *capillary closure*, resulting in non-perfusion of retinal capillaries. Hidayat et al.<sup>5</sup> reported pathology in the choroid of patients with diabetes, which included *capillary drop-out*, luminal narrowing of capillaries and choroidal neovascularization with subretinal fibro-vascular membranes.

### Optical coherence tomography (OCT)

**Optical coherence tomography (OCT)** is clinically useful in monitoring disease progression in diabetic retinopathy.

It allows non-invasive visualization and evaluation of the choroid, retinal pigment epithelium, retinal layers and vitreous cavity.<sup>9</sup>

**Enhanced depth imaging (EDI)-OCT scans** are shown to produce higher resolution images with increased depth of penetration, hence

allowing quantitative assessment of the choroid.

This has led to significant research on *choroidal thickness*, in different disease conditions including diabetic maculopathy.

Many recent studies focus on using **choroidal thickness** as an indicator of choroidal blood flow.

However, reports on choroidal thickness in DM have been *contradictory*. This may be because choroidal thickness can be affected by various variables, thus leading to possible pitfalls.

Hence, the *need to explore the use of OCT-Angiography (OCT-A)* as a marker for the assessment of choroidal health.

**Clinical and experimental findings** suggest that choroidal vasculopathy in diabetes may play a role in the pathogenesis of diabetic retinopathy.

Various choroidal abnormalities, including obstruction of the choriocapillaris, vascular degeneration, choroidal aneurysms, and choroidal neovascularization, have been reported in histopathologic studies of diabetic eye.<sup>6,10</sup>

Esmacelpour et al<sup>11</sup> reported central choroid thinning in all Type 2 diabetic eyes regardless of disease stage. In this sixty-three eyes study,

the choroidal thickness mapping of all diabetic patients demonstrated *central and inferior thinning* compared with healthy eyes (unpaired t-test;  $P = 0.001$ ).

Subfoveal choroidal thickness for healthy eyes was  $327 \pm 74 \mu\text{m}$ , which was found to be significantly thicker than all diabetic eyes:

- eyes with micro aneurysm:  $208 \pm 49 \mu\text{m}$
- eyes with exudates:  $205 \pm 54 \mu\text{m}$
- eyes with CSME:  $211 \pm 76 \mu\text{m}$ .

It can be speculated that the thinner choroid indicates an *overall reduction of choroidal blood flow* in diabetic patients, as was previously demonstrated with laser Doppler flowmetry and ICG angiography.<sup>11,12</sup>

Therefore, it is likely that the **decreased choroidal thickness** may be related to retinal tissue hypoxia because the choroid is the major source of nutrition for the RPE and outer retinal layers.

## OCT-Angiography: Choroidal Assessment

**OCT-Angiography** is a useful tool to evaluate retinal blood flow. But the information about medium and large choroidal vessels on OCT-A remain substantially limited.

This is due to the wavelength of the spectral domain OCT devices (around 850 nm), to the hyper-reflectivity of the retinal pigment epithelium (RPE) and to the hyper-intense decorrelation signal coming from the choriocapillaris, which is related to **the high flow**.

As a consequence, *medium and large choroidal vessels are not visible as perfused (hyper-intense) structures*, with the current technology, except in case of RPE-choriocapillaris impairment (or atrophy).

Diabetic signs of choroidal vascular impairment are therefore evaluated principally at the level of the **choriocapillaris**, since it is the unique structure clearly defined on OCT-A.

## CHORIOCAPILLARIS INVOLVEMENT

### 1. In mild non-proliferative diabetic retinopathy

**Mild, non-proliferative diabetic retinopathy** is a pathological condition that is mainly characterized by the presence of **micro aneurysms**.

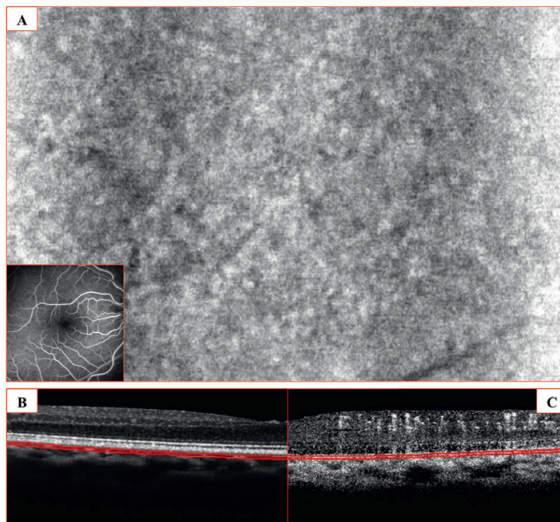
OCT-Angiography may allow to identify some sub clinical retinal lesions, such as non-perfused areas, that can be hidden on biomicroscopic examinations of the eye fundus.

At the level of the choriocapillaris, some abnormalities of blood flow might be related to an impaired circulation that, as in retinal capillar-

ies, might induce a **focal non-perfusion**.

On the C-scan OCT-Angiogram, the choriocapillaris may appear slightly rarefied in macular area (**Figure 1, A**). A few areas of "**flow void**" could be visible, probably due to small non-perfused areas.

This process could result in a **direct damage** of the outer retinal layers and photoreceptors, which obtain the oxygen supply and nourishments from choriocapillaris circulation.



**Figure 1: CASE I – Choriocapillaris on OCT-A (Patient with mild non-proliferative diabetic maculopathy)**  
A- C-scan OCT-Angiogram (20- $\mu$ m-thick): The Choriocapillaris appears minimally or non-rarefied in macular region No areas of flow void are clearly distinguishable.  
B-The cross sectional structural OCT, and  
C-The corresponding OCT-angiogram clearly shows the level of the C-scan above (A), which is taken immediately beneath the Bruch's membrane (red lines).

## CHORIOCAPILLARIS INVOLVEMENT

### 2. In severe non-proliferative diabetic retinopathy

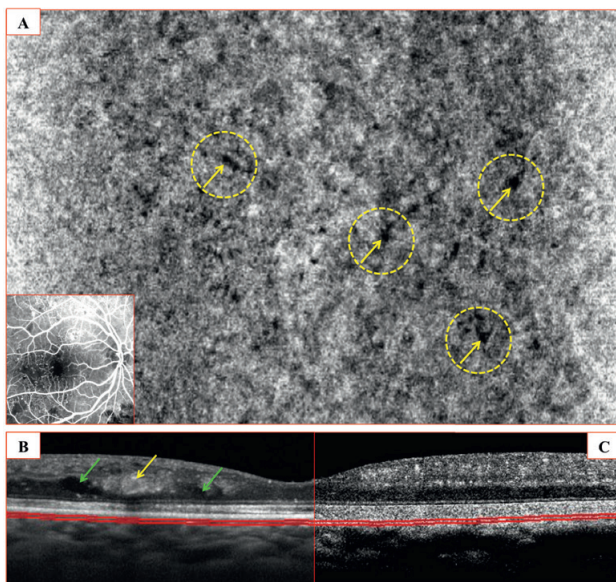
**Severe, non-proliferative diabetic retinopathy** is a pathological condition characterized by:

- more than 20 intraretinal hemorrhages in each of the four quadrants,
- definite venous beading in two quadrants,
- prominent intra-retinal micro-vascular abnormalities in one quadrant and
- no signs of proliferative retinopathy.

*All these features may be clearly identified on*

OCT-Angiography, which can also highlight the presence of non-perfused areas at different levels of depth.

The careful analysis at the level of the choriocapillaris, can reveal **focal flow voids**, which might be referred to an impaired perfusion secondary to diabetic micro-angiopathy. (**Figure 2**)



**Figure 2: CASE II – Choriocapillaris on OCT-A (Patient with severe non-proliferative diabetic maculopathy)**

A- C-scan OCT-Angiogram (20- $\mu$ m-thick): The Choriocapillaris appears slightly rarefied in macular area. **Limited number areas of flow void** (yellow arrows with dashed yellow circle) are visible, probably due to small non-perfused areas.

B-The cross sectional structural OCT: severe impairment of the retina: an intra-retinal abnormal hyper-reflectivity (yellow arrow) probably due to IRMA and a few cystoid spaces (green arrows) are shown

## CHORIOCAPILLARIS INVOLVEMENT

### 3. In ischemic non-proliferative diabetic retinopathy

In some cases, even in the most severe DM conditions, no clear signs of choriocapillaris involvement are appreciable on OCT-A (Figure 3).

This apparent lack of damage may be due to potential limitations of the current devices:

- Very slow and very fast vascular flows are sometimes not distinguishable,
- As well as minimal damages that exceed the actual lateral or axial resolution.

In other cases the difference in architecture between the choroidal and the retinal vascularization can be considered.

The terminal pattern of the retinal vessels, rather than the anastomotic one of the choriocapillaris and choroid, might suffer more from the chronic damage caused from diabetic micro-angiopathy.

This difference may be due to potential limitations of the current devices (*very slow and very fast vascular flows are sometimes not distinguishable*).

It could also be due to limits in terms of resolution or to the structure of the choroidal and retinal vascularization (*terminal pattern of the retinal vessels versus the anastomotic one of the choriocapillaris*). (Figure 3)

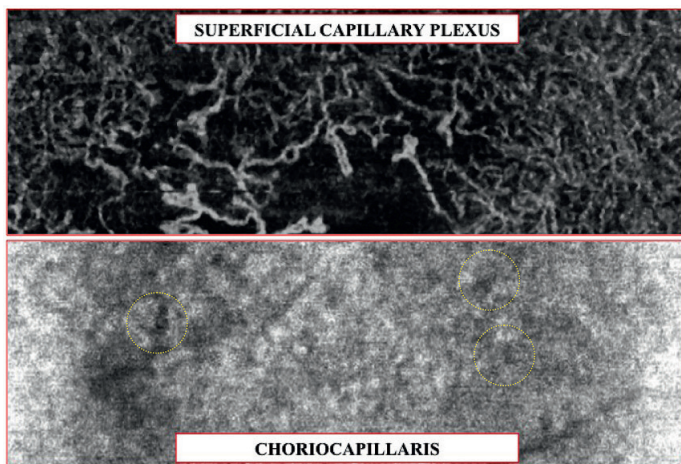


Figure 3: CASE II – Different degree of involvement between deep capillary plexus (DCP) and Choriocapillaris on OCT-A (Patient with severe non-proliferative diabetic maculopathy)

A-Top half of the image: The DCP shows a widely impaired vascular network, with dilated vessels, non-perfused areas, IRMA and extensive areas of non-perfusion.

B- Bottom half of the image: In the same patient, the Choriocapillaris appears minimally rarefied. But some areas of flow void are clearly distinguishable. (*yellow arrows with dashed yellow circle*).

## And previous focal laser treatment

### CHORIOCAPILLARIS INVOLVEMENT IN ISCHEMIC DIABETIC RETINOPATHY

#### 4. And previous focal laser treatment

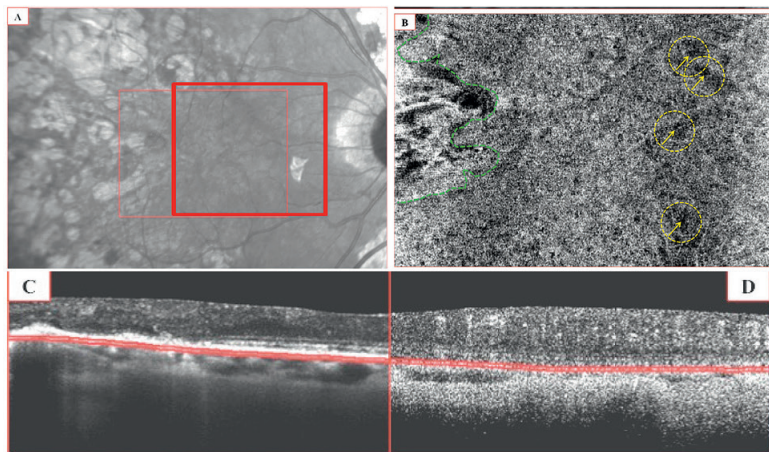
**Laser treatment** determines RPE and choriocapillaris atrophy and, as a consequence, a window defect (Figure 4).

**This will** allow the visualization of the medium and large choroidal vessels.

**On OCT-Angiography**, the deep choroidal vasculature is shown in case of a loss of highly decorrelated structures above (choriocapillaris), [which normally prevents the assessment

of the whole information coming from the perfused tissue below].

In all those cases in which the examined area includes scars (Figure 4) due to a focal thermal laser treatment, the OCT-A C-scans show a window defect of the RPE and the choriocapillaris. In these areas, medium and large choroidal vessels are visible as a consequence of a lack of decorrelated structures above (choriocapillaris).



**Figure 4: CASE III – Choriocapillaris on OCT-A (Patient with severe non-proliferative diabetic maculopathy and previous focal laser treatment)**

A- The infrared, reference image: the scanned area (*red rectangle*) partially includes the scars (temporal side) of a focal thermal laser treatment.

B-C-scan OCT-Angiogram (20- $\mu$ m-thick): the Choriocapillaris appears rarefied in macular region

**Several areas of flow void** are clearly distinguishable (*yellow arrows*).

Moreover, in temporal region, an area of window defect (*dashed green line*) of the RPE and the choriocapillaris is evident as result of a focal laser treatment. In this area, medium and large choroidal vessels are shown, which become visible as a consequence of a loss of decorrelated structures above (choriocapillaris).

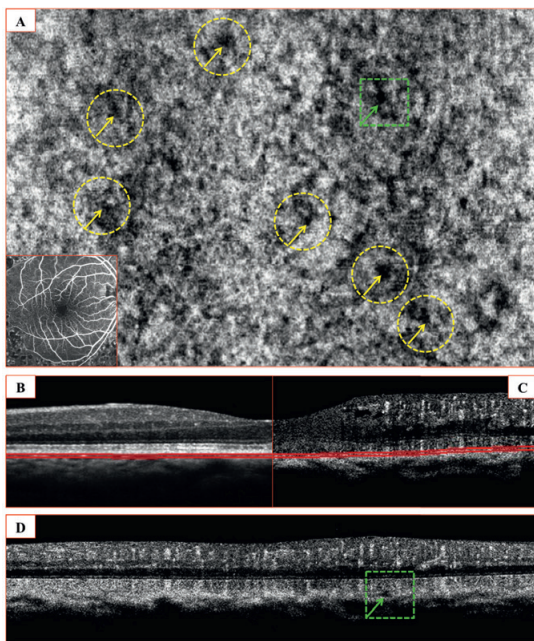
C: The cross sectional structural OCT reveals focal impairments of the outer retinal layers and the RPE in the laser-treated areas.

D: The corresponding OCT-angiogram demonstrates the level of the C-scan above (Figure B), which is taken immediately beneath the Bruch's membrane (*red lines*).

### COMPARISON BETWEEN CHORIOCAPILLARIS FLOW-VOID ON OCT-A OF A MILD RDNP AND AN ARTIFACTUAL CHORIOCAPILLARIS FLOW-VOID

The nature of these localized “flow-void” is generally referred to a pathologically impaired circulation (**Figure 5**).

In order to exclude a *potential artifactual nature* of these areas of absent decorrelation signal, a careful cross sectional analysis should be performed.



**Figure 5: CASE IV – Cross-sectional analysis of a true choriocapillaris flow-void on OCT-A (diabetic patient with mild non-proliferative diabetic maculopathy)**

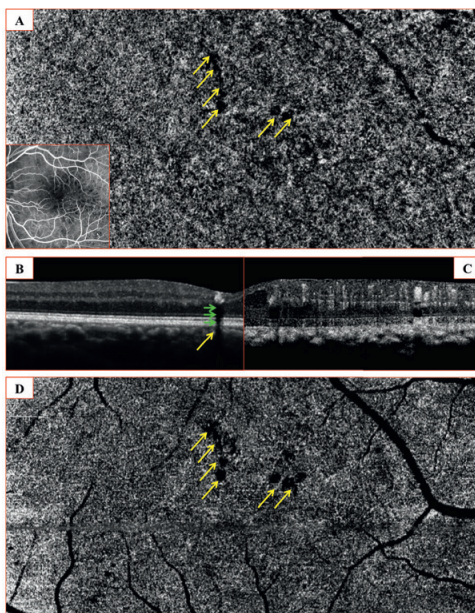
A: C-scan OCT-Angiogram (20- $\mu$ m-thick): The Choriocapillaris shows numerous areas of flow void (yellow arrows), which might be due to diffuse non-perfusion.

B: The cross sectional structural OCT

C: The corresponding OCT-Angiogram, clearly show the level of the C-scan above (Figure A), which is taken immediately beneath the Bruch's membrane (red lines)

D: A focal flow-void has been selected in Figure A (green arrow) and then checked in the corresponding cross-sectional OCT-Angiogram. In this case, the image in C-scan OCT-A clearly correspond to a true flow-void (green arrow), because the B-scan only shows a focal lack of decorrelation signal and no artifactual projections coming from the structures above

### ANALYSIS OF AN ARTIFACTUAL CHORIOCAPILLARIS FLOW-VOID ON OCT-A



**Figure 6: CASE V – Cross-sectional analysis of an artifactual choriocapillaris flow-void on OCT-A (diabetic patient with mild non-proliferative diabetic maculopathy)**

A- C-scan OCT-Angiogram (20- $\mu$ m-thick): The Choriocapillaris shows some areas of flow void (*yellow arrows*), which might be due to focal non-perfusion.

B- When checking the cross sectional structural OCT, it is evidenced the presence of intraretinal hyper-reflective lesions, due to **hard exudates**.

The reflective skills of these intraretinal lesions cause a *dark back shadowing*. As a result, no light passes beyond these structures determining hypointense areas (*pseudo flow-voids*) involving all the levels of depth beneath them.

D - The hypo-intense lesion (*yellow arrow*) is also present in a C-scan section at the level of the outer nuclear layer, exactly in the same location of the choriocapillaris one (Figure A).

On OCT-Angiograms, **areas of flow void** might not be necessarily related to the choriocapillaris non-perfusion.

In some cases, when checking the cross sectional structural OCT (**Figure 6**) it is evidenced the presence of intraretinal hyper-reflective lesions, due to *hard exudates*. The reflective

skills of these intraretinal lesions cause a *dark back shadowing*.

As a result, no light passes beyond these structures determining hypo intense areas (*pseudo flow-voids*) involving all the levels of depth beneath them.



**In conclusion**, the OCT-A assessment of the choriocapillaris and choroid it is extremely useful to detect **potential flow impairment** due to diabetic retinopathy. Although a clear distinction of different vascular abnormalities is not possible at this level of depth, OCT-Angiography seems a useful tool to **detect focal damages**, which could lead to a severe visual impairment.

## REFERENCES

1. Scarinci F, Jampol LM, Linsenmeier RA, et al. Association of Diabetic Macular Non-perfusion With Outer Retinal Disruption on Optical Coherence Tomography. *JAMA Ophthalmol*. 2015 Jul 9. doi: 10.1001/jamaophthalmol.2015.2183.
2. Haugh LM, Linsenmeier RA, Goldstick TK. Mathematical models of the spatial distribution of retinal oxygen tension and consumption, including changes upon illumination. *Ann Biomed Eng*. 1990; 18(1): 19-36.
3. Kur J, Newman EA, Chan-Ling T. Cellular and physiological mechanisms underlying blood flow regulation in the retina and choroid in health and disease. *ProgRetin Eye Res*. 2012;31(5):377-406.
4. Nickla DL, Wallman J. The multifunctional choroid. *ProgRetin Eye Res*. 2010; 29(2):144-168.
5. Spraul CW, Lang GE, Lang GK, Grossniklaus HE. Morphometric changes of the choriocapillaris and the choroidal vasculature in eyes with advanced glaucomatous changes. *Vision Res*. 2002; 42(7):923-932.
6. Hidayat AA, Fine BS. Diabetic choroidopathy: light and electro-nmicroscopic observations of seven cases. *Ophthalmology*. 1985;92(4):512-522.
7. Branchini L, Carmody J, et al. Choroidal thickness in patients with diabetic retinopathy analyzed by spectral-domain optical coherence tomography. *Retina*. 2012;32(3):563-568.
8. Kohner EM, Porta M. Vascular abnormalities in diabetes and their treatment. *Trans Ophthalmol Soc U K*. 1980; 100: 440-444.
9. Huang D, Swanson EA, Lin CP et al. Optical coherence tomography. *Science*. 1991. 254: 1178-1181.
10. Weinberger D, Kramer M, Priel E, et al. Indocyanine green angiographic findings in non-proliferative diabetic retinopathy. *Am J Ophthalmol* 1998;126:238-247.
11. Esmaeelpour M, Povazay B, Hermann B, et al. Mapping choroidal and retinal thickness variation in type 2 diabetes using three-dimensional 1060-nm optical coherence tomography. *Invest Ophthalmol Vis Sci* 2011; 52:5311-5316.
12. Schocket LS, Brucker AJ, Niknam RM, et al. Foveolar choroidal hemodynamics in proliferative diabetic retinopathy. *Int Ophthalmol* 2004;25:89-94.
13. Shiragami C, Shiraga F, Matsuo T, et al. Risk factors for diabetic choroidopathy in patients with diabetic retinopathy. *Graefes Arch Clin. Exp Ophthalmol* 2002;240:436-442.



**CHAPTER X**  
**OCT-ANGIOGRAPHY (SPECTRALIS)**  
**IN**  
**DIABETIC PATIENTS:**  
**MACULAR EDEMA**



## OCT-ANGIOGRAPHY (SPECTRALIS) IN DIABETIC MACULAR EDEMA

**Vision loss due to DR** may result from several mechanisms: *macular edema* and/or *capillary non perfusion* that may directly impair central vision. The most common cause of visual impairment among diabetic patients is **diabetic macular edema (DME)**, accounting for about three fourths of cases of visual loss.

**The prevalence of DME** in Europe is about 3%, while it is substantially higher in Africa and in South America. The most relevant risk factors for the development of DME are: the duration of the diabetes, the type of diabetes, the quality of glycometabolic control and hypertension.

**The development of macular edema** is not limited to diabetic patients but represents a common response to a broad spectrum of potential problems caused by diabetic retinal vascular disease.

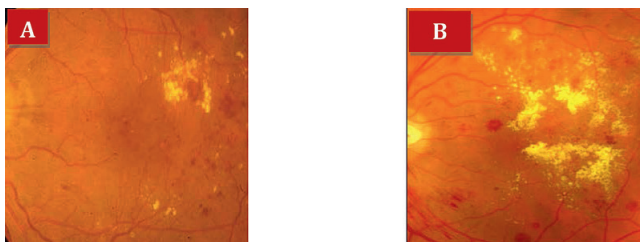
All these factors are mainly referable to oxidative stress, hypoxia and inflammation, which determine an increase in terms of growth factors (i.e VEGF), cytokines and metalloproteinase of the matrix (MMP).

The result is a *diffuse activation of the glial cells* and a significant impairment of the *inner blood retinal barrier*. The predilection of the edema to the macular region is probably secondary to the higher susceptibility of the macula to both ischemic and oxidative stress and to its peculiar anatomical features, for example, loose inter-cellular adhesion and an absence of Müller cells in the fovea.

**The diagnosis of macular edema** is mainly clinical. The gold standard for diagnosing DME is stereoscopic color fundus photography. (**Figure 1**)

In clinical practice, *contact lens and non contact fundus biomicroscopy* is often employed, and it can be useful, especially when there is significant retinal thickening. Conventionally, DME is defined as **retinal thickening and/or presence of hard exudates** within 1 disc diameter of the center of the macula.

The term “*clinically significant macular edema*” (**CSME**), initially defined on the base of biomicroscopic examination, was coined to characterize the severity of the disease and to provide a threshold level to apply laser photocoagulation.



**Figure 1: Color Fundus Photo of Diabetic Macular Edema**

The color fundus photo is a useful method that allows detecting different features of diabetic macular edema. In this case we can appreciate in (A) localized ring of hard exudates, extra foveal and in (B) a loss of macular transparency associated with a large amount of hard exudates (*yellowish deposits*), which involve the macular area but also extend within a large part of the posterior pole.

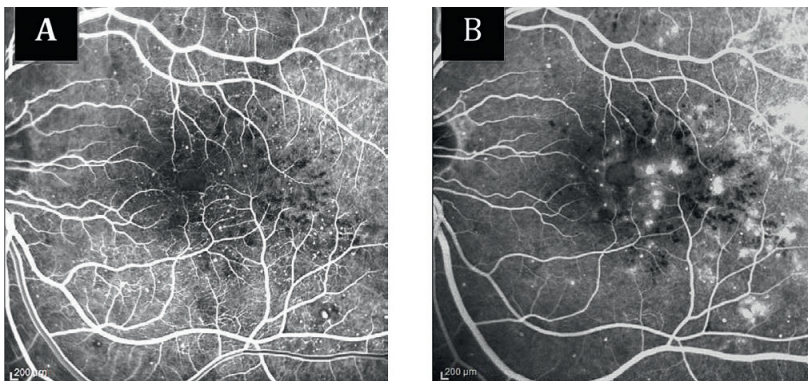
### Fluorescein angiography (FA)

**Fluorescein angiography (FA)** is not necessary for diagnosing DME, but it provides a qualitative assessment of *vascular leakage*, helps in identifying treatable lesions, and is important in assessing the presence of an enlargement of the foveal avascular zone (FAZ), which may be associated with poor visual prognosis. (**Figure 2**)

Fluorescein angiography allows visualizing **leakage** by staining the fluid coming out from the wall of the affected retinal capillaries. It is not, however, sufficient to diagnose a macular edema. A limited diffusion of fluorescein without retinal thickening is not an evidence of a

macular edema. It is useful to detect also *collateral findings* such as: Foveal avascular zone enlargement, perifoveal capillary arcade disruption and non-perfusion areas.

**FA shows the origin of leakage** from micro aneurysms or impaired macular capillaries. It may also show, on late phase of the angiogram, the accumulation of fluid into *intra-retinal cystoid spaces* and enable to assess the extension of clinically significant macular edema and macular non-perfusion, which might have a significant prognostic value. **Peripheral non-perfusion**, associated to CSME, may be also be evaluated on FA.



**Figure 2:**

**A-Early phase of Fluorescein Angiography of a diabetic patient**

The early arterial-venous phase of fluorescein angiography is useful to highlight retinal vascular impairment due to diabetic retinopathy. The enlargement of the foveal avascular zone is clearly appreciable, associated with a reduced visibility of perfused capillaries in macular area. Numerous micro aneurysms are visible in macular area and at the posterior pole.

**B-Late phase of Fluorescein Angiography of a diabetic patient**

The late-venous phase of fluorescein angiography is useful to highlight the degree of leakage from impaired vascular structures. The diffuse leakage is clearly visible in the macular area suggesting the presence of diabetic macular edema. Highly hyperfluorescent micro aneurysms are surrounded by a ring of hypofluorescent hard exudates.

DME can also be classified into focal and diffuse: *Focal macular edema* is characterized by the presence of localized areas of retinal thickening,

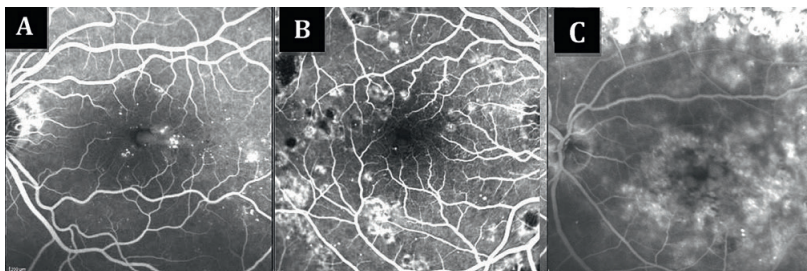
derived from focal leakage of individual micro aneurysms or clusters of micro aneurysms as demonstrated with FA (**Figure 3**).

*Diffuse macular edema* is derived from extensively damaged capillaries, and it is characterized by a more widespread thickening of the macula.

*Cystoid macular edema (CME)*, often associated with diffuse macular edema, results from a generalized breakdown of the BRB with fluid

accumulation in a petaloid pattern, primarily in the outer plexiform and inner nuclear layers. (**Figure 3**).

*In clinical practice* the distinction between focal and diffuse edema is not always clear and a wide variety of mixed forms are observed.<sup>1</sup>



**Figure 3: Evaluation on Fluorescein Angiography of different degrees of a diabetic macular edema**  
A- *Focal macular edema*: a weak diffusion is visible mainly around micro aneurysms. The central macula is minimally (or not) affected by the exudation.  
B - *Diffuse macular edema*: a widespread involvement of the central macular region is visible with a diffuse leakage during the late phases of FA.  
C - *Cystoid macular edema*: the typical "petaloid" pattern of DME is visible in macular area. This is the result from a generalized breakdown of the BRB with fluid accumulation, primarily in the outer plexiform and inner nuclear layers.

## OPTICAL COHERENCE TOMOGRAPHY (OCT)

**Optical coherence tomography (OCT) imaging** helps in estimating intraretinal modifications, in highlighting the existence of serous retinal detachment, in assessing the vitreo-retinal interface, and in measuring the thickened retina.<sup>1</sup>

In the case of DME, OCT demonstrates an increased **retinal thickness** and the loss of foveal depression due to the presence of low-reflective spaces (cystoid spaces) both located at the inner and outer retinal layers. (Figures 5-6)

Spectral Domain OCT (SD-OCT) can visualize *small cystoid spaces*, even in case of moderate retinal thickening.

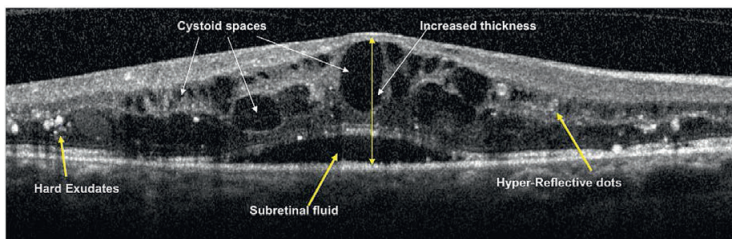
*Hard exudates* are mainly located at the inner retinal layers and they are generally detected as highly reflective intraretinal lesions associated with hypo reflective back-shadows. All these features might coexist in the same OCT B-scan.

*A serous retinal detachment*, seen in 15% of eyes with DME, appears as a shallow elevation of the retina, with an optically empty space between the retina and the RPE.

The pathogenesis and the *functional consequences* of serous retinal detachment associated with cystoid macular edema are still unknown. It may be a sign of early dysfunction of the outer BRB.

It may also allow detecting the presence of disorganization of the inner retinal layers (DRIL). **DRIL** is defined as the inability to identify any

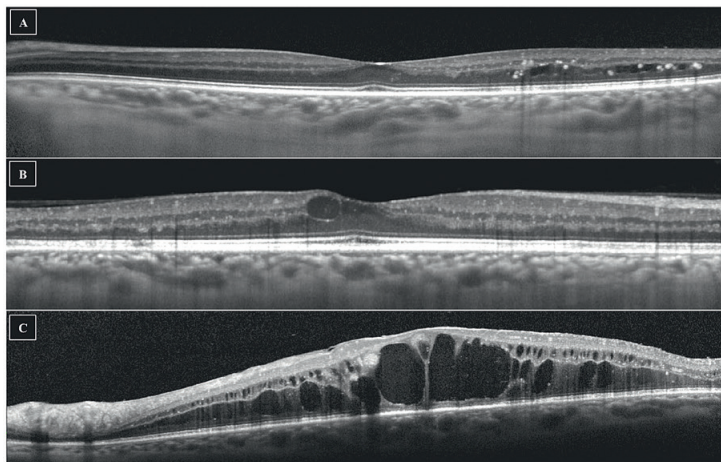
boundaries between the ganglion cell–inner plexiform layer complex, inner nuclear layer, and outer plexiform layer.



**Figure 4: Optical Coherence Tomography (OCT) B-scan of a diabetic macular edema**

The OCT imaging may show different features of diabetic macular edema. A *thickened retina* is visible here with complete loss of the foveal depression. *Cystoid spaces* are both located at the level of inner and outer nuclear layers. *Hard exudates* are visible as highly hyper reflective spots inside the retina and also numerous *hyper reflective dots*, sign of inflammatory reaction, are appreciable.

The current case also shows a *serous retinal detachment* which might be due to a potential impairment of the outer retinal barrier.



**Figure 5: Evaluation on Optical Coherence Tomography of different degrees of a diabetic macular edema**  
A - *Focal macular edema*: limited intraretinal serous exudation is visible in extra-foveal area. Several hyper reflective foci are also shown, probably due to hard exudates.  
B - *Moderate macular edema*: intraretinal fluid accumulation with diffuse impairment of the foveal depression.  
C - *Severe cystoid macular edema*: massive intraretinal exudation, involving the entire retinal thickness and determining macular pseudo-retinoschisis, mainly at the inner and outer nuclear layers.



## OCT-ANGIOGRAPHY

Newer methods, in particular **OCT-Angiography** with different types of amplitude-decorrelation algorithms, allow OCT to provide *non-invasive*, three-dimensional mapping of the retina and choroidal microvasculature.

**Optical coherence tomography angiography** has shown promise in identifying vascular changes in diabetic retinopathy.

Jia et al.<sup>2</sup> imaged neo-vascularization and quantified areas of **macular ischemia** in DR. Their quantification of macular ischemia involved measuring the diameter of the foveal avascular zone and the total area of vessel non-perfusion.

Ishibazawa et al.<sup>3</sup> used OCT-Angiography to image micro aneurysms, venous beading, neo-vascularization, and non-perfused areas. They also quantified the area of non-perfusion in

addition to neo-vascularization using this imaging modality.

Couturier et al.<sup>4</sup> studied the ability of OCT-A to detect diabetic microvascular changes compared to fluorescein angiography: they concluded that OCT-A accuracy for assessing capillary non-perfusion was better than FA and might enable a proper grading of diabetic retinopathy progression.

Despite these recent advances, there remains a gap in our diagnostic capabilities for quickly and non invasively **grading DR** in a simple, comparable way. With this new, non invasive technique, we might **identify progressive changes in DR** and provide easily interpretable qualitative and quantitative pictures of retinal vascularity.

## DIABETIC MACULAR EDEMA

Although diabetic macular edema is mainly a morphological, rather than functional, feature of diabetic maculopathy, we consider important to distinguish DME on an OCT-Angiogram.

**Diabetic macular edema**, as on fluorescein angiography or OCT, may show also on OCT-Angiography different patterns that should be recognized in order to avoid potential pitfalls and misleading interpretations of the images.

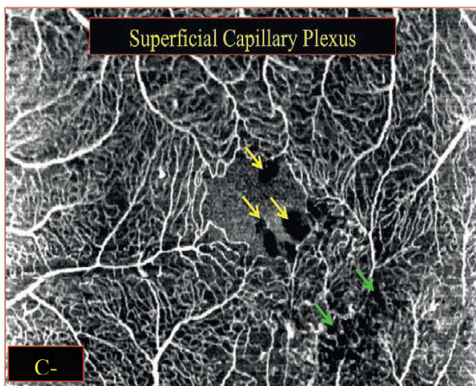
*Diabetic macular edema* may appear on OCT-Angiography as:

- (1)-**Hypo-intense intraretinal spaces**
- (2)-**Grayish intraretinal spaces**
- (3)-**Focal hyper-intense clumps**

### 1. HYPO INTENSE INTRARETINAL SPACES

**Hypo-intense intraretinal spaces** are roundish structures, which may vary in dimension and location depending on the depth of the C-scan section. These findings are due to the presence

of, black, intraretinal cystoid spaces (**Figure 6**) and they are mainly located in proximity of non-perfused areas.



**Figure 6: Optical Coherence Tomography Angiography C-scan of the Superficial Capillary Plexus in case of diabetic macular edema.**

The OCT-Angiogram above may show the superficial capillary plexus of a patient suffering from a mild non-proliferative diabetic retinopathy.

The enlargement of the foveal avascular zone (FAZ) is associated with focal capillary dilations and small areas of capillary non-perfusion.

The presence of large, roundish, hypo-intense lesions (*yellow arrows*), which are due to cystoid spaces in the perifoveal area. Smaller black cystoid lesions are also visible in the extra-foveal area (*green arrows*).

These findings are generally preceded by focal capillary dilations and zones of capillary non-perfusion.

As in structural OCT, their dimension may vary from few-microns lesion to large ones, almost involving the entire thickness of the retina.

The larger ones are more frequently located in subfoveal and para-foveal area, while smaller ones are more peripheral in macular and extra-macular area.

**Substantial differences** of hypo intense intraretinal spaces in terms of distribution may be noticed between the superficial and the deep capillary plexuses. The degree of involvement

of the two vascular layers might explain the **high variability** of aspect.

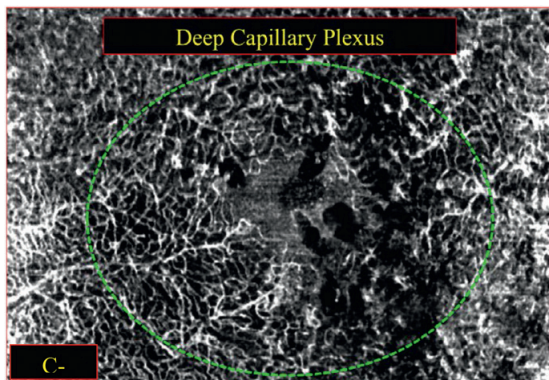
The latter are often visible at the level of the inner nuclear layer, which is bracketed by the two components of the deep capillary plexus. (**Figure 7**)

The same findings are visible on the corresponding B-scan OCT-Angiogram, showing similar features. (**Figure 8**)

**Hypo-intense intraretinal spaces** are the most common pattern of diabetic macular edema on OCT-Angiography, associated with intra-retinal fluid accumulation.

This cystoid morphology is quite similar to the one of structural OCT, but in this case borders

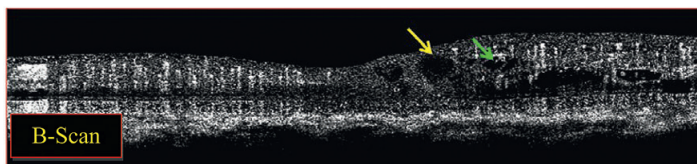
are not well-demarcated and therefore more difficult to distinguish.



**Figure 7: Optical Coherence Tomography Angiography C-scan of the deep capillary plexus in case of diabetic macular edema**

The OCT-Angiogram, taken at the level of the inner nuclear layer, clearly shows the *deep capillary plexus*. A diffuse reduction of the vascularity is visible coupled with an enlargement of the foveal avascular zone (FAZ), focal capillary dilations and areas of capillary non-perfusion.

Numerous hypo-intense lesions (*cystoid spaces*) are appreciable in macular area (*dashed green line*).



**Figure 8: Optical Coherence Tomography Angiography B-scan in case of diabetic macular edema.**

The B-scan OCT-Angiogram highlights the presence of large cystoid spaces in perifoveal area (*yellow arrow*), while the smaller ones are mainly visible at the level of the inner nuclear layer, where the deep capillary plexus is located (*green arrow*).

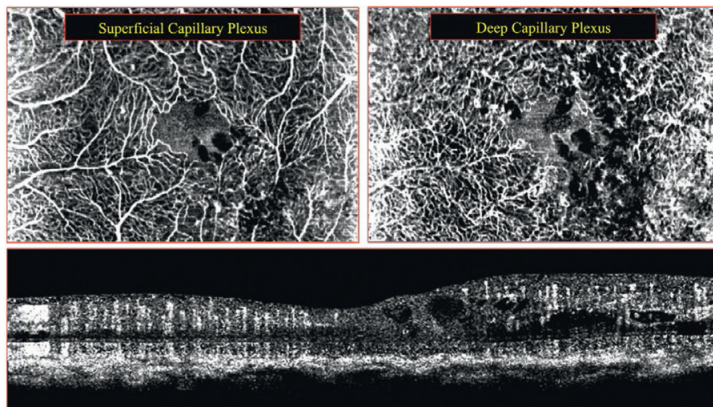
The hyper-intense structures that are visible at the level of the inner retinal layers are referred to transverse sections of retinal capillaries.

It is difficult to visualize the eventual vascular abnormalities with the cross sectional OCT (B-scan), but it is highly useful to evaluate the morpho-functional correlation with the corresponding structural B-scan.

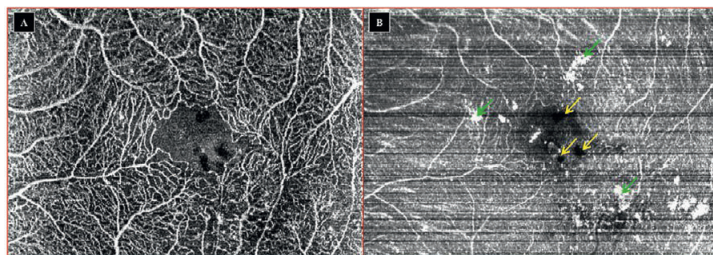
For a comprehensive assessment of a DME patient on OCT-Angiography, the imaging approach need to include a C-scan section taken at the level of the ganglion cell layer (*superficial capillary plexus*), another one taken at the inner nuclear layer (*deep capillary plexus*) and the corresponding B-scan passing through the foveal depression.

*plexus*) and the corresponding B-scan passing through the foveal depression. (Figure 9).

This approach may also be enriched with the structural OCT C-scan (En-Face) (Figure 10).



**Figure 9:** Diabetic macular edema (DME) : Comprehensive assessment of a DME patient on OCT-Angiography  
The imaging approach includes: 1. a C-scan section taken at the level of the ganglion cell layer (*superficial capillary plexus*), 2. another one taken at the inner nuclear layer (*deep capillary plexus*) and 3. The corresponding B-scan passing through the foveal depression.



**Figure 10:** Diabetic macular edema (DME) evaluated on OCT-Angiography and on “En-Face” Structural OCT (C-scan section taken at the level of the ganglion cell layer).  
A: the entire vascular network of the Superficial Capillary Plexus, and some intraretinal cystoid spaces as dark, black, hypo intense intraretinal structures.  
B. the corresponding En-Face image in which both the cystoid lesions and some hyper reflective spots, due to hard exudates are visible. The combined analyses of the structural (En-Face) and functional (OCT-A) images allow a better definition of the degree of involvement, in case of diabetic maculopathy.

## 2. GREYISH INTRARETINAL SPACES

**Large intraretinal cystoid spaces** may sometime appear with a *greyish aspect*. This particular pattern may be confusing when interpreting an OCT-Angiogram, because sharing almost the same signal intensity of inter-vascular spaces.

The Authors hypothesized that this peculiar aspect might be due to the *presence of active motion insi de* these spaces.

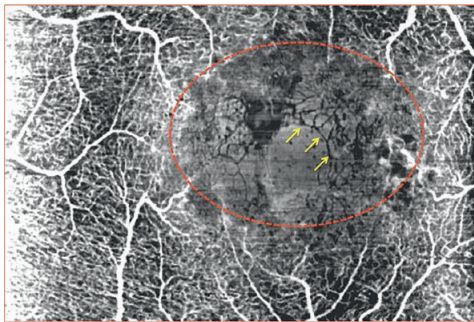
This resulted therefore in a weak decorrelation signal, which has its origin in the Brownian motion of the molecules that are consequence of an intense intraretinal exudation.<sup>5</sup> **(Figure 11)**

Both C-scan and B-scan visualization allow to distinguish this peculiar phenomenon. **(Figure 11)**

This greyish aspect of the large cystoid spaces may sometimes highlight the presence of non-perfused vessels in the inter-cystoid tissue. **(Figure 11)**

These vessels appear as well-defined tubular structures, without any decorrelation signal inside.

Non-perfused vessels are normally not detectable with OCT-Angiography, since no decorrelation signal is comes from flowing blood: the difference in terms of signal intensity between these vessels and greyish cystoid spaces around makes them clearly distinguishable.



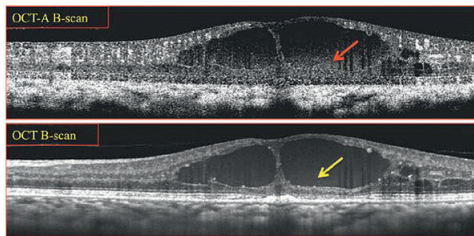
**Figure 11: Greyish intraretinal spaces as a sign of DME on OCT-Angiography**

The C-scan OCT-Angiogram is taken at the level of the ganglion cells layer and therefore shows the *superficial capillary plexus*.

The foveal avascular zone (FAZ) and the macular capillary network are no more visible due to the severe impairment or retinal vascularity.

The OCT-A shows large areas of vascular non-perfusion partially filled by large greyish intraretinal spaces (*dashed red line*).

This peculiar aspect is given by the Brownian motion of the molecules that are consequence of an intense intraretinal exudation. Non-perfused vessels, as well-defined dark tubular structures in the inter-cystoid tissue, are highlighted by the weak decorrelation signal of the cystoid spaces around.



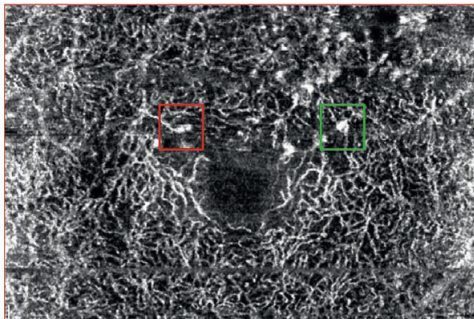
**Figure 12: Greyish intraretinal spaces as a sign of DME on OCT-Angiography and structural OCT B-scans**  
The B-scan OCT-Angiogram (*top*) shows a weak decorrelation signal inside large cystoid spaces (*red arrow*). The corresponding structural B-scan (*bottom*) shows a mild diffuse reflectivity inside the corresponding location inside the cyst.

### 3. FOCAL HYPERINTENSE CLUMPS

On C-scan OCT-Angiograms of a patient with diabetic maculopathy can be often shown *highly decorrelated roundish or fusiform structures*, which are generally interpreted as microaneurysms or intra retinal vascular

abnormalities (IRMA).

This focal hyper-intense signal may unfortunately be related also to non-decorrelated lesions such as hard exudates. (**Figure 13**)



**Figure 13: Optical Coherence Tomography Angiography C-scan of the Deep Capillary Plexus (diabetic macular edema) showing different types of hyper intense structures.**

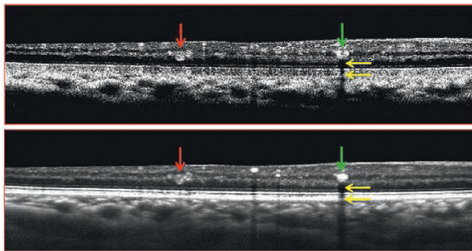
The OCT-Angiogram taken at the level of the inner nuclear layer clearly shows the deep capillary plexus. The fusiform hyper-intense structure (*red square*) shows the typical appearance of a microaneurysm.

The roundish hyper-intense lesion (*green box*) although sharing some similarities with the previous one, is due to a focal accumulation of hard exudates.

These assume this aspect on OCT-A because, as hyper-reflective structures, are able to reflect the refracted signal coming from the perfused (decorrelated) vessels above. The latter are hyper-reflective structures on structural OCT and hyper-intense ones on OCT-Angiography.

**Intraretinal hyper-reflective material** due to hard exudates appears hyper-intense on OCT-A, because completely reflects the refracted signal coming from the perfused (decorrelated) vessels above.

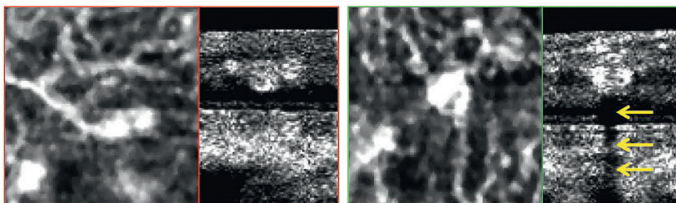
Unlike the RPE and the true perfused lesions (i.e. micro aneurysms) these intraretinal clumps are associated on OCT-A B-scan with *typical dark back shadowing*, implying that the light that hit these deposits was largely reflected.<sup>6</sup> (Figure 14)



**Figure 14: Focal hyper intense clumps as a sign of DME on OCT-Angiography and structural OCT B-scans**

The B-scan OCT-Angiogram (top) shows two decorrelated intraretinal structures. One of these (red arrow) does not show any additional finding above or below the lesion itself, while the second one (green arrow) is associated with a dark back shadowing (yellow arrows).

This phenomenon is linked to the high reflectivity of the hard exudates. The corresponding structural B-scan (bottom) highlights the difference in reflectivity of the two intraretinal lesions (microaneurysm [red arrow] Versus hard exudates [green arrow]).



**Figure 15: Comparative C-scan and B-scan analysis of focal hyperintense clumps in DME**

The simultaneous analysis of the C-scan and the B-scan on OCT-A, which is available on the Spectralis OCT2 automated software, could help to avoid some pitfalls and guide the differential diagnosis between truly perfused lesions (left) and artifactual hyper-intense structures (right).

The presence of dark back shadowing (yellow arrows) could help to distinguish these findings and thus to ensure an accurate diagnostic process.

This phenomenon could also explain the focal lack of signal, corresponding to the lesion area, observed on C-scan OCT-A below the same lesion. **(Figure 15)** The peculiar appearance is not due to impaired perfusion of the deeper tissue but rather to a “*shielding effect*” caused by the high reflectivity of the clumps above.

This particular finding is obtained from a simultaneous analysis of the C-scan and the B-scan on OCT-A, which is available on the Spectralis OCT2 automated software.

It could help to **avoid some pitfalls** and guide the differential diagnosis.

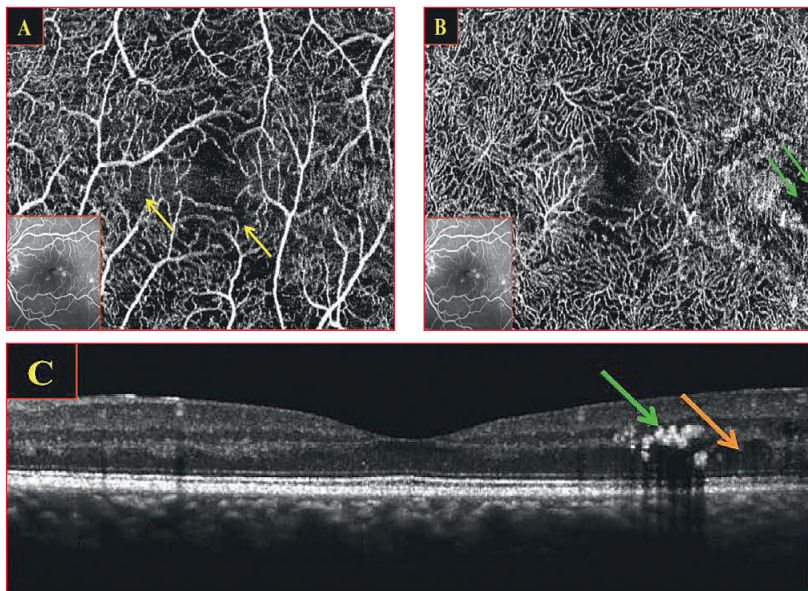


**Cas cliniques d'OMD:  
Différents degrés de sévérité**

**DME: DIFFERENT DEGREES OF MACULAR INVOLVEMENT**

**Cas cliniques d'OMD:  
Différents degrés de sévérité**

**CASE N° 1 : Mild non-proliferative diabetic retinopathy with focal macular edema.**



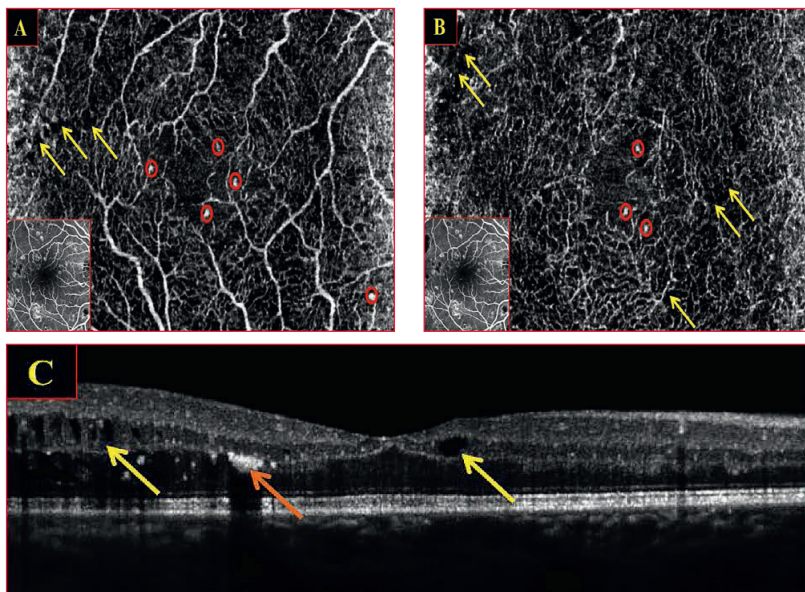
**Figure 16: Mild non-proliferative diabetic retinopathy with focal macular edema**

**A** - The OCT-Angiogram shows a rarefied Superficial Capillary Plexus with numerous perifoveal areas of non-perfusion.

**B** - At the level of the Deep Capillary Plexus, several roundish, hypo-intense lesions (*green arrows*) are visible: these are due to cystoid spaces and hard exudates in extra-foveal area.

**C** The structural B-Scan OCT highlights the presence of hyper reflective intraretinal lesions (*hard exudates, green arrow*) and extra-foveal cystoid spaces (*orange arrow*).

**CASE II : Moderate non-proliferative diabetic retinopathy with macular edema**



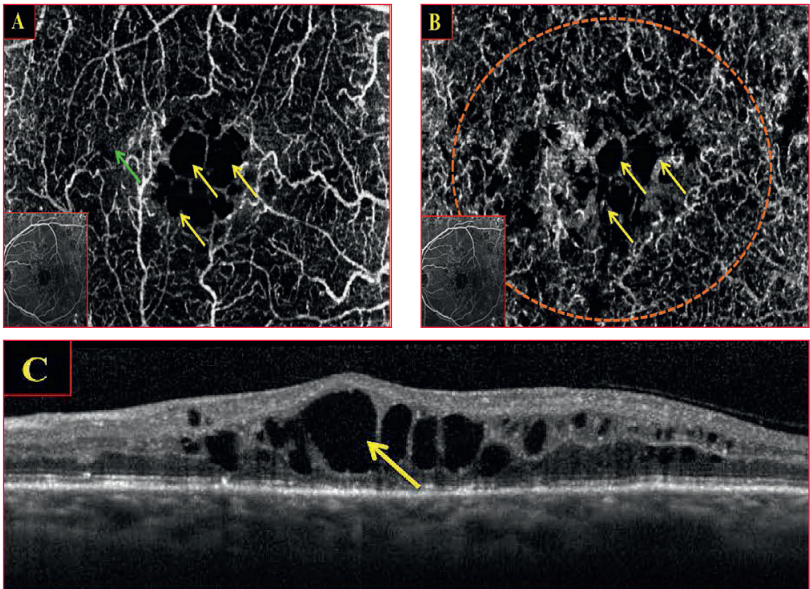
**Figure 17: Moderate non-proliferative diabetic retinopathy with macular edema**

**A** - The Superficial Capillary Plexus (SCP) shows numerous hyper intense structures probably due to microaneurysms (*red circles*) and some hypo intense intraretinal spaces (*yellow arrows*).

**B** - At the level of the Deep Capillary Plexus (DCP), microaneurysms are still visible (*red circles*). The number of cystoid spaces (hypo intense intraretinal structures, *yellow arrows*) is substantially higher than SCP.

**C** - The structural B-Scan OCT highlights the presence of hyper reflective intraretinal lesions (hard exudates, *orange arrow*) and cystoid spaces (*yellow arrows*).

**CASE III : Severe non-proliferative diabetic retinopathy with cystoid macular edema**



**Figure 18: Severe non-proliferative diabetic retinopathy with cystoid macular edema**

**A** - The Superficial Capillary Plexus (SCP) shows focal vessel dilations, variably sized non-perfused areas (*green arrow*) and numerous hypo intense roundish structures due to intraretinal cystoid spaces (*yellow arrows*).

**B** The Deep Capillary Plexus (DCP) appears rarefied (*orange dashed line*). Numerous cystoid spaces (hypo intense intraretinal structures, *yellow arrows*) are also appreciable.

**C** - The structural B-Scan OCT highlights the presence of an extensive intraretinal exudation (*yellow arrows*).

## REFERENCES

- 1. Bandello F, BattagliaParodi M, Lanzetta P, Loewenstein A, Massin P, Menchini F, Veritti.** Diabetic macular edema. *Dev Ophthalmol.* 2010; 47:73-110.
- 2. Massin P, Girach A, Erginay A, Gaudric A.** Optical coherence tomography: a key to the future management of patients with diabetic macular oedema. *Acta Ophthalmol Scand* 2006;84:466–474.
- 3. Jia Y, Bailey S, Hwang T, et al.** Quantitative optical coherence tomography angiography of vascular abnormalities in the living human eye. *Proc-NatlAcadSci USA Proceedings of the National Academy of Sciences* 2015.
- 4. Ishibazawa A, Nagaoka T, Takahashi A, et al.** Optical coherence tomography angiography in diabetic retinopathy: a prospective Pilot study. *Am J Ophthalmol* 2015;160:35–44.
- 5. Couturier A, Mané V, Bonnin S, et al.** Capillary Plexus Anomalies In Diabetic Retinopathy On Optical Coherence Tomography Angiography. *Retina.* 2015 Nov;35(11):2384-91.
- 6. Spaide RF, Fujimoto JG, Waheed NK.** Image artifacts in optical coherence tomography angiography. *Retina* 2015;35:2163–80.
- 7. Lupidi M, Coscas G, Cagini C, et al.** Optical coherence tomography angiography of a choroidal neovascularization in adult onset foveomacular vitelliform dystrophy: pearls and pitfalls. *Invest Ophthalmol Vis Sci.* 2015;56:7638–7645.

**CHAPTER XI**  
**SPECTRALIS OCT-ANGIOGRAPHY**  
**IN**  
**DIABETIC PATIENTS:**  
**MACULAR ISCHEMIA**



## SPECTRALIS OCT-ANGIOGRAPHY IN DIABETIC MACULAR ISCHEMIA

Two different vascular layers are supplying the high oxygen demand of the human retina.

- The *inner retinal layers* are exclusively supplied by the retinal circulation, while
- *the outer retinal ones*, which are completely avascular, obtain their oxygen supply mainly via diffusion from the choroidal tissue and only minimally from the retinal circulation.<sup>1,2</sup>

**Retinal vascular supply in the macula** consists of 3 capillary plexuses.

The *superficial capillary plexus* (SCP) lies in the ganglion cell layer, while the double-layered *deep capillary plexus* (DCP) is located on the inner and outer borders of the inner nuclear layer.

The deep capillary plexus provides from 10% to 15% of the oxygen supply to the photoreceptor cells, especially during dark adaptation.

Foveal and perifoveal area are completely avascular, therefore the oxygen supply comes almost only from the choriocapillaris, with a minimum contribution from surrounding reti-

nal capillaries. This “capillary-free zone” is called **foveal avascular zone (FAZ)** and may significantly vary in terms of shape and dimension, either in healthy subjects or in different pathologic conditions.<sup>3, 4</sup>

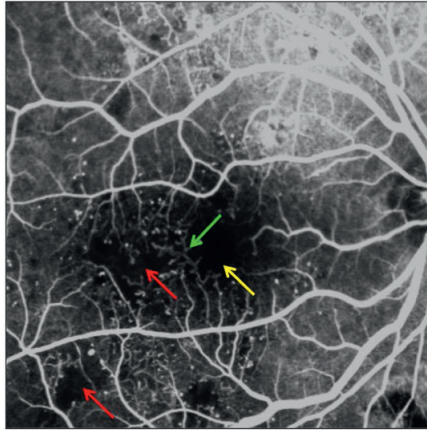
Normally, the FAZ is approximately 350  $\mu\text{m}$  to 750  $\mu\text{m}$  in diameter. Even in absence of macular edema in diabetic eyes, abnormalities of the FAZ are often seen, and include irregular margins and widening of the inter-capillary spaces.

**Diabetic macular ischemia (DMI)** is an important cause of severe visual impairment in patients with diabetic retinopathy. DMI is characterized by the enlargement of the foveal avascular zone, by the disruption of the perifoveal capillary arcade, and by retinal capillary loss in other, non contiguous areas of the macula (capillary drop-out)<sup>5</sup>

**Standards for assessment of DMI severity** were first established in the Early Treatment Diabetic Retinopathy Study (ETDRS) in the 1980s.<sup>6</sup>

All these findings are commonly evaluated with the **fluorescein angiography (FA)**. FA shows several signs of retinal vascular impairment including micro aneurysms, capillary dilations, intra retinal micro vascular abnor-

malities (IRMA) and capillary dropout. It may also show, on late photographs, the existence of cystoid spaces and enable assessment as to **the extent** of macular non-perfusion, which has a significant prognostic value. **(Figure 1)**.



**Figure 1: Fluorescein angiography of Diabetic Maculopathy**

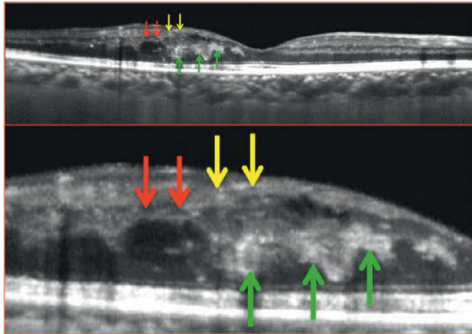
The early venous phase of fluorescein angiography is useful to highlight retinal vascular impairment due to diabetic retinopathy. It is clearly shown

- the enlargement of the foveal avascular zone, which appears highly hypo-fluorescent, and it is associated with an - evident disruption of the perifoveal capillary arcade (*yellow arrow*).
- Non-perfused areas are present in macular area, extra-macular area and at the posterior pole (*red arrows*).
- Intraretinal micro vascular abnormalities (or possibly an intraretinal neovascularization) are visible in macular area (*green arrow*).

**Optical coherence tomography (SD-OCT)** shows a thinning of the inner retinal layers, including the ganglion cell layer and retinal nerve fiber layer, in patients with diabetic macular ischemia. **(Figure 2)**

**Optical coherence tomography angiography (OCT-A)** is a promising new imaging approach, which is able to show the actively perfused structures.





**Figure 2: Optical Coherence Tomography (OCT) B-scan of a diabetic macular ischemia (Top image: full macular area; Bottom Image: Zoomed visualization of the involved area)**

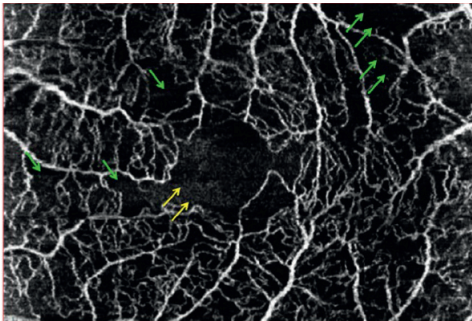
The OCT imaging may show different indirect signs of diabetic macular ischemia.

A focally thickened retina is visible, due to the presence of intraretinal exudation, with a preserved foveal depression. Cystoid spaces are both located at the level of inner and outer nuclear layers.

Intraretinal micro vascular abnormalities (IRMA) are visible as highly hyper reflective lesions inside the retina (*green arrows*).

Macular ischemia has induced a thinning of the ganglion cells layer (GCL, *yellow arrows*) and of the inner nuclear layer (INL, *red arrows*).

This might mean that the impaired perfusion both involved the superficial capillary plexus and the deep capillary plexus, which are located at the level of the GCL and INL respectively.



**Figure 3 - Optical Coherence Tomography Angiography (OCT-A) C-scan of a diabetic patient with macular ischemia: Superficial Capillary Plexus**

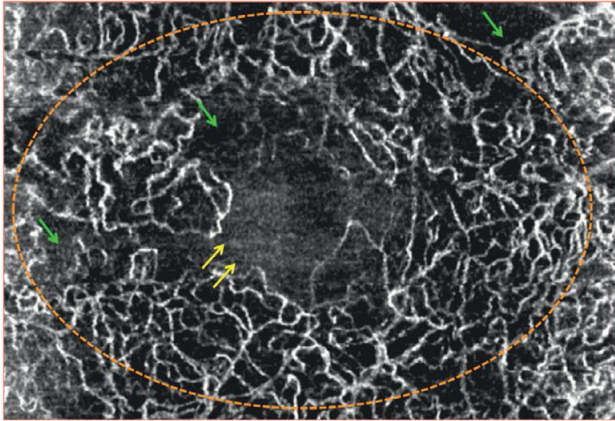
The OCT-A shows a substantially rarefied superficial capillary plexus.

The foveal avascular zone is enlarged and an interruption of the perifoveal capillary arcade is clearly visible (*yellow arrows*).

Numerous areas without any decorrelation signal, considered as non-perfused areas (*green arrows*) are also shown.

It appears therefore possible that OCT-A can be a **valid tool to visualize and quantify** capillary

non-perfusion as a potential sign of macular ischemia in DR. (**Figure 3 – 4**)



**Figure 4 - Optical Coherence Tomography Angiography (OCT-A)  
C-scan of a diabetic patient with macular ischemia: Deep Capillary Plexus.**

A rarefied deep capillary plexus (*orange dashed line*) is visible on the OCT-Angiogram.

The foveal avascular zone is enlarged and it is associated with an interruption of the perifoveal capillary arcade (*yellow arrows*).

Areas of non-perfusion (*green arrows*), characterized by the absence of any decorrelation signal, are also appreciable.

### **PATTERNS OF DIABETIC MACULAR ISCHEMIA: (OCT-A ASSESSMENT)**

**Diabetic macular ischemia (DMI)** is an important clinical feature of diabetic retinopathy (DR).

It has been postulated that the selective loss of

*pericytes and thickening of the basement membrane* in retinal capillaries occurs as a result of exposure to elevated blood glucose over an extended period of time.<sup>7</sup>

**Clinically**, DMI is defined by an enlargement of the foveal avascular zone (FAZ) and paramacular areas of capillary non-perfusion.

Recently, an analysis of the RIDE and RISE trials showed that patients with DMI at baseline progressed earlier to neovascular complications of DR during intravitreal ranibizumab treatment than those with normal perfusion at baseline.<sup>8</sup>

Therefore, baseline assessment of DMI when initiating anti-VEGF therapy for diabetic macular edema (DME) has clinical implications and may be of practical importance when planning review schedules for reassessment of peripheral retinopathy grades for patients receiving injections.

**Fluorescein angiography (FA)** is widely recognized as an essential tool in the diagnosis and treatment of DR and DMI since assessing the

level of macular ischemia can often provide important clinical and prognostic information on disease severity and progression.

The recent development of **OCT angiography** allows for the visualization of the retinal capillary layers and for the construction of microvascular flow maps.

This imaging of the retinal vasculature is novel, and seems able to provide reliable information about areas of **flow impairment**, which are at the base of macular ischemia, without the need for injection of fluorescein sodium dye.

*Different degrees of DMI* may be identified on OCT-Angiograms:

- **Focal Macular Ischemia (FMI)**, (**Figure 5**)
- **Moderate Macular Ischemia (MMI)** and
- **Severe Macular Ischemia (SMI)**. (**Figures 5,6,7**).

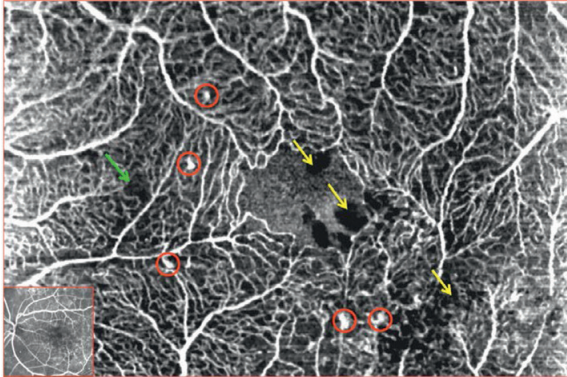
## **1. FOCAL MACULAR ISCHEMIA (FMI)**

**Focal Macular Ischemia (FMI)** is characterized on OCT-A assessment by the presence of small non-confluent areas, without any decorrelation signal. (**Figure 5**)

These areas of focal macular ischemia are suspicious of a very initial flow impairment,

which is generally hidden on standard fluorescein examination.

These findings are generally *associated with all those of diabetic maculopathy*, such as microaneurysms, hemorrhages and DME.



**Figure 5 - Optical Coherence Tomography Angiography (OCT-A)  
C-scan of a diabetic patient with Focal Macular Ischemia (FMI)**

The OCT-A shows very limited areas of flow absence (*green arrow*). This might be a very initial sign of vascular impairment, which is potentially involved in ischemic process. Several other features of diabetic maculopathy are also appreciable, such as: enlargement of the FAZ, microaneurysms (*red circles*) and dark black cystoid spaces (*yellow arrows*).

## **2. MODERATE MACULAR ISCHEMIA (MMI)**

**Moderate Macular Ischemia (FMI)** is characterized by several non-confluent areas without any decorrelation signal.

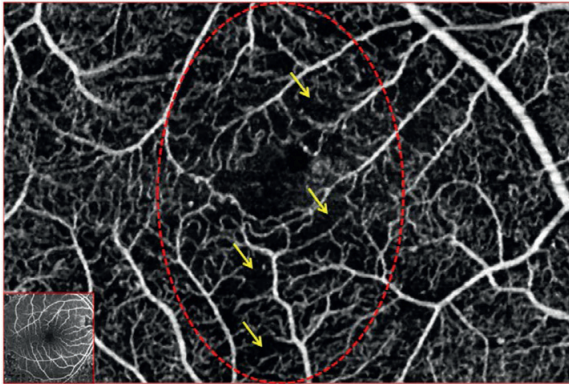
The rarefaction of the vascular network and the consequent appearance of these flow-void areas are probably the result of more significant capillary non-perfusion. (**Figure 6**)

These findings are generally related to more severe stages of non-proliferative diabetic

retinopathy, like moderate or severe DR.

At the borders of these “non-perfused” areas are generally located micro aneurysms, venous beading or focally dilated vessels: all these features are signs of a progressively increasing vascular impairment.

At these stages, only *some tiny non-perfused areas* are also visible on conventional fluorescein angiography.



**Figure 6 - Optical Coherence Tomography Angiography (OCT-A)  
C-scan of a diabetic patient with Moderate Macular Ischemia (MMI)**

The OCT-A shows several areas of flow absence (*yellow arrows*) in a diffusely rarefied superficial capillary network.

These flow-void areas and the contiguous vascular abnormalities such as micro aneurysms, venous beading and focal vessels dilations are related to a *more severe stage* of diabetic retinopathy.


### **3. SEVERE MACULAR ISCHEMIA (SMI)**

**Severe Macular Ischemia (FMI)** is a late stage of diabetic macular impairment, where confluent areas without any decorrelation signal largely involve the scanned area. (**Figure 7**)

Capillaries are rare and the only decorrelation

signal in large areas is the one belonging to large retinal vessels.

These findings are related to late stages of non-proliferative diabetic retinopathy or to proliferative diabetic retinopathy.



**Figure 7 - Optical Coherence Tomography Angiography (OCT-A)  
C-scan of a diabetic patient with Severe Macular Ischemia (SMI)**

The OCT-A shows large areas of flow absence (*yellow arrows*), in a diffusely rarefied superficial capillary network (*green dashed lines*).

These flow-void areas are related to severe stage of non-proliferative diabetic retinopathy or proliferative diabetic retinopathy.

#### **4. SUPERFICIAL CAPILLARY ISCHEMIA:** **"COTTON-WOOL" SPOTS**

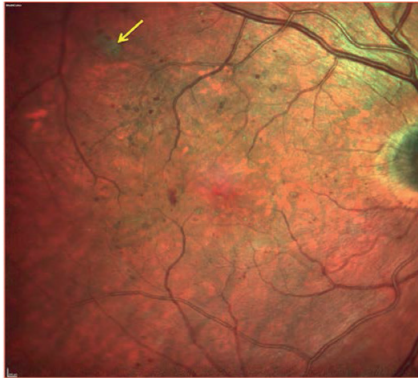
**Cotton-wool spots (CWSs)** are retinal lesions, most commonly seen as manifestations of diabetes mellitus and systemic hypertension. They are also associated with a number of other etiologies including ischemic, embolic, connective tissue, neoplastic, and infectious, but occasionally no underlying cause can be identified.

CWSs are thought to represent axoplasmic debris at the level of retinal ganglion cell axons resulting from **axoplasmic flow interruption** due to vascular or mechanical causes.

At the biomicroscopic examination, CWSs appear as whitish, fluffy retinal patches that eventually fade with time. (**Figure 8**).

**Fluorescein angiography** may reveal a focal impairment of the blood flow,.

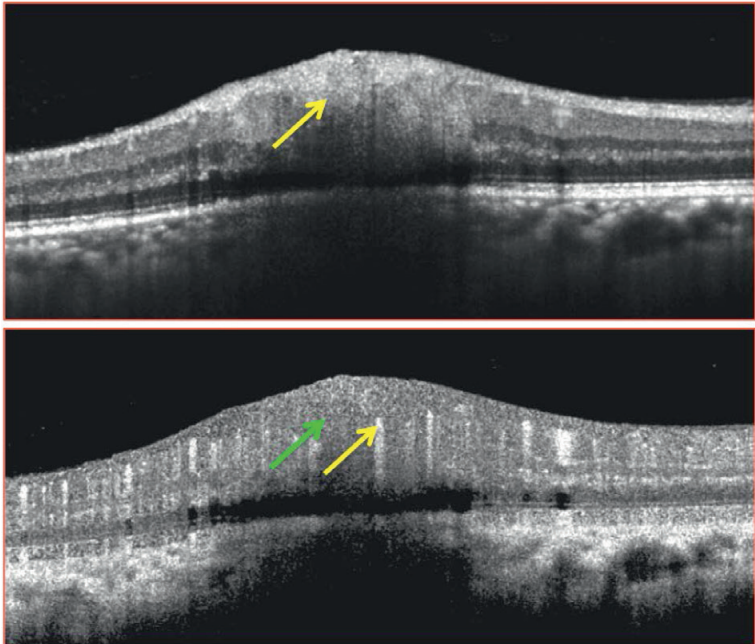
But **OCT findings (Figure 9)** are typically characterized by a marked retinal thickening corresponding to the area of the CWS, confined to the *level of the retinal nerve fiber layer*.



**Figure 8 – Multicolor image showing a cotton wool spot.**  
**(Patient with non-proliferative diabetic retinopathy)**

The multicolor image shows a single cotton wool spot (*yellow arrow*).

Micro aneurysms, dot hemorrhages and hard exudates are also visible in macular and extra-macular area.



**Figure 9 – Cross-sectional OCT of a cotton wool spot**

The structural OCT B-scan (*top image*) reveals a focal thickening of the ganglion cells layer (*yellow arrow*), partially involving also other inner retinal layers.

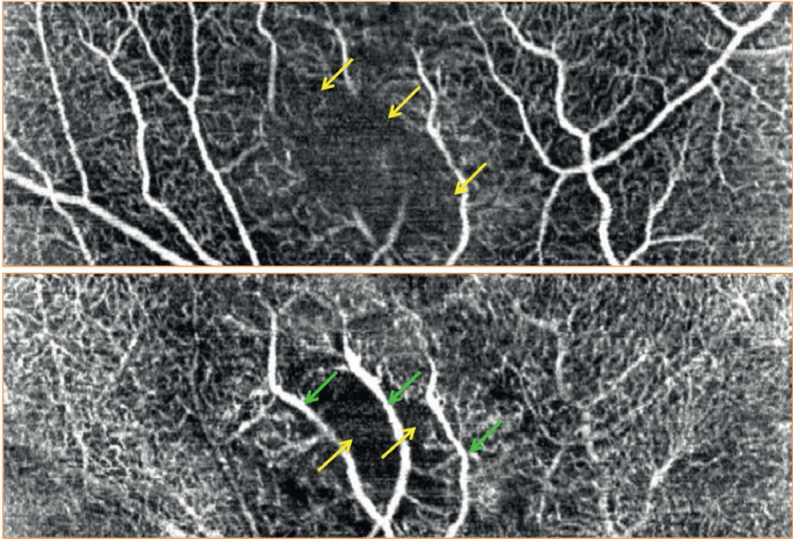
On the corresponding B-scan OCT-A (*bottom image*) no hyper intense signals are visible in the involved area (*green arrow*), while large retinal vessels are displaced deeper in the retina (*yellow arrow*).

This phenomenon is due to focal capillary ischemia, and confirmed on morpho-functional analysis.



**On OCT-Angiography**, a “cotton wool spot” appears as an area of *absence* of decorrelation signal, coming both from the superficial and deep capillary plexus, which may result simultaneously involved. (Figure 10)

Large retinal vessels appear displaced deeper. Moreover these large vessels remain also visible at the level of the DCP because of the absence of decorrelation signal coming from inner vascular layers.<sup>9</sup>



**Figure 10 – En-face OCT-Angiography of a cotton wool spot**

The superficial capillary plexus (*top image*) reveals an area of absence of hyper intense signals coming from perfused vessels (*yellow arrows*).

This area almost shares the same features at the level of the deep capillary plexus (*bottom image*) where there is no evidence of decorrelated structures (*yellow arrows*).

Large retinal vessels are visible at this level due to the inward displacement caused by the thickening of the nerve fiber layer, and also because of the absence of decorrelation signal coming from inner vascular layers.

## 5. DISORGANIZATION OF RETINAL INNER LAYERS (DRIL)

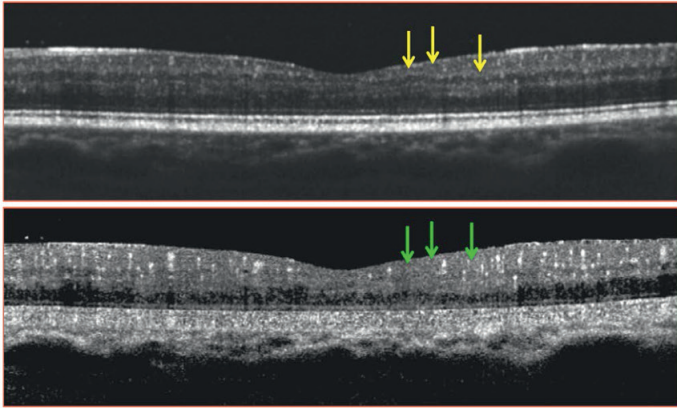
**Disorganization of the retinal inner layers (DRIL)** was defined as the horizontal extent in microns for which any boundaries between the ganglion cell – inner plexiform layer complex, inner nuclear layer, and outer plexiform layer could not be identified.<sup>10</sup> (**Figure 11**).

**DRIL** was found to correlate more consistently with visual acuity in both active and resolved center-involved diabetic macular edema (DME)

DRIL is thought to represent the result of retinal capillary non-perfusion in eyes with diabetic retinopathy.

**OCT-Angiography** may reveal the capillary non-perfusion in areas where a DRIL is present on structural OCT. (**Figures 12-13**).

This finding could be relevant, since DRIL have also been associated with visual function in case of DME and outcome after the resolution of the exudation.

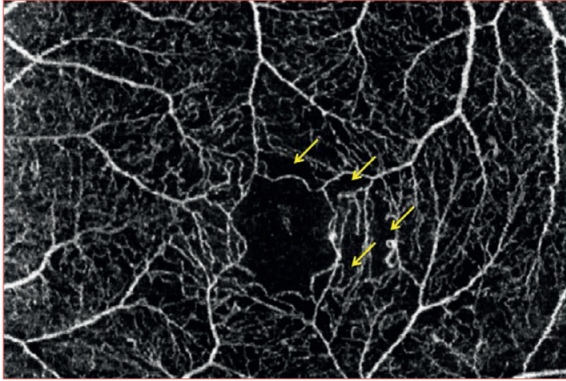


**Figure 11 – Cross-sectional OCT of a disorganization of retinal inner layers (DRIL)**

The structural OCT B-scan (*top image*) reveals a local (*yellow arrows*) change in reflectivity leading to a non-distinguishable ganglion cell – inner plexiform layer complex, focally involving also the inner nuclear layer and outer plexiform layer.

On the corresponding B-scan OCT-A (*bottom image*) no hyper intense signals are visible in the involved area (*green arrows*), probably due to focal capillary non-perfusion.

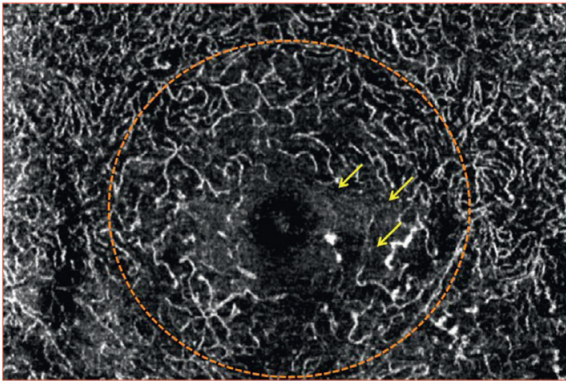
This ischemic process might be at the base of the disorganization of the inner retinal layers, (**DRIL**) as visible on structural OCT.



**Figure 12 – En-face OCT-Angiography of a disorganization of retinal inner layers (DRIL), at the level of the Superficial Capillary Plexus**

The superficial capillary plexus (*top image*) reveals the absence of hyper intense signals coming from perfused vessels (*yellow arrows*) in the area involved by DRIL.

The OCT-A seems to confirm that at the base of the inner retinal impairment, there is a focally compromised retinal vascularity.



**Figure 13 – En-face OCT-Angiography of a disorganization of retinal inner layers (DRIL), at the level of the Deep Capillary Plexus**

The deep capillary plexus (*top image*) is substantially rarefied. (*orange dashed line*)

In this area, and mainly where the DRIL was appreciated (*yellow arrows*), there is no evidence of decorrelated vessels.

The compromised blood flow, probably determining a DRIL, involves not only the superficial but also the deep capillary plexus.

## REFERENCES

1. Scarinci F, Jampol LM, Linsenmeier RA, et al. Association of Diabetic Macular Non-perfusion With Outer Retinal Disruption on Optical Coherence Tomography. *JAMA Ophthalmol.* 2015 Jul 9. doi: 10.1001/jamaophthalmol.2015.2183.
2. Haugh LM, Linsenmeier RA, Goldstick TK. Mathematical models of the spatial distribution of retinal oxygen tension and consumption, including changes upon illumination. *Ann Biomed Eng.* 1990; 18(1):19-36.
3. Yu PK, Balaratnasingam C, Cringle SJ, McAllister IL, Provis J, Yu DY. Microstructure and network organization of the microvasculature in the human macula. *Invest Ophthalmol Vis Sci.* 2010;51(12): 6735-6743.
4. Arend O, Wolf S, Jung F, et al. Retinal microcirculation in patients with diabetes mellitus: dynamic and morphological analysis of perifoveal capillary network. *Br J Ophthalmol.* 1991;75(9):514-518.
5. Mansour AM, Schachat A, Bodiford G, Haymond R. Foveal avascular zone in diabetes mellitus. *Retina.* 1993;13:125-128.
6. Classification of diabetic retinopathy from fluorescein angiograms. ETDRS report number 11. Early Treatment Diabetic Retinopathy Study Research Group. *Ophthalmology* 1991; 98(suppl 5):807-822.
7. Bradley PD, Sim DA, Keane PA, et al. The evaluation of diabetic macular ischemia using optical coherence tomography angiography. *Invest Ophthalmol Vis Sci.* 2016;57:626-631.
8. Ip MS, Domalpally A, Sun JK, et al. Long-term effects of therapy with ranibizumab on diabetic retinopathy severity and baseline risk factors for worsening retinopathy. *Ophthalmology.* 2015;122:367-374.
9. Nemiroff J, Kuehlewein L, Rahimy E, et al. Assessing Deep Retinal Capillary Ischemia in Para-central Acute Middle Maculopathy by Optical Coherence Tomography Angiography. *Am J Ophthalmol.* 2016 Feb;162:121-132.
10. Sun JK, Lin MM, Lammer J, et al. Disorganization of the retinal inner layers as a predictor of visual acuity in eyes with center-involved diabetic macular edema. *JAMA Ophthalmol.* 2014Nov;132(11):1309-16.

**CHAPTER XII**

**OCT-ANGIOGRAPHY  
IN  
DIABETIC PATIENTS:**

**QUANTITATIVE IMAGE ANALYSIS  
AND  
FOLLOW-UP**



## **SECTION I**

### **SPECTRALIS OCT-ANGIOGRAPHY IN DIABETIC MACULOPATHY: QUANTITATIVE IMAGE ANALYSIS**

**Automated quantification of macular diseases** could translate the theoretical usefulness of OCT-Angiography (OCT-A) into “*clinical practice*”.

Therefore an **automated algorithm**, which analyzes OCT-A images, can detect and quantify macular vascular impairment in diabetic retinopathy.

**Recent studies** have focused their attention on different tentative approaches in quantifying OCT-A images. These methods, although providing interesting findings, are not or partially automated, and this might be a potential limit of their actual usefulness.

**Hwang et al.**<sup>1</sup> described a method for quantifying Macular Capillary Non Perfusion, Vessel Density, Total Macular Avascular Area and Foveal Avascular Zone (FAZ) in diabetic patients with an automated analysis, based on Split-Spectrum Amplitude Decorrelation Angiography (SSADA).

These authors used a commercially available OCT and the macular angiography scan was performed on a 6×6 mm area.

They reported that para-foveal and perifoveal vessel densities were reduced in patients with diabetes compared with normal controls. Moreover the *FAZ area* and *Total Avascular Area* were greater in eyes with Diabetic Maculopathy.

**In a recent study, Agemy et al.**<sup>2</sup> demonstrated a statistically significant difference in terms of *capillary perfusion density* **between** the superficial and the deep capillary plexus.

Similar findings were also documented in a group of 52 healthy Indian subjects who underwent SSADA OCT-Angiography followed by **local fractal dimension method** to quantify Vessel Density and Foveal Avascular Zone (FAZ).<sup>3</sup>

This difference was explained with the potential higher *metabolic demand* of the deeper retinal layers and with the absence of larger vessels at the level of the deep plexus.

The Authors have recently developed an Automated, Custom-built Software (**AngiOC-Tool™**), able to provide a quantitative assessment of vascular perfusion in macular area.<sup>4</sup>

This approach has been *already validated on healthy subjects*<sup>4</sup>, and it is actually ongoing its application in case of different retinal vascular diseases.

**On OCT-A images**, vessels detection is both based on the exact identification of each decorrelated pixel and on the trajectory taken by contiguous decorrelated pixels.

This process allows:

- to render the **vessel thickness** and
- to obtain, with a vector representation,
- the **shape** of perfused structures.

The **FAZ** is automatically detected in a similar way by outlining a contour along the vascular

rim of the *Perifoveal capillary arcade* in case of SCP or by connecting decorrelated pixels at a border of a *central non-flow area* in case of DCP.

In case of errors in defining the FAZ, a manual correction of the borders is also allowed.

The image analysis provides **several quantitative parameters**:

- FAZ metrics (perimeter, surface, major axis, orientation),
- Total Vascular Surface,
- Total Avascular Surface.

Quantitative data may be achieved within a circular **area of 2000  $\mu\text{m}$  diameter**, centered on the FAZ.

The evaluation, performed on a 2-mm-diameter area, is based on the diameter of the **physiologic fovea**, which is 1.85 mm, and on the relevance of this specific area for the visual function.

This approach also reduces the effects of artifacts at the edge of the C-scan images.



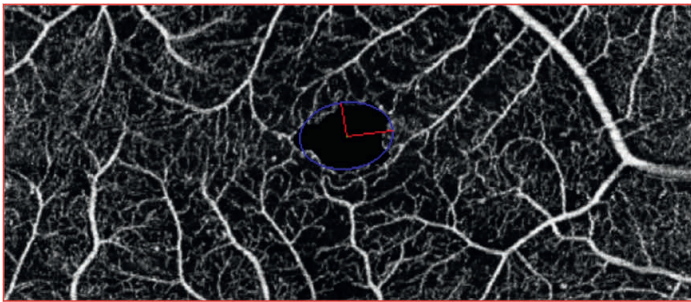
## QUANTITATIVE IMAGE ANALYSIS

### - STAGE ONE: Foveal Avascular Zone Metrics

The first stage of the analysis includes the **definition of the foveal avascular zone (FAZ) borders**. This is obtained by an automated outlining process, which leads to the exact compu-

tion of the FAZ perimeter and surface.

The major and minor axis and their orientation are also computed.



**Figure 1: FOVEAL AVASCULAR ZONE METRICS**

The foveal avascular zone (FAZ) is automatically detected

- in case of SCP: by outlining a contour along the vascular rim of the perifoveal capillary arcade
- in case of DCP: by connecting decorrelated pixels at a border of a central non-flow area.

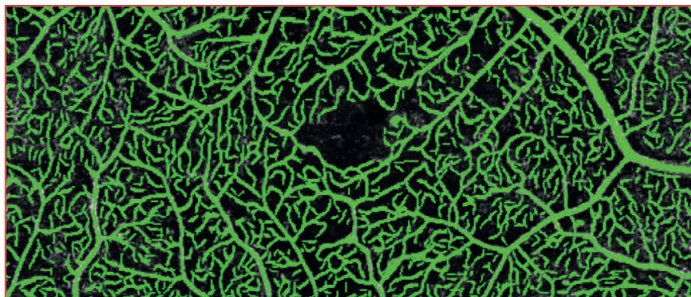
FAZ perimeter, axes (*red lines*), surface (equivalent circular surface, *blue line*) are computed.

### - STAGE TWO: Total Vascular Surface Assessment

The second stage of the automated process is the **identification of all the decorrelated signals** (hyper intense structures), due to actively perfused vessels.

This process allows the complete recognition of the entire perfused vascular tree imaged in the scanned area. Both **vessel's trajectory and thickness** are considered.

## TOTAL VASCULAR SURFACE ASSESSMENT



**Figure 2: Total Vascular Surface Assessment.**

Vessels' detection was both based on the exact identification of each decorrelated pixel and on the trajectory taken by contiguous decorrelated pixels.

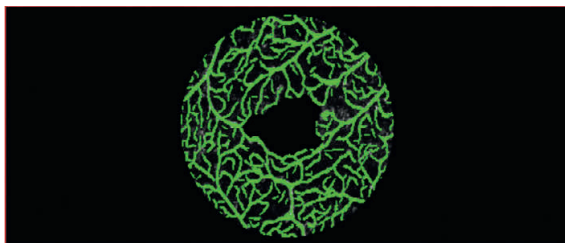
This process allowed to render the **vessel thickness** and to obtain, with a vector representation, the **shape of perfused structures**.

### - STAGE THREE: Quantitative Analysis On Central Area

The final stage provides the **quantification of the different parameters** identified in the two previous steps. The *FAZ perimeter, surface, major and minor axes (and orientation), vascular and avascular surfaces* are calculated.

All the data are referred to the central 2 mm-diameter circular area.

This approach was chosen in order to reduce potential artifacts and because of the **relevance of this area in terms of visual function**



**Figure 3: QUANTITATIVE ANALYSIS ON CENTRAL AREA**

Quantitative data are achieved within a circular **area of 2000  $\mu\text{m}$  diameter**, centered on the FAZ, in order to reduce potential artifacts and because of the relevance of this area in terms of visual function

## PRELIMINARY QUANTITATIVE RESULTS ON DIABETIC MACULOPATHY

Preliminary results in an unpublished retrospective case series of 50 eyes of 34 patients with Diabetic Maculopathy showed that in the superficial capillary plexus, non-perfused areas were present in all DM eyes.

Conversely, in the deep capillary plexus, non-perfused areas were detected in a lower number of cases. No significant differences were found in number of microaneurysms between the two

capillary plexa. Capillary density values were significantly lower in nearly all layers of DM patients compared with healthy subjects.

OCT-A is a useful technology for detecting DM abnormalities both in the superficial and deep capillary plexa. The fully automated quantitative retinal vascular analysis may offer an objective method for monitoring disease progression and the functional response to treatment.

## REFERENCES

1. Hwang TS, Gao SS, Liu L, et al. Automated Quantification of Capillary Non-perfusion Using Optical Coherence Tomography Angiography in Diabetic Retinopathy. *JAMA Ophthalmol.* 2016; 21:1-7.
2. Agemy SA, Scripsema NK, Shah CM, et al. Retinal vascular perfusion density mapping using optical coherence tomography angiography in normals and diabetic retinopathy patients. *Retina.* 2015; 35 (11): 2353-63.
3. Gadde SGK, Anegondi N, Bhanushali D, et al. Quantification of vessel density in retinal optical coherence tomography angiography images using local fractal dimension. *Invest Ophthalmol Vis Sci.* 2016; 57: 246-252.
4. Lupidi M, Coscas F, Cagini C, et al. Automated Quantitative Analysis of Retinal Microvasculature In Normal Eyes On Optical Coherence Tomography- Angiography. *Am J Ophthalmol.* 2016 Jun 10. doi: 10.1016/j.ajo.2016.06.008

## **SECTION II**

### **SPECTRALIS OCT-ANGIOGRAPHY IN DIABETIC MACULOPATHY**

#### **FOLLOW-UP AFTER TREATMENT**

**Diabetes mellitus (DM)** is a global epidemic with significant morbidity. Although *Diabetic Retinopathy (DR)* affects 1 in 3 people with DM, the leading cause of vision loss in this population is *Diabetic Macular Edema (DME)*, which affects approximately 6.8% of the diabetic population.<sup>1</sup>

Despite a substantial improvement in diagnostic screening techniques and the proven efficacy of laser treatment in preventing visual loss, diabetic retinopathy (DR) remains the **leading cause of legal blindness** in working age populations of industrialized countries.

**Diabetic Macular Edema (DME) or capillary non-perfusion** may directly impair central vision. DME represents a spectrum of retinopathy signs, characterized by edema and thickening of the central macula and surrounding non-central macula that are not explained by the presence of an Epiretinal Membrane (ERM) at the macula.

**These symptoms** are typically confirmed by slit-lamp biomicroscopy and, increasingly, with the aid of Optical Coherence Tomography (OCT).

**The natural history of DM** is characterized by a slow progression of retinal thickening until

the center of the macula is involved, causing visual acuity deterioration.

Partial regression of DM may be observed, usually secondary to improvement in systemic risk factors, such as glycemic control, hypertension, or hypercholesterolemia.

If untreated, 29% of eyes with DME and foveal involvement experience moderate visual loss (doubling of the visual angle) after 3 years.

Spontaneous visual recovery is also unusual, with improvement of at least 3 Early Treatment Diabetic Retinopathy Study (ETDRS) lines occurring in 5% of cases

For nearly 30 years, focal/grid laser photocoagulation has been the mainstay of treatment for clinically significant DME (CSME).<sup>2</sup>

It has been reported that 3 years after initial grid treatment, visual acuity improved in 14.5% of patients with DME, did not change in 60.9%, and decreased in 24.6%<sup>3</sup>

However, there have been **substantial advances** in our understanding of DME since this method was first used.

First, epidemiologic data indicate that DME, more than DR severity, is the most common cause of vision loss for patients.

Moreover, there is now better understanding that *risk factors for DME* may be different from those for DR, highlighting the importance of systemic management being targeted at DME.

Therefore the improved knowledge of the patho-physiology of DME has enabled the **development of alternative therapies**.

In recent years, the *intravitreal administration of steroids* has provided promising results for the treatment of DME due to their anti-inflammatory and anti-permeability properties<sup>4</sup> and mainly the Anti-Vascular Endothelial Growth Factor (anti-VEGF) treatments<sup>5-9</sup>

The development of modern imaging techniques, such as OCT, has allowed assessment of early DME, including sub clinical DME.

OCT imaging helps in immediately estimating intraretinal changes, pinpointing the eventual existence of infra-clinical foveolar detachment, assessing the vitreo-retinal juncture, and precisely measuring the thickened retina<sup>10</sup>.

OCT is particularly useful in detecting serous retinal detachment, a feature combined with macular edema but not easily seen on biomicroscopy<sup>11-12</sup>.

OCT seems also particularly relevant to analyze the *vitreomacular relationship*.<sup>13-14</sup>

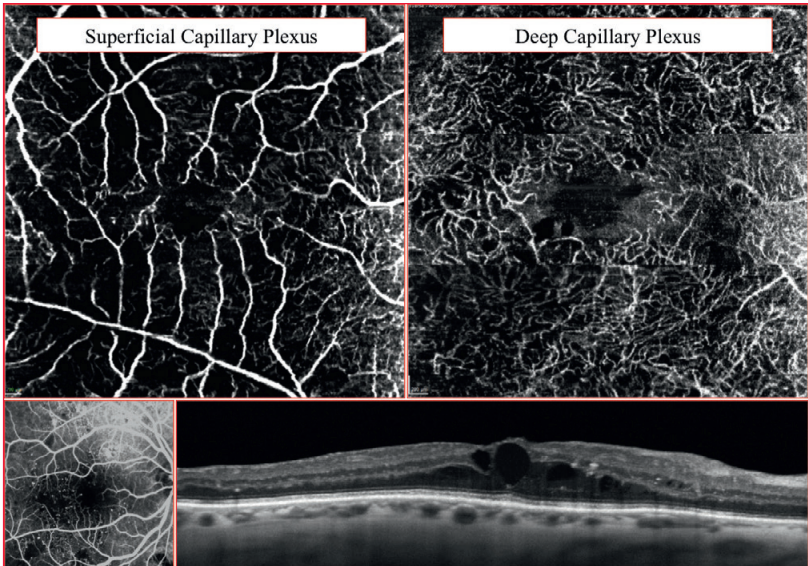
The recent introduction of **OCT-Angiography** (OCT-A) might allow a non-invasive functional assessment of diabetic maculopathy.

This achievement, coupled with structural OCT could result in a comprehensive morpho-functional examination of the status of the disease and its response to treatment.

**Here follow some cases of diabetic maculopathy** both assessed with OCT-A and structural OCT, before and after anti-VEGF and/or steroid implants treatment.

This analysis is performed in order to evaluate the **potential outcome** of the intravitreal treatment on intraretinal (or sub-retinal) exudation as well as on vascular perfusion but not based on the indications nor the results of different treatments.

**CASE I: Diabetic Maculopathy BEFORE  
single intravitreal injection of VEGF-Trap**



**Figure 1 - Optical Coherence Tomography Angiography (OCT-A- $15 \times 10^\circ$ ) C-scan and structural OCT of a 56 years-old patient with Diabetic Maculopathy before a single intravitreal injection of VEGF-Trap.**

The Superficial Capillary Plexus (SCP; *top left image*) shows large areas of flow absence in a diffusely rarefied vascular network.

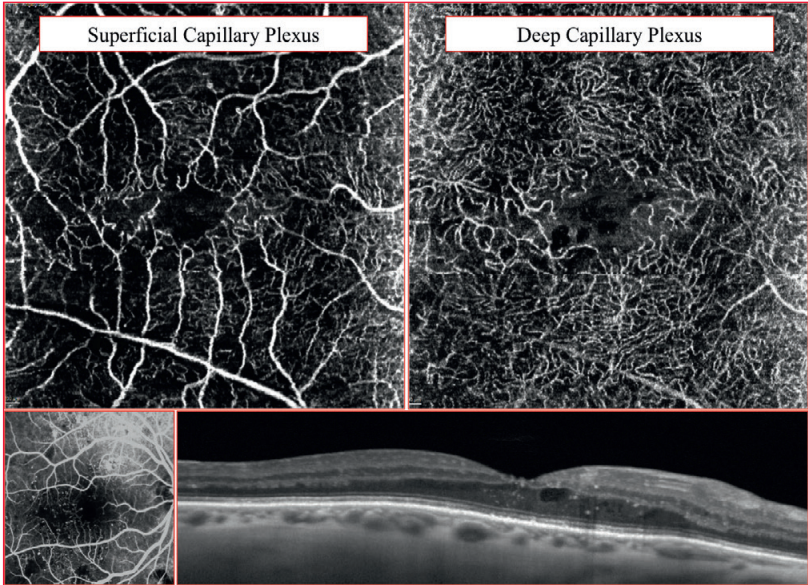
The Deep Capillary Plexus (DCP; *top right image*) appears impaired as well, with focal vascular dilations and areas of absence of signal coming from decorrelated structures.

These **flow-void areas** are generally related to severe stages of non-proliferative diabetic retinopathy or proliferative diabetic retinopathy.

Reference fluorescein angiography (*bottom left image*). Structural OCT (*bottom image*) shows the presence diabetic macular edema.

**Cystoid spaces** mainly involve the inner and outer nuclear layers. Some hyper reflective clumps are also appreciable.

**CASE I: Diabetic Maculopathy AFTER  
single intravitreal injection of VEGF-Trap**



**Figure 2 - Optical Coherence Tomography Angiography (OCT-A) C-scan and structural OCT of a 56 years-old patient with Diabetic Maculopathy 1 month after a single intravitreal injection of VEGF-Trap**

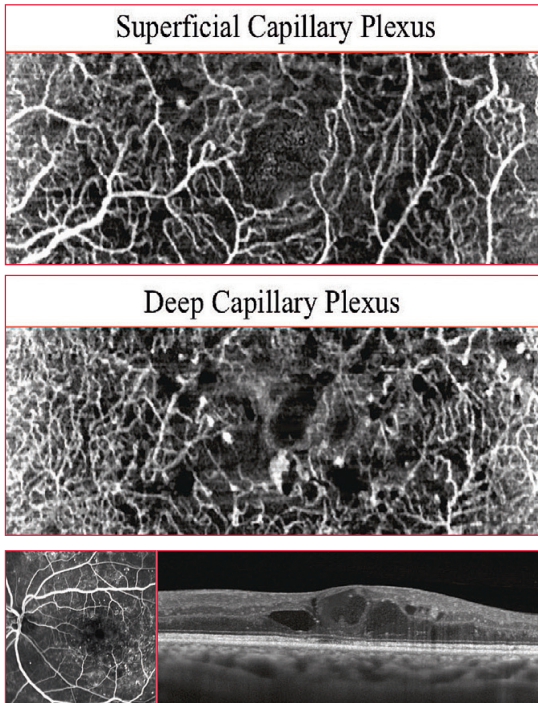
The Superficial Capillary Plexus (SCP; *top left image*) appears less rarefied, due to substantial reduction of the capillary dropout.

The Deep Capillary Plexus (DCP; *top right image*) although showing severe impairment of vascular architecture in perifoveal area, seems slightly improved.

On OCT-A, a more homogeneous signal is coming from the perfused structures, either in SCP or in DCP

Structural OCT confirm an evident decrease of intraretinal exudation. Some residual cystoid spaces are seen, but foveal depression is almost maintained.

**CASE II: Diabetic Maculopathy  
before dexamethasone intravitreal implant**



**Figure 3 - Optical Coherence Tomography Angiography (OCT-A-15 x 5°) C-scan and structural OCT of a 72 years-old patient with Diabetic Maculopathy before dexamethasone intravitreal implant**

The Superficial Capillary Plexus (SCP; *top image*) shows micro aneurysms, connecting vessels and very limited areas of flow absence in a substantially preserved vascular network.

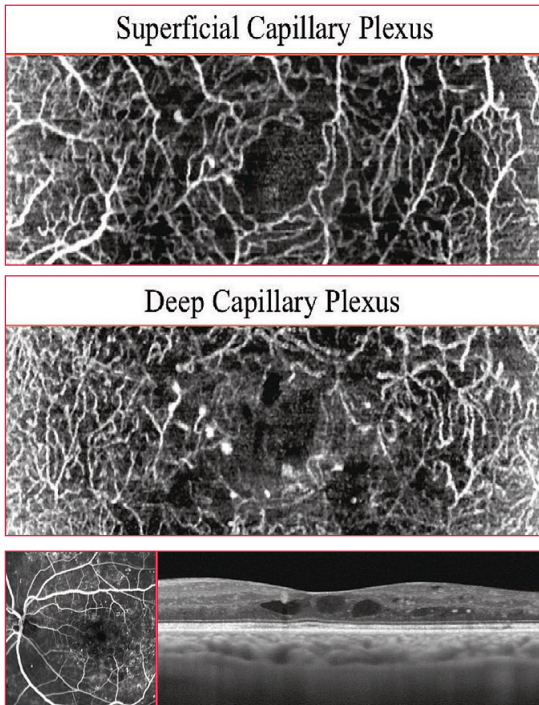
The Deep Capillary Plexus (DCP; *middle image*) appears more severely impaired, with focal vascular dilations and micro aneurysms.

Areas of absence of signal are due to *cystoid spaces (black)* and non-perfused areas (*grayish*).

Reference fluorescein angiography (*bottom left image*). Structural OCT (*bottom right image*) highlights the presence **diabetic macular edema**.



**CASE II: Diabetic Maculopathy**  
**One month after dexamethasone intravitreal implant**



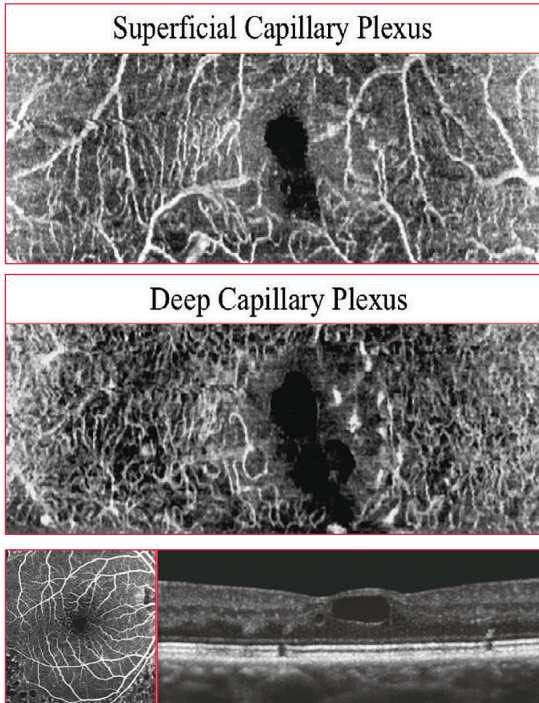
**Figure 4 - Optical Coherence Tomography Angiography (OCT-A) C-scan and structural OCT of a 72 years-old patient with Diabetic Maculopathy 1 month after dexamethasone intravitreal implant**

The Superficial Capillary Plexus (SCP; *top image*) does not show significant variations in terms of decorrelated structures.

The Deep Capillary Plexus (DCP; *middle image*) seems slightly improved, mainly due to the partial regression of intraretinal exudation. Microaneurysms are still visible.

Reference fluorescein angiography (*bottom left image*). Structural OCT (*bottom right image*) shows an evident decrease of intraretinal exudation. A few cystoid spaces are still present, **although reduced, in foveal area.**

**CASE III: Diabetic Maculopathy**  
**before intravitreal injection of anti-VEGF (Ranibizumab\*)**



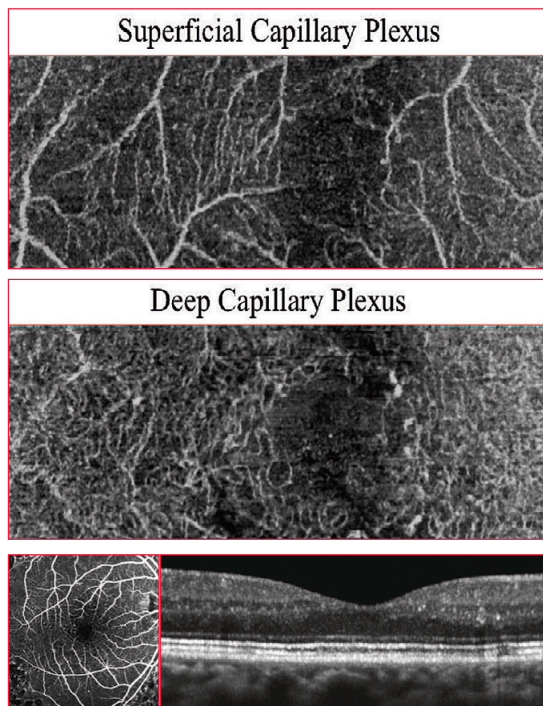
**Figure 5 - Optical Coherence Tomography Angiography (OCT-A--15 x 5°) C-scan and structural OCT of a 66 years-old patient with Diabetic Maculopathy before 3 intravitreal injections of anti-VEGF (Ranibizumab\*)**

The Superficial Capillary Plexus (SCP; *top image*) demonstrates the presence of focal areas of flow absence probably due to non-perfused areas and a central dark (black) area in correspondence of the foveal avascular zone which might be referred to a large cystoid space.

The Deep Capillary Plexus (DCP; *middle image*) shows similar findings, with micro aneurysms in perifoveal area and the same central dark area, larger than at the level SCP, probably due to the confluence of several cystoid spaces.

Reference fluorescein angiography (*bottom left image*). Structural OCT (*right image*) shows the presence diabetic macular edema: a **large cystoid space** determines the loss of foveal depression.

**CASE III: Diabetic Maculopathy  
after 3 (monthly) intravitreal injections of anti-VEGF (Ranibizumab\*)**



**Figure 6 - Optical Coherence Tomography Angiography (OCT-A) C-scan and structural OCT of a 66 years-old patient with Diabetic Maculopathy after 3 (monthly regimen) intravitreal injections of anti-VEGF (Ranibizumab\*)**

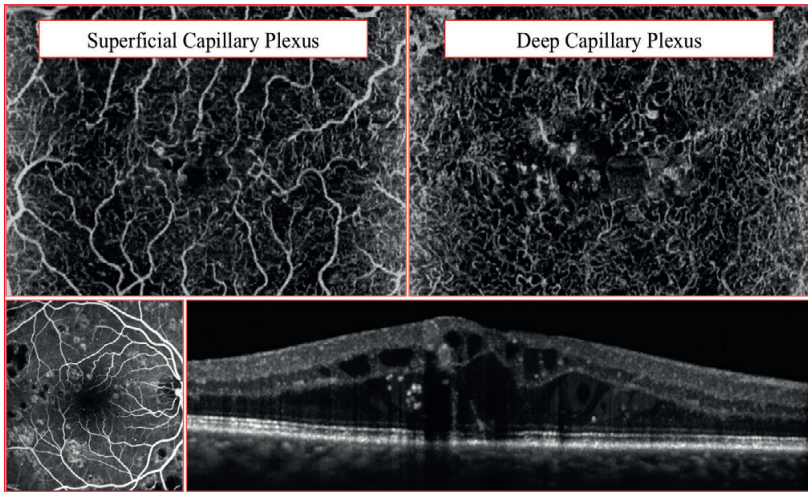
After the loading phase (3 IV injections)

The Superficial Capillary Plexus (SCP; *top image*) and the Deep Capillary Plexus (DCP; *middle image*) appear well preserved:

Flow void areas are limited and micro aneurysms or focal vessels dilations are less numerous.

Reference fluorescein angiography (*bottom left image*). Structural OCT (*bottom right image*) shows the complete **regression of intraretinal fluid**.

**CASE IV: Diabetic Maculopathy  
before a single intravitreal injection of VEGF-Trap**



**Figure 7 - Optical Coherence Tomography Angiography (OCT-A-- $15 \times 10^\circ$ ) C-scan and structural OCT of a 74 years-old patient with Diabetic Maculopathy before a single intravitreal injection of VEGF-Trap**

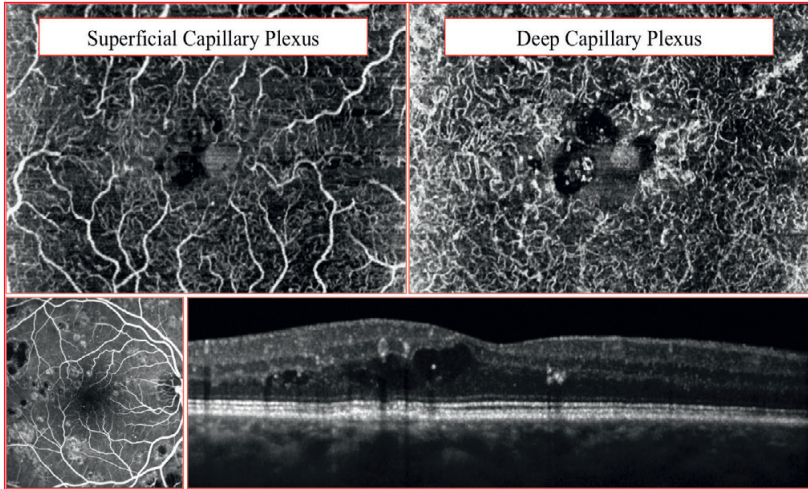
The Superficial Capillary Plexus (SCP; *top left image*) shows a substantially impaired perifoveal vascular arcade, with several interruptions, partially due to the presence of intraretinal exudation. Connecting vessels and microaneurysms are also visible.

The Deep Capillary Plexus (DCP; *top right image*) appears impaired as well, with focal vascular dilations and areas of absence of signal coming from decorrelated structures.

Reference fluorescein angiography (*bottom left image*). Structural OCT (*bottom right image*) shows the presence **diabetic macular edema**: the macular profile is thickened, numerous cystoid spaces (and intraretinal clumps) both involve inner and outer retinal layers.

The foveal depression is almost disappeared and a cross-section of a micro aneurysm is also visible.

**CASE IV: Diabetic Maculopathy  
after a single intravitreal injection of VEGF-Trap**



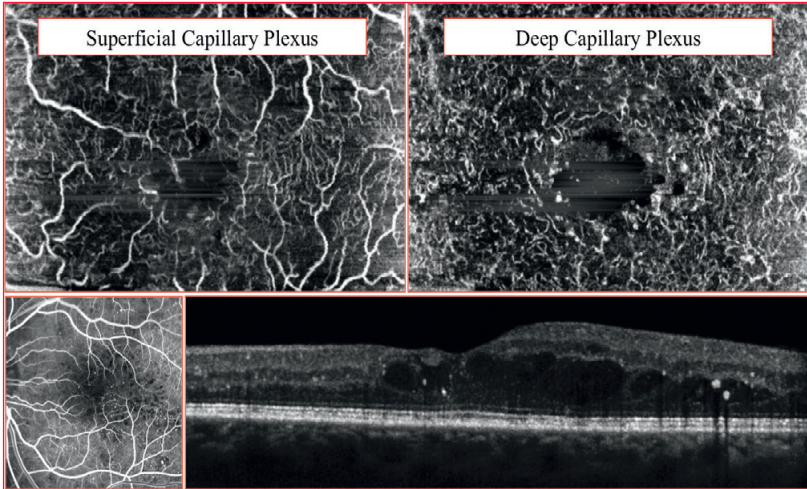
**Figure 8 - Optical Coherence Tomography Angiography (OCT-A) C-scan and structural OCT of a 74 years-old patient with Diabetic Maculopathy 1 month after a single intravitreal injection of VEGF-Trap**

Both the Superficial Capillary Plexus (SCP; *top left image*) and the Deep Capillary Plexus (DCP; *top right image*) appear almost unchanged.

Vascular dilations, connecting vessels and micro aneurysm are still visible, as well as the intraretinal exudation.

Reference fluorescein angiography (*bottom left image*). Structural OCT (*bottom right image*) shows a thinned macular profile, due to the **decrease of intraretinal fluid**.

**CASE V: Diabetic Maculopathy  
before dexamethasone intravitreal implant**



**Figure 9 - Optical Coherence Tomography Angiography (OCT-A--- $15 \times 10^\circ$ ) C-scan and structural OCT of a 83 years-old patient with Diabetic Maculopathy before dexamethasone intravitreal implant**

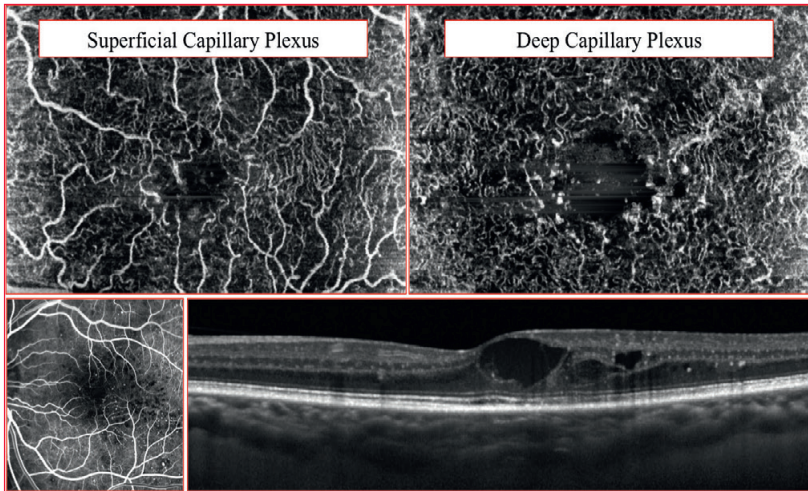
The Superficial Capillary Plexus (SCP; *top left image*) shows tiny areas of flow absence both in perifoveal area and at the borders of the scanned region.

The Deep Capillary Plexus (DCP; *top right image*) appears severely impaired with a loss of the common architecture (capillary vortex are not detectable). Microaneurysms are clearly visible.

Reference fluorescein angiography (*bottom left image*). Structural OCT (*bottom right image*) shows the presence diabetic macular edema: **cystoid spaces** mainly involve the outer nuclear layers.

Some hyper reflective clumps are also appreciable.

**CASE V: Diabetic Maculopathy  
after dexamethasone intravitreal implant**



**Figure 10 - Optical Coherence Tomography Angiography (OCT-A) C-scan and structural OCT of a 83 years-old patient with Diabetic Maculopathy 4 months after dexamethasone intravitreal implant**

The Superficial Capillary Plexus (SCP; *top left image*) shows areas capillary dropout, although reduced when compared with the previous examination.

The Deep Capillary Plexus (DCP; *top right image*) although showing severe impairment of vascular architecture in perifoveal area seems slightly improved, with a more homogeneous signal coming from the perfused structures.

Reference fluorescein angiography (*bottom left image*). Structural OCT (*bottom right image*) shows the persistence of intraretinal exudation, with large intraretinal hyporefective cavities: this might be due to the **confluence of smaller cystoid spaces** in a substantially compromised tissue.

## REFERENCES

1. Yau JWY, Rogers SL, Kawasaki R, et al. For the Meta-Analysis for Eye Disease (META-EYE) Study Group. Global prevalence and major risk factors of diabetic retinopathy. *Diabetes Care* 2012;35(3):1-9.
2. Early Treatment Diabetic Retinopathy Study Research Group. Photocoagulation for diabetic macular edema. ETDRS report number 1. *Arch Ophthalmol* 1985;103(12):1796-1806.
3. Lee CM, Olk RJ. Modified grid laser photocoagulation for diffuse diabetic macular edema. Long-term visual results. *Ophthalmology* 1991;98:1594-602
4. Boyer DS, Yoon YH, Belfort R Jr, Bandello F, Maturi RK, Augustin AJ, Li XY, Cui H, Hashad Y, Whitcup SM; Ozurdex MEAD Study Group. Ophthalmology. Three-year, randomized, sham-controlled trial of dexamethasone intravitreal implant in patients with diabetic macular edema. 2014 Oct;121(10):1904-14.
5. Bhagat N, Grigorian RA, Tutela A, Zarbin MA. Diabetic macular edema: pathogenesis and treatment. *Surv Ophthalmol* 2009;54(1):1-32.
6. Bressler NM, Miller KM, Beck RW, et al; for the Diabetic Retinopathy Clinical Research Network. Observational study of subclinical diabetic macular edema. *Eye (Lond)* 2012; 26(6):833-840.
7. Mitchell P, Bandello F, Schmidt-Erfurth U, et al; for the RESTORE study group. The RESTORE study: ranibizumab monotherapy or combined with laser versus laser monotherapy for diabetic macular edema. *Ophthalmology* 2011;118(4):615-625
8. Shah SM NQ, Tatlipinar S, et al. One-year results of the READ study: ranibizumab for edema of the macula in diabetes. In: *Retina Society Annual Meeting. Cape Town; 2006.*
9. Korobelnik JF, Do DV, Schmidt-Erfurth U, Boyer DS, Holz FG, Heier JS, Midena E, Kaiser PK, Terasaki H, Marcus DM, Nguyen QD, Jaffe GJ, Slakter JS, Simader C, Soo Y, Schmelter T, Yancopoulos GD, Stahl N, Vitti R, Berliner AJ, Zeitz O, Metzigg C, Brown DM. Intravitreal aflibercept for diabetic macular edema. *Ophthalmology*. 2014 Nov;121(11):2247-
10. Massin P, Girach A, Erginay A, Gaudric A. Optical coherence tomography: a key to the future management of patients with diabetic macular oedema. *Acta Ophthalmol Scand* 2006;84:466-74.
11. Ozdemir H, Karacorlu M, Karacorlu S. Serous macular detachment in diabetic cystoid macular oedema. *Acta ophthalmologica Scandinavica* 2005;83:63-66.
12. Catier A, Tadayoni R, Paques M, et al. Optical coherence tomography characterization of macular edema according to various etiology. *Am J Ophthalmol*, 2005, 140: 200-6.
13. Gaucher D, Tadayoni R, Erginay A, et al. Optical coherence tomography assessment of the vitreoretinal relationship in diabetic macular edema. *Am J Ophthalmol*, 2005. 139: 807-813.
14. Bandello F, Battaglia-Parodi M, Lanzetta P, Loewenstein A, Massin P, Menchini F : Diabetic Macular Edema in *Coscas G (Ed): Macular Edema. Dev Ophthalmol. Basel, Karger, 2010, vol 47, pp 73-110*