


## Glaucoma Toolkit



**SPECTRALIS®**

**HEIDELBERG  
ENGINEERING**

## Table of Contents

### Introduction

3 What is Glaucoma?

3 SPECTRALIS Toolkit for Glaucoma Assessment

### Considerations

4 Anatomic Positioning

5 Confounding Factors

### Parameters

6 Optic Nerve Head (ONH)

8 Retinal Nerve Fiber Layer (RNFL)

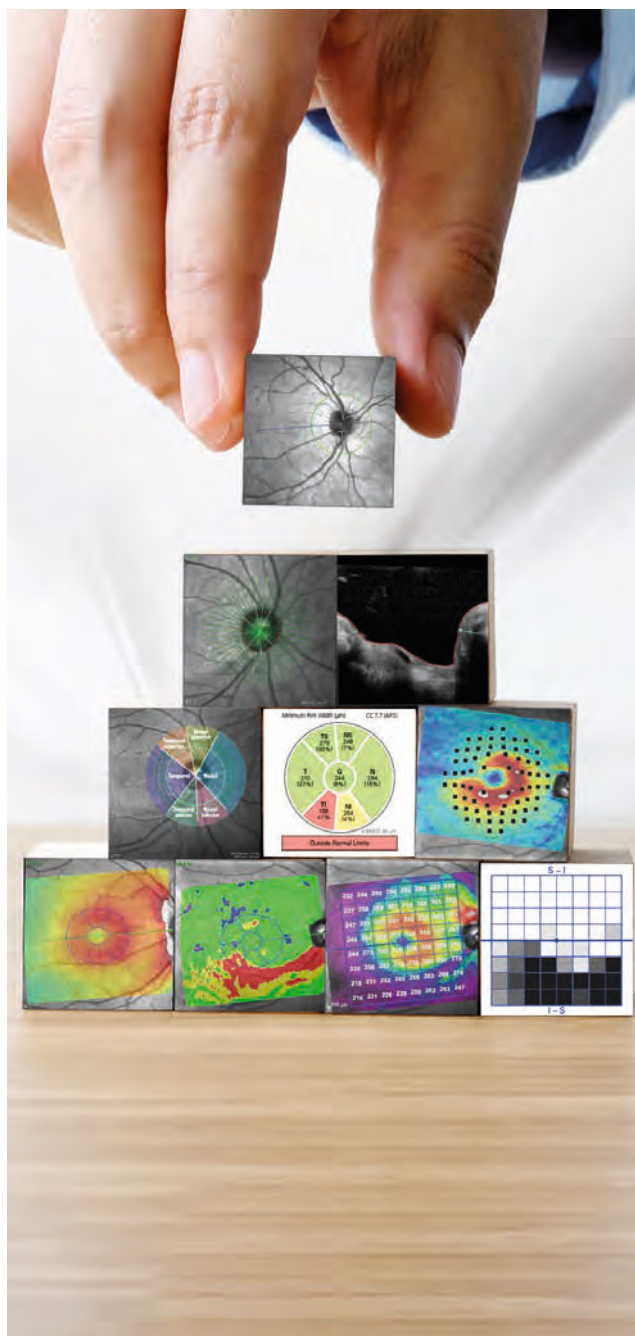
10 Structural Assessment of the Macula\*

14 Posterior Pole Asymmetry

15 The Hood Glaucoma Report

18 Progression

19 Summary



## Key



= right eye



= optic nerve head scan



= left eye



= macula scan

## Introduction

### What is Glaucoma?

Glaucoma is a group of progressive optic neuropathies characterized by degeneration of retinal ganglion cells (RGCs) and progressive thinning of the neuroretinal rim and retinal nerve fiber layer (RNFL). Glaucomatous RGC loss results in characteristic visual field (VF) defects, which are usually arcuate in nature.

While the disease progression is treatable, the visual impairment caused by glaucoma is irreversible. Early detection of damage and precise monitoring of progressive RGC loss is essential in assisting the clinician to confirm a glaucoma diagnosis and prevent additional glaucomatous vision loss.

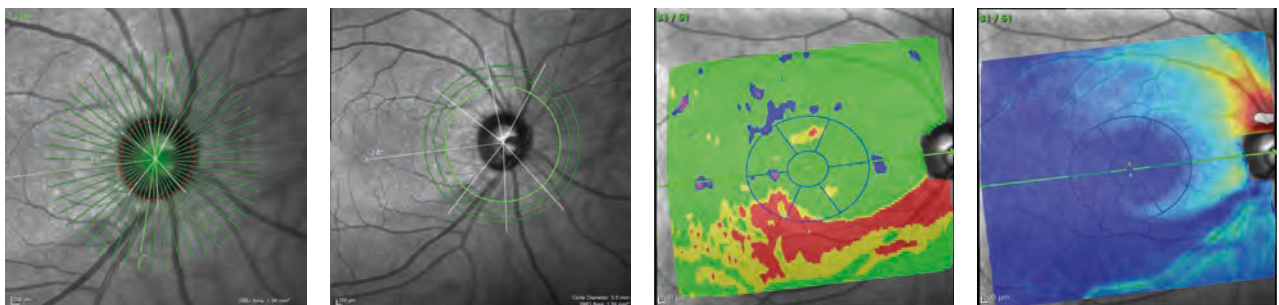
### SPECTRALIS Toolkit for Glaucoma Assessment

OCT can provide detailed information about the anatomical structure of the eye and an objective measurement of progressive change. OCT complements the subjective, qualitative eye examination with objective, quantitative results.

It is extremely useful to integrate OCT into glaucoma assessment, alongside the clinical examination, consideration of the patient's history and symptoms, visual field results, and arsenal of other diagnostic tests.

The SPECTRALIS® Glaucoma Module Premium Edition (GMPE) provides you with a comprehensive suite of parameters and the reproducibility for glaucoma diagnosis and monitoring that allows you to evaluate glaucoma patients in your own individualized way.

The following images and data were generated using the SPECTRALIS GMPE.



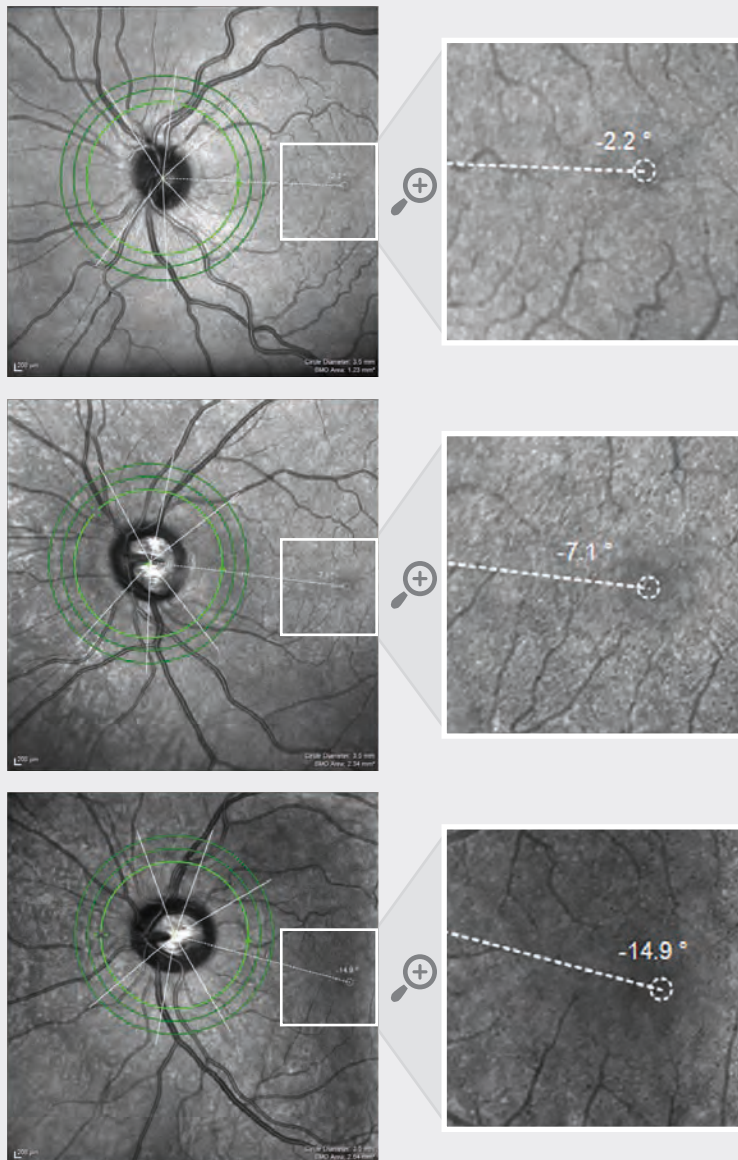
Case study credit: Donald Hood, PhD, and Robert Ritch, MD.



## Considerations

### Anatomic Positioning

The SPECTRALIS GMPE Anatomic Positioning System (APS) identifies two fixed landmarks – the center of Bruch’s membrane opening (BMO) and the fovea – in order to place and orient glaucoma scans according to the correct anatomic location in each individual eye. This unique, semi-automated technology increases the precision and accuracy of the results by ensuring that all glaucoma scans are anatomically aligned according to the individual configuration of axons in each eye. This enhances the accuracy in the comparison to the reference database (RDB). The software then ensures that each eye’s results are compared to the RDB while accounting for potential anatomical differences. This personalized anatomic alignment provides diagnostic images and data that you can rely on.



The center of the ONH is anatomically defined as the center of the BMO using OCT imaging.

The range of angles for the fovea to the center of the BMO axis (BMOC) is large across a population and could theoretically vary by as much as 35° between eyes of different individuals or between two eyes of the same individual.<sup>1</sup>

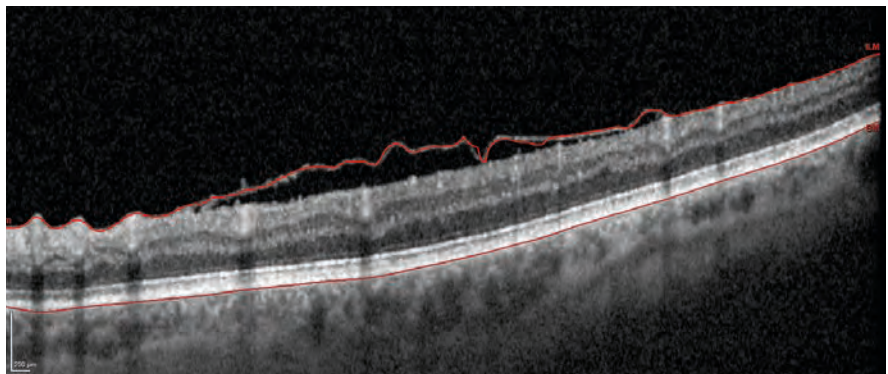
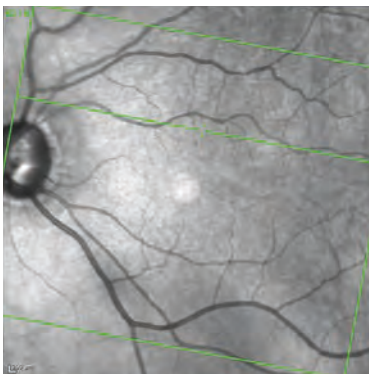
In these three examples, the fovea is -2.2°, -7.1° and -14.9° (top to bottom) below the BMOC.

The 6-sector Garway-Heath classification, represented by the white lines through the ONH, is automatically positioned according to the angle.

## Confounding Factors

The SPECTRALIS GMPE RNFL and neuroretinal rim parameters are compared to an age- and BMO- area adjusted RDB, with the results displayed in color-coded graphs that indicate if the measurements are within normal limits (green), borderline (yellow), or outside of normal limits (red).

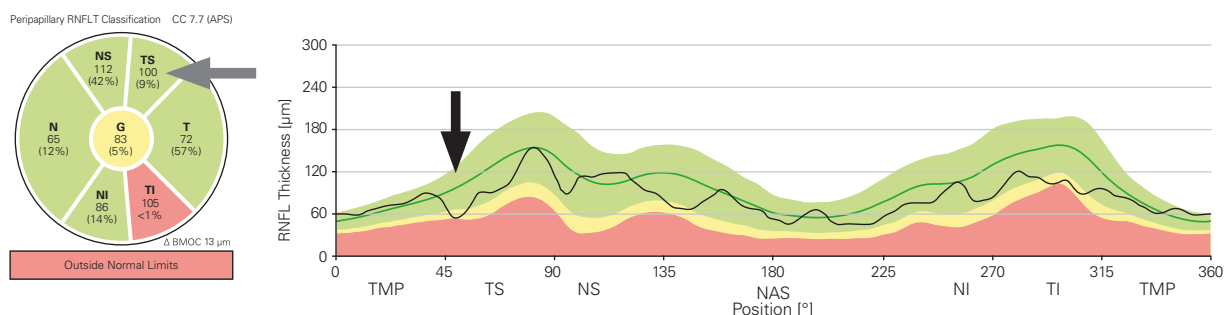
Be aware that this color-coding can be affected by several variables, such as comorbidities and segmentation errors. Checking that the retinal layers have been segmented correctly and reviewing the OCT images for signs of confounding pathology will help identify and exclude potentially misleading variables during your glaucoma analysis.



Example of a segmentation error due to confounding pathology (epiretinal membrane).

Color classification may also be affected if the patient's age, BMO area and refractive error are beyond the limits of the RDB. You can find further information about the RDB of SPECTRALIS in the GMPE User Manual.

Focal defects may not be sufficiently large enough in magnitude to trigger borderline and/or outside of normal limits sectors on the BMO-MRW and RNFL classification charts. It is, therefore, advantageous to analyze the classification charts and thickness profiles carefully, as you may notice that while a sector is triggered as green in the classification chart, defects can be identified on the thickness profile. Interrogation of all the OCT parameters, rather than reliance solely on color-coded classifications, will help you to confidently and accurately use the OCT parameters as an aid in your diagnosis of glaucoma.




Example of a temporal superior focal defect visible on the RNFL profile (black arrow). The corresponding sector (grey arrow) on the classification chart is in the 9th percentile, but has not been triggered as outside of normal limits on the classification chart.

## Parameters



### Optic Nerve Head



The minimum distance between Bruch's membrane opening and the internal limiting membrane around the optic nerve head – referred to as Bruch's Membrane Opening – Minimum Rim Width (BMO-MRW) – provides you with the true anatomic optic nerve head (ONH) boundary and the most geometrically accurate measurement of the neuroretinal rim.<sup>2,3,4</sup>

To assess the thickness of the neuroretinal rim, 24 radial OCT scans centered on the BMO are captured, as visualized by the green lines in *figure 1 (left image)*. The white arrow in *figure 1* indicates the BMO-MRW, which is the shortest distance between BMO and the ILM (*right image*). The average thickness of the neuroretinal rim is then calculated for each sector of the ONH and displayed as a thickness profile (*figure 2*) and a classification chart (*figure 3*).

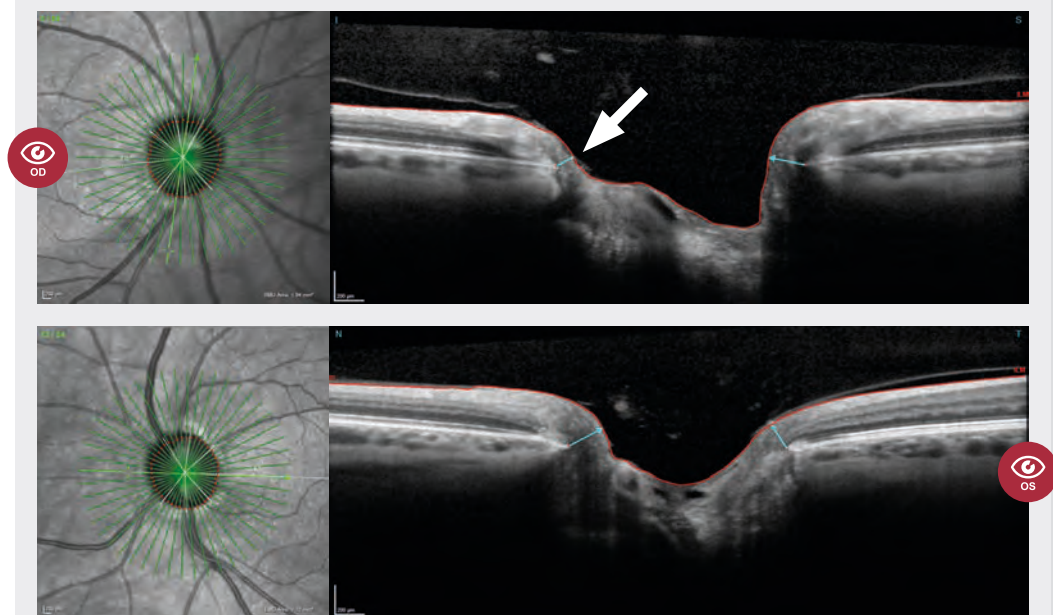
In a healthy eye, the thickness profile of the BMO-MRW should show a slight double hump. Tilted and myopic discs may exhibit an altered profile with a single hump.

In this case study, the thickness profile indicates significant loss of neuroretinal rim in the temporal inferior sector and focal loss in the nasal superior sector of the right eye (*figure 2 – OD black and grey arrows*). The inferior neuroretinal rim thinning can clearly be seen in the OCT image (*figure 1 – OD white arrow*). The average thickness value in the temporal inferior sector in the right eye classification chart is displayed at 158  $\mu\text{m}$  and the percentile value is marked as <1% (*figure 3 – OD black arrow*). This means that 99% of individuals in the age-and BMO-area adjusted RDB have a neuroretinal rim measurement that is greater than this value and less than 1% have a neuroretinal rim measurement that is lower than this value. A percentile value of <1% is colored red, <5% is colored yellow, and >5% is colored green.

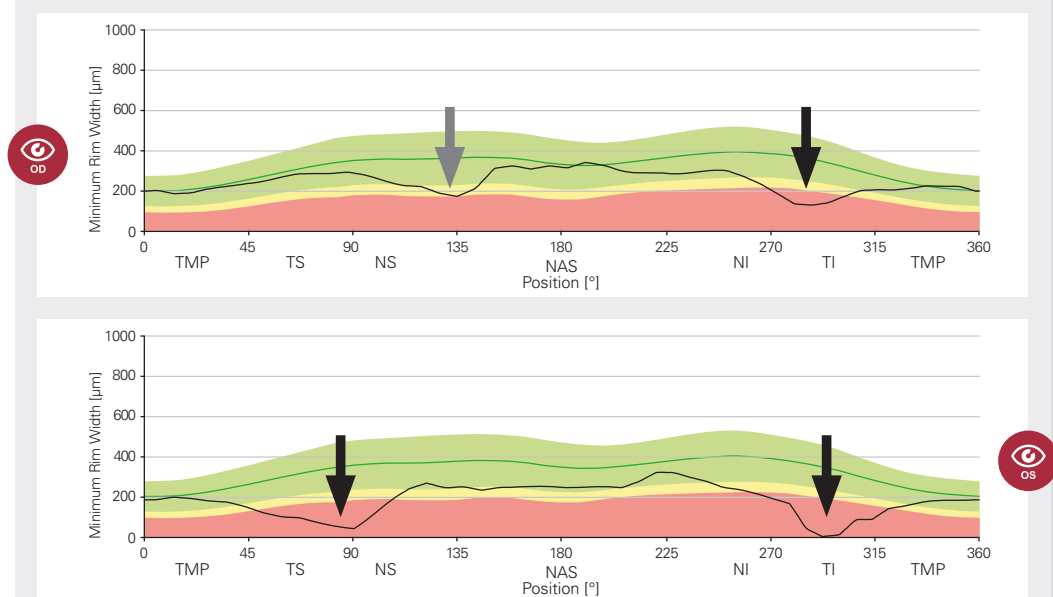
Notice that the nasal superior (NS) sector of the classification chart for the right eye is colored green (*figure 3 – OD grey arrow*), despite there being a clear dip in the corresponding area of the thickness profile (*figure 2 – OD grey arrow*). Closer inspection of the NS sector of the classification chart reveals a percentile value of just 7% (*figure 3 – OD grey arrow*). This highlights the importance of interrogating all of the available data rather than relying on color-codings. In the left eye, there is more significant loss of superior and inferior neuroretinal rim (*figure 2 & 3 – OS black arrows*).



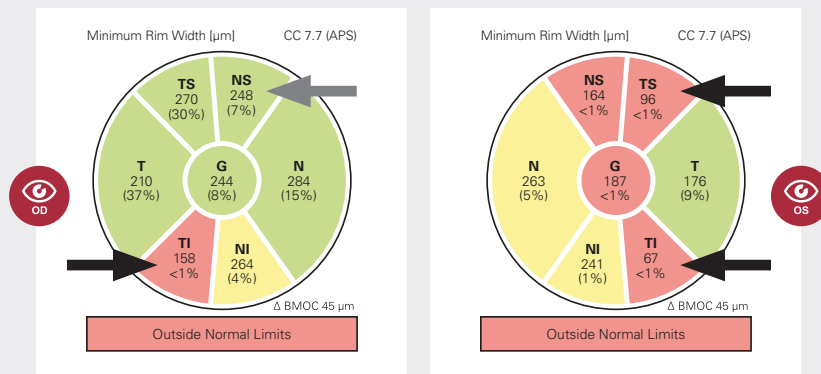
**Figure 1**  
BMO-MRW  
OCT scan

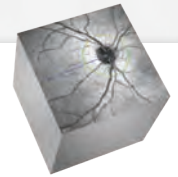


**Figure 2**  
BMO-MRW  
thickness  
profiles



**Figure 3**  
BMO-MRW  
classification  
charts



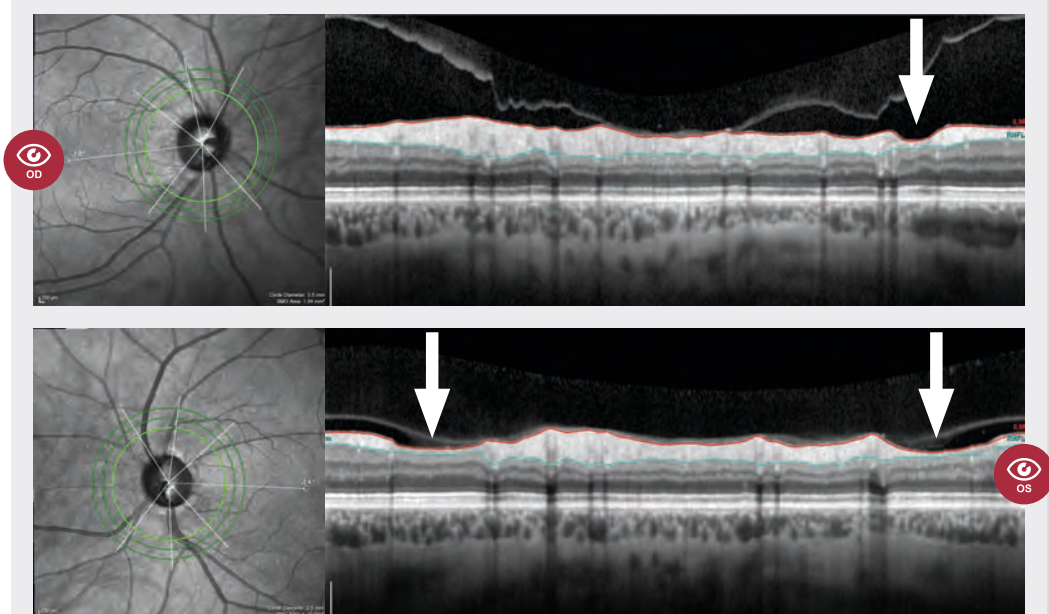


## Retinal Nerve Fiber Layer (RNFL) Thickness

A BMO-centered OCT scan of the RNFL is taken in a circular pattern as visualized by the bright green circles in *figure 4 – left image*. This circle is then “unrolled” and displayed as a horizontal OCT scan (*figure 4 – right image*). This allows you to view the condition of the circumpapillary RNFL (cpRNFL) in a single shot. This information is displayed in the temporal-superior-nasal-inferior-temporal (TSNIT) order (from left to right), generating a TSNIT thickness profile (*figure 4 – right image*).

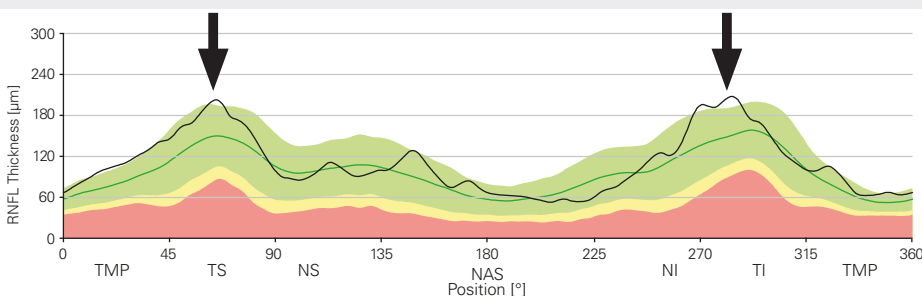
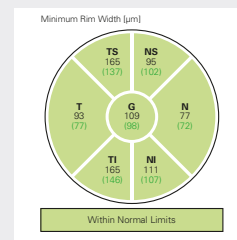
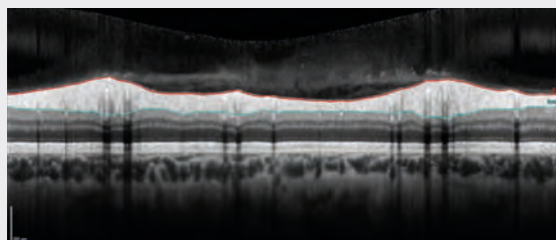
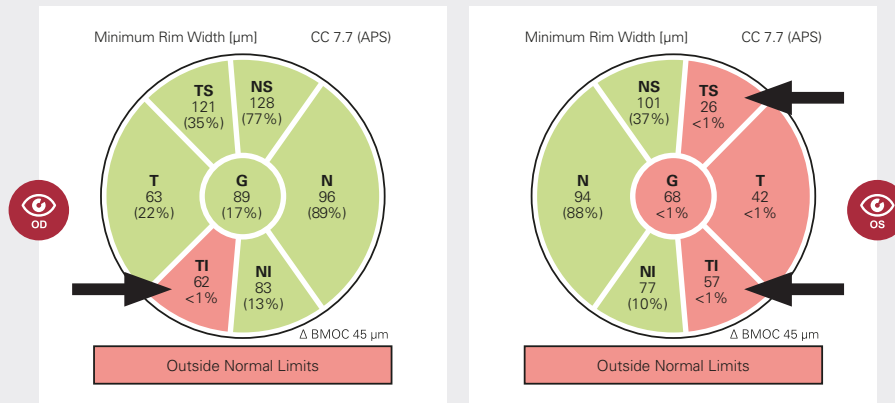
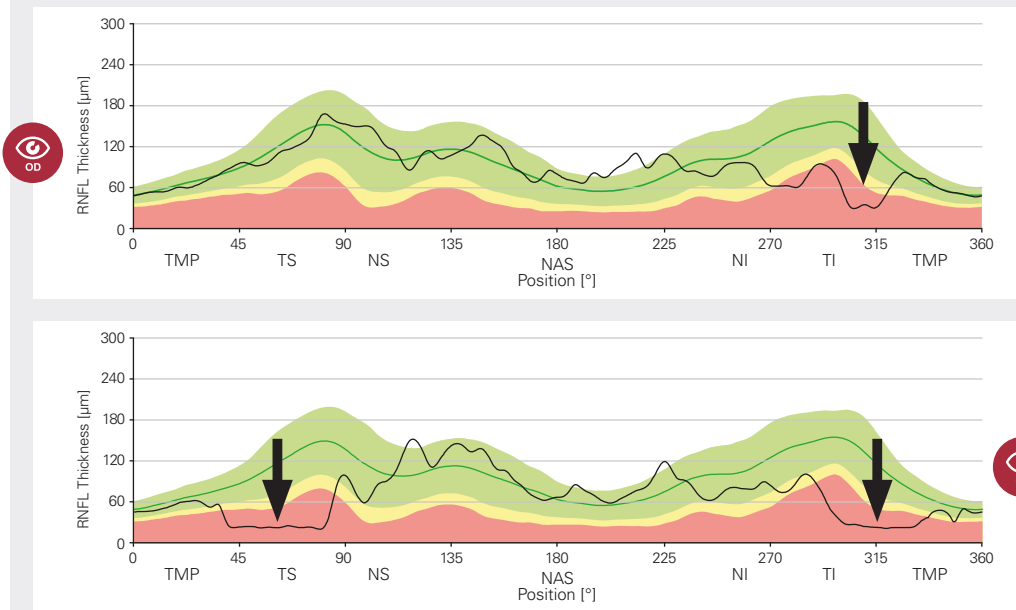
The average thickness of the RNFL is calculated and displayed in the thickness profile (*figure 5*) and classification chart (*figure 6*). In a healthy eye, the thickness profile should present as a “double hump” configuration (*figure 7 – an example of a healthy eye with two humps that are indicated by the black arrows*). Bear in mind that the RNFL profile can be impacted by the vascular anatomy of the retina (e.g. vessel configuration).


In this case study, there is significant temporal inferior thinning of the RNFL in the right eye (*figures 5 & 6 – OD black arrow*). This corresponds with the temporal inferior neuroretinal rim thinning (*figure 1 – OD white arrow*). The thin RNFL in the right eye is clearly visible in the OCT image (*figure 4 – OD white arrow*). The left eye shows significant loss of the temporal RNFL, consistent with severe glaucomatous damage (*figures 4, 5 & 6 – OS white/black arrows*).



**Figure 4**  
RNFL OCT  
scans







## □ Structural Assessment of the Macula\*

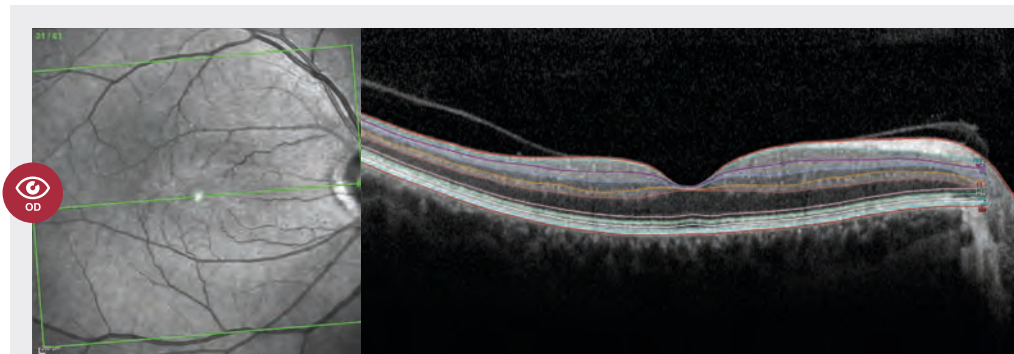
To calculate retinal thickness and asymmetry, a single “posterior pole” volume scan comprised of 61 OCT scan lines (B-scans) is taken across the macula and segmented into individual retinal layers (*figure 8*).

The deviation map tab includes a thickness map, thickness deviation map, and classification chart (*figure 9*). The thickness deviation maps of the total retina, RNFL, ganglion cell layer (GCL) and inner plexiform layer (IPL) reveal regions and patterns within these retinal layers that have significantly thinner or thicker measurement values when compared to eyes included in the RDB and highlight areas that are not within normal limits.

Research has shown that the human brain perceives changes in the lightness parameter as changes in the data much better than changes in hue. The thickness maps utilize a “perceptually uniform” color scale based on the range of values from the reference database (*figure 9 – left images*). This color gradient offers the most visually accurate and easily perceived representation of the thickness of each retinal layer. These perceptually uniform color-coded maps may make structural changes clearer to the human eye in comparison to thickness maps with the standard hue color scale (*e.g. figure 11*). Thicker areas are indicated by white and warm red/yellow colors, while thinner areas are indicated by cool blue colors.

The RDB-derived thickness deviation maps color-code the thickness values of a given layer to highlight whether they are within normal limits, borderline or outside of normal limits making the regions and extent of structural thickening or thinning clearly discernible (*figure 9 – middle images*). Red and yellow areas represent percentile values of <1% and <5% respectively while blue and purple areas represent percentile values of >95% and >99% respectively. Note that it is common to see blue and purple colors due to the presence of blood vessels. Green areas represent a percentile value between 5%-95%.

The 6-sector Garway-Heath grid is anatomically aligned with the RDB using the APS and the results are displayed as a classification chart (*figure 9 – right images*). The grid has been optimized for GCL thickness so there is no RNFL color-coded classification chart. This is because the macula RNFL is anatomically thin, which limits the reliability of measurements in this location and because RNFL defects are typically most prominent beyond the confines of the GCL-optimized grid.



**Figure 8**  
Segmented  
posterior pole  
scan of the  
macula

\*Deviation maps and deviation maps with macula change analysis are not available for sale in the United States.

**Figure 9**

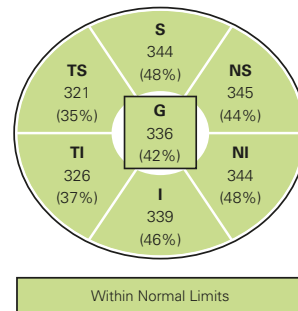
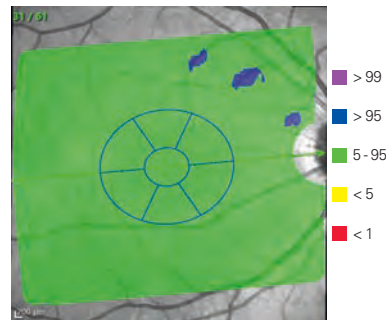
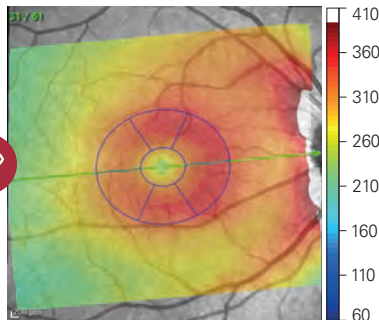
Thickness map, thickness deviation map\*, and classification chart of a healthy eye

Thickness map

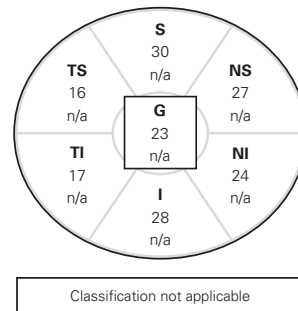
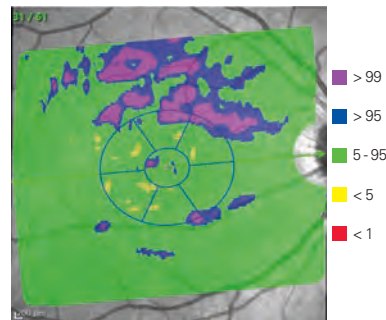
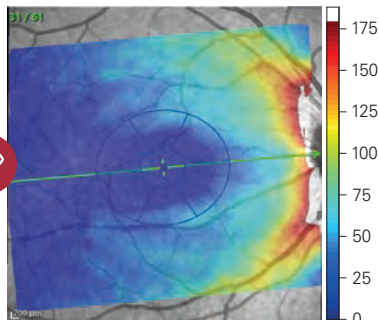
Thickness deviation map

Classification chart

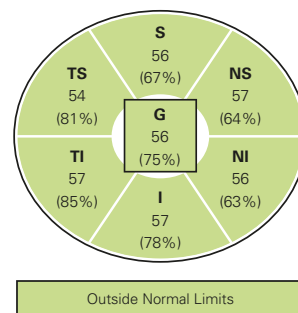
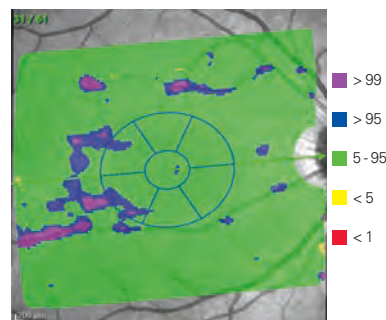
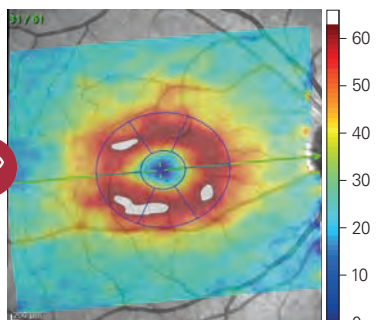
**A**  
Retina



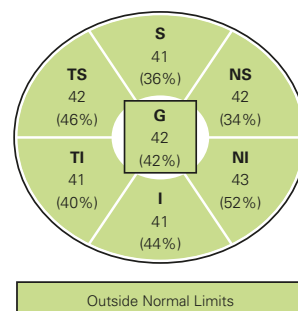
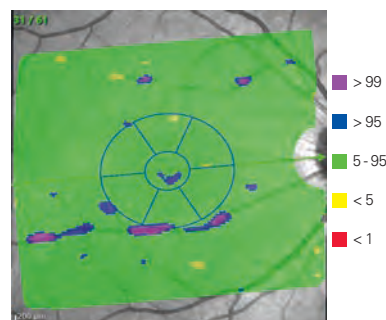
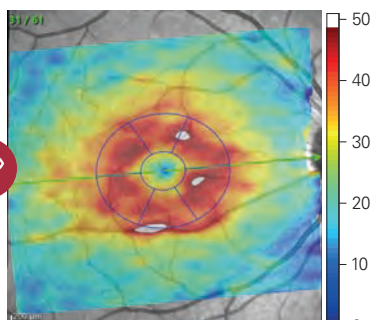
**B**  
RNFL



**C**  
GCL




**D**  
IPL



\*Thickness deviation maps are not available for sale in the United States.





## □ Structural Assessment of the Macula\*

In this case study, a suspicious arcuate (curved) pattern of thinning can be seen in the retina thickness map (*figure 10 – A, white arrow*).

The retina thickness deviation map highlights its arcuate nature, reveals thickness values beyond normal limits, and confirms the extent of thinning. The RNFL and GCL thickness maps (*figure 10 – left images B & C*) confirm that this loss of retinal tissue is specific to the retinal ganglion cells and representative of glaucomatous damage, while the corresponding thickness deviation maps accentuate the region and extent of the pattern of damage (*figure 10 – middle images B & C*).

The GCL and IPL classification charts (*figure 10 – right images C & D*) reveal the temporal inferior region is outside of normal limits. While the temporal inferior sector in the retina thickness classification chart is color-coded green (*figure 10 – right-hand image A*), the percentile value is low at 9%, highlighting the benefit of interrogating all of the available data in detail rather than reliance on color-coded classifications alone.

The left eye (not pictured) revealed more significant loss across all the maps, consistent with severe glaucomatous damage. This pattern confirms the loss that is seen in the BMO-MRW, RNFL and posterior pole OCT images.

\*Deviation maps and deviation maps with macula change analysis are not available for sale in the United States.

**Figure 10**

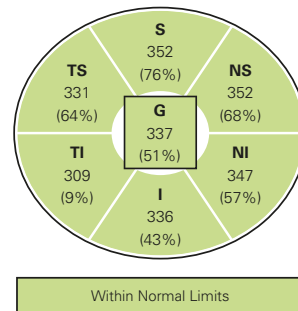
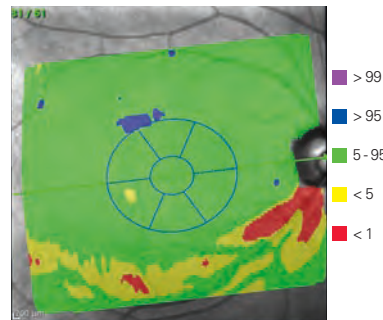
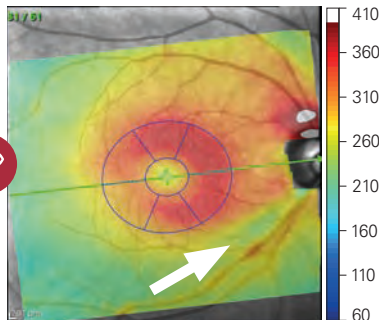
Thickness map, thickness deviation map\*, and classification chart

Thickness map

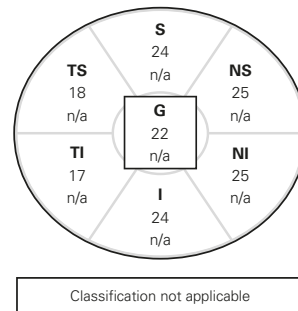
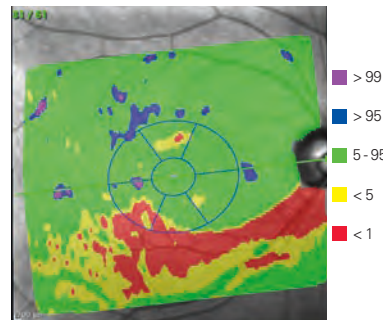
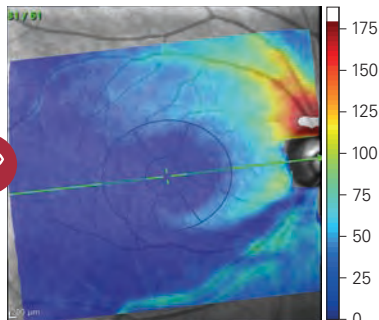
Thickness deviation map

Classification chart

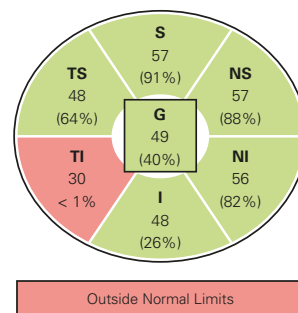
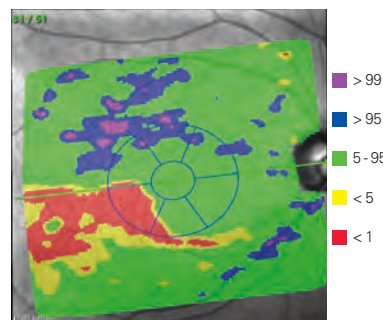
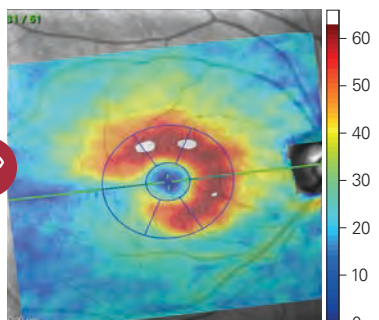
**A**  
Retina



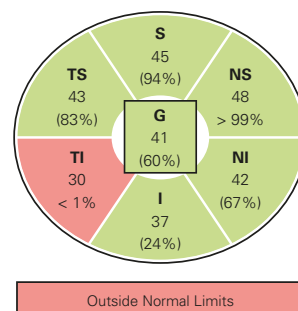
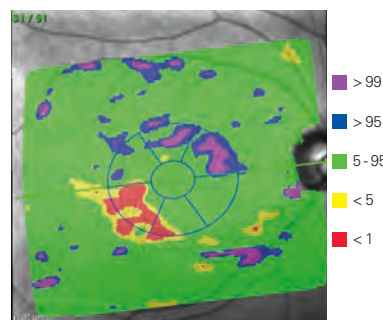
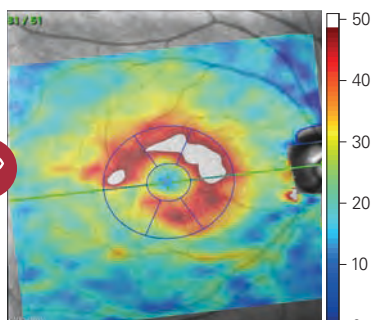
**B**  
RNFL




**C**  
GCL



**D**  
IPL



\*Deviation maps and deviation maps with macula change analysis are not available for sale in the United States.



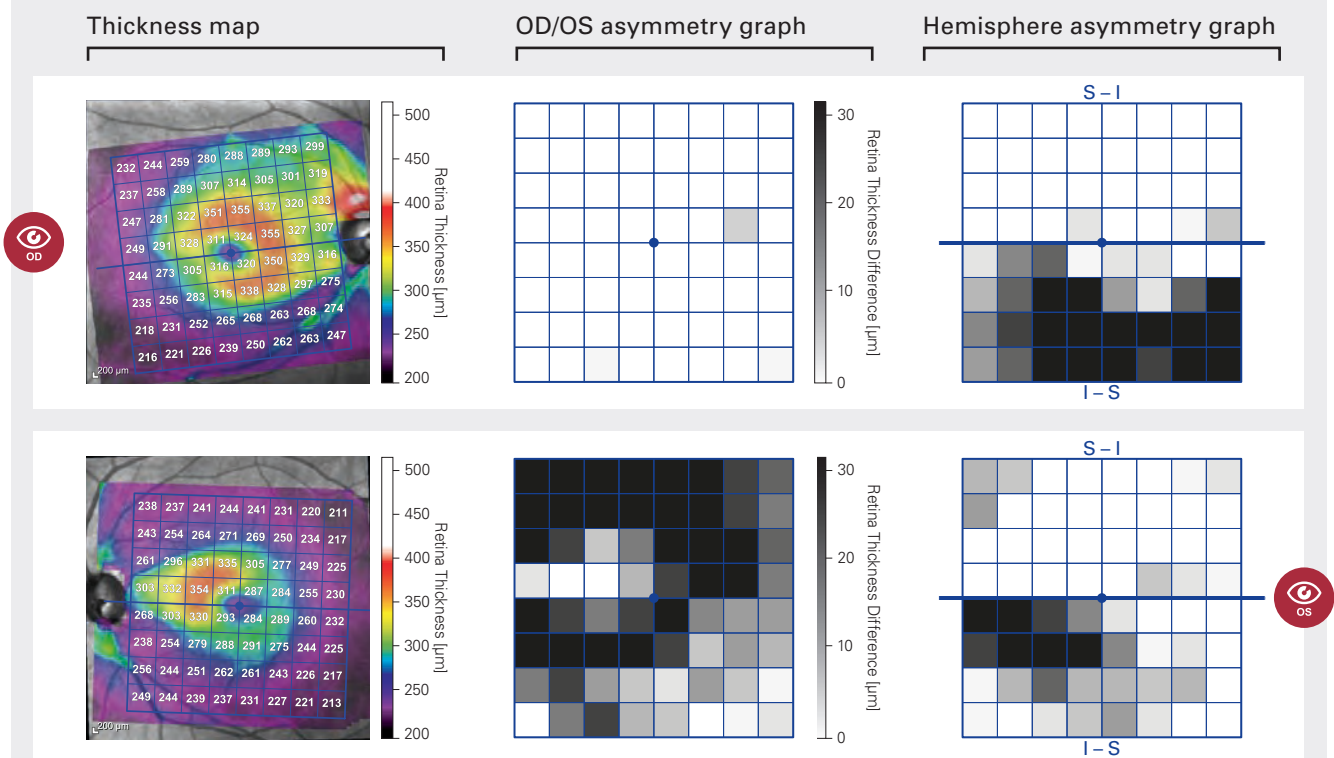
## Posterior Pole Asymmetry

Asymmetry is a hallmark of glaucoma. The full retinal thickness asymmetry analysis quantifies imbalances between the inferior and superior macula, as well as between the left and the right eye, serving as an aid in identifying potential glaucomatous damage.


In the posterior pole asymmetry analysis (derived from the same OCT volume scan as the deviation maps), the total thickness of the retina is calculated and displayed in a color-coded map (*figure 11 – left images*). In this glaucoma patient, the superior and inferior hemispheres present with asymmetric retinal thinning in both the left and right eye (*figure 11*). The superior hemisphere is overall thicker than the inferior hemisphere in both eyes (indicated by the warm red/yellow colours). You will also observe that there are asymmetric thickness values between the left and right eye. The left eye is further progressed and there is a larger area of thin retina (indicated by blue/purple colors) in comparison to the right eye.

A thickness asymmetry graph between the inferior and superior macula hemisphere of each eye (*figure 11 – right images*), and between the right and left eye (*figure 11 – middle images*), is also available. The darker the square, the larger the difference in thickness between that square and the corresponding square in the opposite hemisphere or eye. The hemisphere and OD/OS asymmetry graphs (*figure 11*) confirm there is marked asymmetry between the superior and inferior hemisphere in both eyes and between OD/OS, with jet black squares indicating a difference of  $>30 \mu\text{m}$ .

**Figure 11**







# The Hood Glaucoma Report



GUJI ENGINEERING  
HEIDELBERG

DO

**Sex:** F

**Sex:**

**DOB:** 01.Dez.1954

**Exam.:** 10.Nov.2015

**Comment:** ---

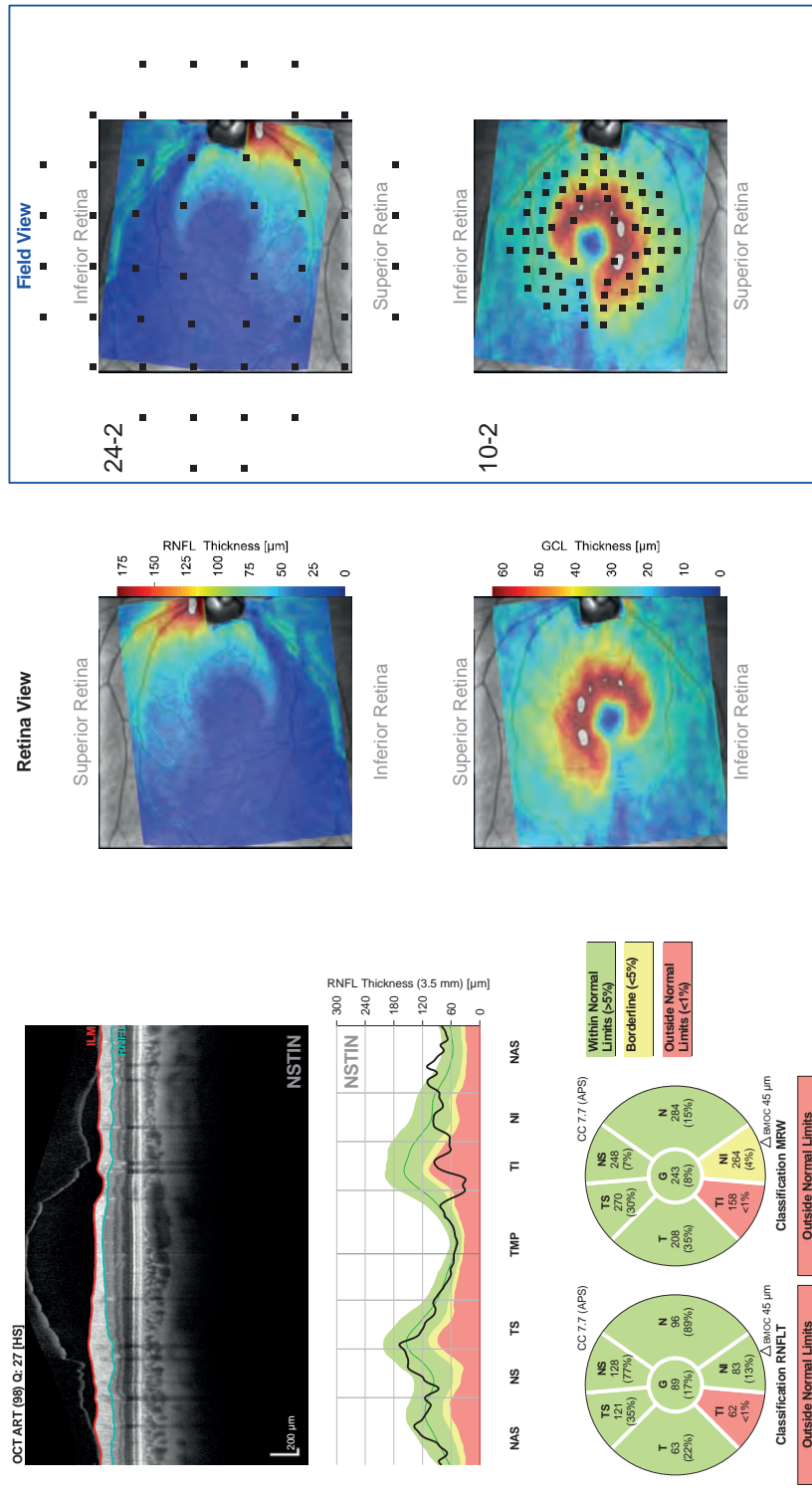
## Hood Glaucoma Report

SPECTRALIS® Tracking Laser Tomography


**Patient:** Glaucoma Imaging Atlas, Chapter - 7, Case - 11

Patient ID: Hood, Ritch

**Diagnosis:** ---



**Figure 12**  
The Hood  
Glaucoma  
Report



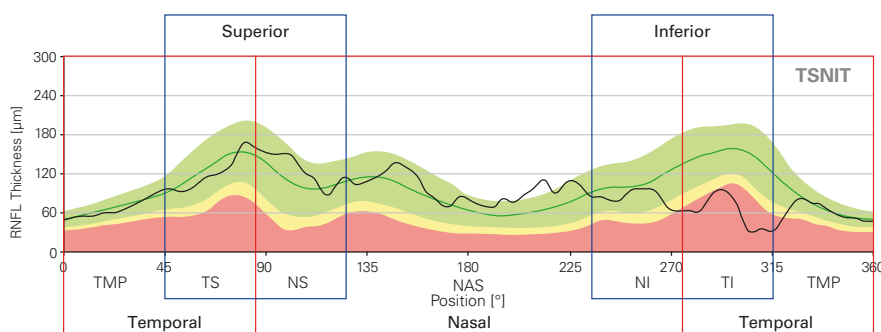
## The Hood Glaucoma Report

The GMPE Hood Glaucoma Report (*figure 12*) combines and organizes the most pertinent OCT data from the ONH, RNFL and macula for detecting glaucomatous damage and empowers you to relate this information to visual field data in a clinically effective manner.

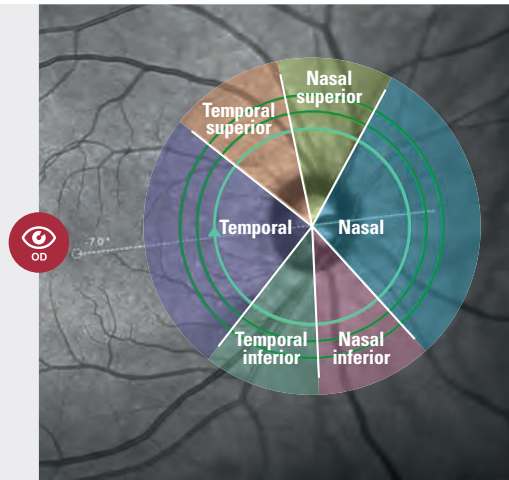
The conventional way to illustrate RNFL thickness data is using a TSNIT RNFL profile (*figure 13*). This profile starts at the temporal most point of the disc (*figure 14 – dotted line in the purple quadrant*) and proceeds clockwise from the temporal (T) to superior (S) to nasal (N) to inferior (I) and back to temporal (T) quadrants. The RNFL thickness data that is associated with the nasal half of the disc is therefore presented in the center of the RNFL profile, while the RNFL thickness data associated with the temporal half of the disc is presented on the far right and left of the RNFL profile (*figure 13*). The disadvantage of the TSNIT profile is that making a comparison between RNFL damage and a visual field defect is challenging considering that most of the retinal ganglion cells are located in the macula.

The GMPE Hood Glaucoma Report (*figure 12*) presents the RNFL data using an NSTIN RNFL profile (*figure 15*). This profile starts at the nasal most point of the disc (*figure 14 – dotted line in the blue quadrant*) and proceeds counter-clockwise. This rearranges the RNFL profile so that the RNFL thickness data associated with the temporal half of the disc is presented in the middle (*figure 15*). The NSTIN plot improves the utility of the RNFL information by optimizing its visual presentation in relation to visual field results. In addition, the large, high-quality OCT image on the report confirms the details of the structural damage and accuracy of the segmentation.

In order to intuitively compare structure and function, the RNFL and GCL thickness maps are rotated and overlaid with the visual field test points. 24-2 locations on the RNFL thickness map and 10-2 locations on the GCL thickness maps (*figure 12*). In this case, the spatial agreement between the 10-2 and 24-2 visual field results and OCT thickness maps (*figure 16*) are excellent, especially considering the various factors that can obscure this relationship such as variability in anatomy and visual field testing among individuals.<sup>5</sup>

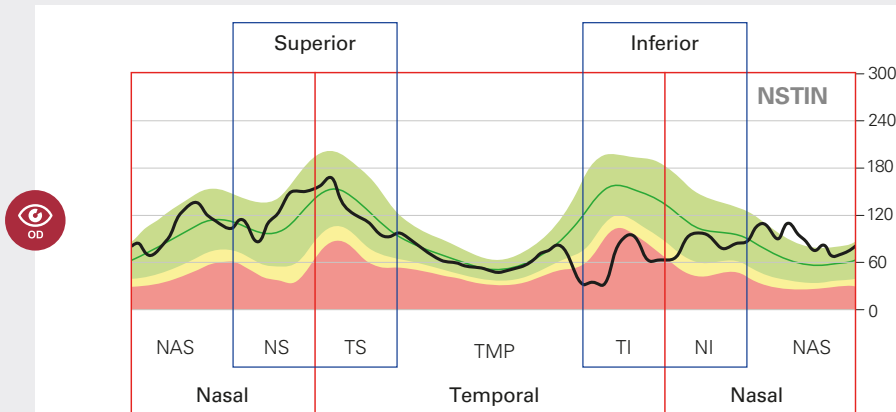


**Figure 13**  
TSNIT RNFL profile of the right eye highlighting where the temporal, nasal, superior and inferior quadrants are located.



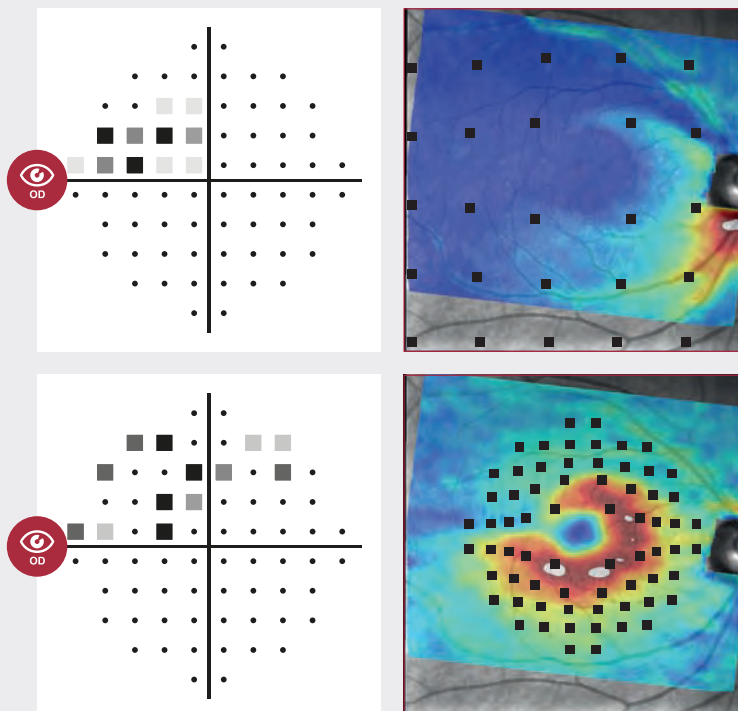
**Figure 14**

A diagram of the right eye showing how the TSNIT quadrants of the ONH relate to the OCT scans.



**Figure 15**


NSTIN RNFL profile for the right eye highlighting where the temporal, nasal, superior and inferior quadrants are located.



**Figure 16**

24-2 SAP (top left) and 10-2 SAP (bottom left) visual field tests of the right eye and corresponding RNFL (top right) and GCL (bottom right) thickness maps with visual field test points overlaid.



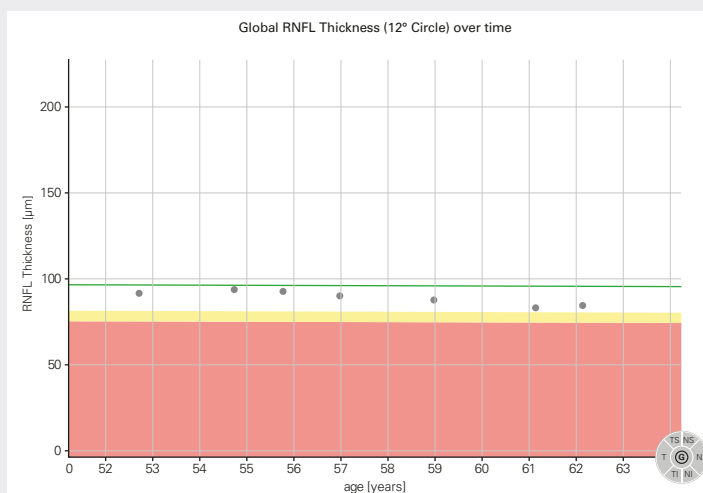


## Progression

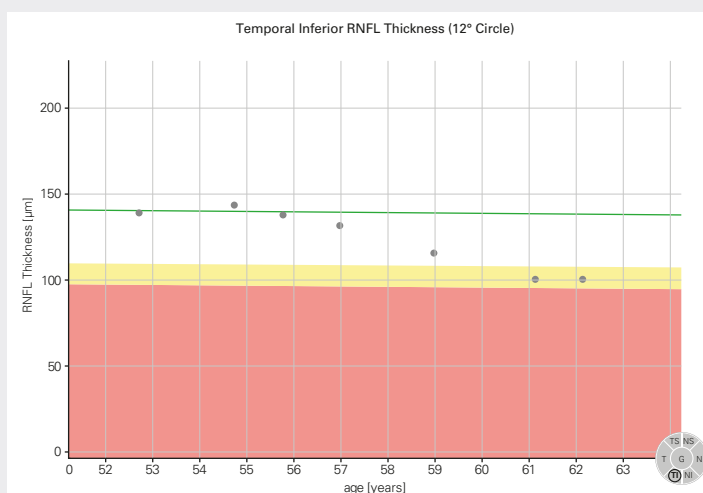
Glaucoma is a progressive disease; therefore, identifying change over time is an important step in confirming a diagnosis and monitoring treatment efficacy. Establishing if there is any progressive loss of tissue over time is useful supporting evidence (*figure 17*). Interrogating the progression in the temporal superior and temporal inferior sectors may reveal a rate of change that is significantly greater than the global average rate of loss (*figure 18*). It is, therefore, important that your OCT device is very accurate during follow-up scanning in order to detect very small changes at the earliest opportunity. SPECTRALIS TruTrack Live Eye Tracking enables the OCT scan to be automatically repositioned at follow-up in the same anatomic location with incredible accuracy and precision<sup>6</sup>, enabling you to see changes as small as 1 micron for confident measurement of disease progression.<sup>7</sup> High repeatability combined with careful review of the OCT B-scans and validation of the automated segmentation will give you confidence that you are looking at real change as opposed to changes induced by operator variability, patient positioning, co-existing pathology or segmentation errors.

**i** Case study used in figures 17 and 18 is different to the case used elsewhere in this guide.

Case study credit: Christian Mardin, MD.



**Figure 17\***  
Global RNFL thinning over time (2008–2017) demonstrated by 7 follow-up examinations.



**Figure 18\***  
Temporal inferior RNFL thinning of the same case as in figure 17 illustrating a greater rate of change.

## Summary

The SPECTRALIS Glaucoma Module Premium Edition provides you with a comprehensive set of parameters for the assessment of structural loss that is characteristic of glaucoma. This multimodal approach empowers you with a toolkit to evaluate both routine glaucoma patients and those who present with a diagnostic conundrum. The result is accurate, objective glaucoma care that is personalized to you and your patient.

For a more comprehensive guide to diagnostic imaging for glaucoma assessment, including 29 case studies, purchase the Glaucoma Imaging Atlas.

You can purchase the Atlas by contacting the Customer Care Team at 1-800-931-2230 (option 2, then press 4).

The information in this document is not intended to be exhaustive and does not cover all eventualities. It is intended as a useful starting point for anyone who intends to integrate OCT information into their clinical diagnostic regimen for the diagnosis and management of glaucoma.

- 1 Jonas, R., et al. Optic Disc – Fovea Angle: The Beijing Eye Study 2011. PLoS ONE, 10: E1041771 (2015).
- 2 Reis, A. et al. Influence of Clinically Visible, But Optical Coherence Tomography Detected, Optic Disc Margin Anatomy on Neuroretinal Rim Evaluation. Invest Ophthalmol Vis Sci 53, 1852-1860 (2012).
- 3 Chen, T.C. Spectral Domain Optical Coherence Tomography in Glaucoma: Qualitative and Quantitative Analysis of the Optic Nerve Head and Retinal Nerve Fiber Layer (An AOS Thesis). Trans Am Ophthalmol Soc 107, 254-281 (2009).
- 4 Povazay, B. et al. Minimum Distance Mapping Using Three-Dimensional Optical Coherence Tomography for Glaucoma Diagnosis. J Biomed Opt 12, 041204 (2007).
- 5 Hood, DC. et al. A test of a linear model of glaucomatous structure-function loss reveals sources of variability in retinal nerve fiber and visual field measurements. Invest Ophthalmol Vis Sci 127, 875–881 (2009).
- 6 Wu, H. et al. Reproducibility of Retinal Nerve Fiber Layer Thickness Measurements Using Spectral Domain Optical Coherence Tomography. J Glaucoma 20, 470-476 (2011).
- 7 Langenegger, J. et al. Reproducibility of Retinal Nerve Fiber Layer Thickness Measurements using the Eye Tracker and Retest Function of Spectralis SD-OCT in Glaucomatous Eyes and Healthy Controls. Invest Ophthalmol Vis Sci. 52. 3338-3344 (2011).



**Headquarters**

Heidelberg Engineering GmbH · Max-Jarecki-Str. 8 · 69115 Heidelberg · Germany  
Tel. +49 6221 64630 · Fax +49 6221 646362

**USA**

Heidelberg Engineering Inc. · 10 Forge Parkway · Franklin, MA 02038  
Tel. +1 800 931 2230 · Fax +1 508 630 7901

**[www.HeidelbergEngineering.com](http://www.HeidelbergEngineering.com)**