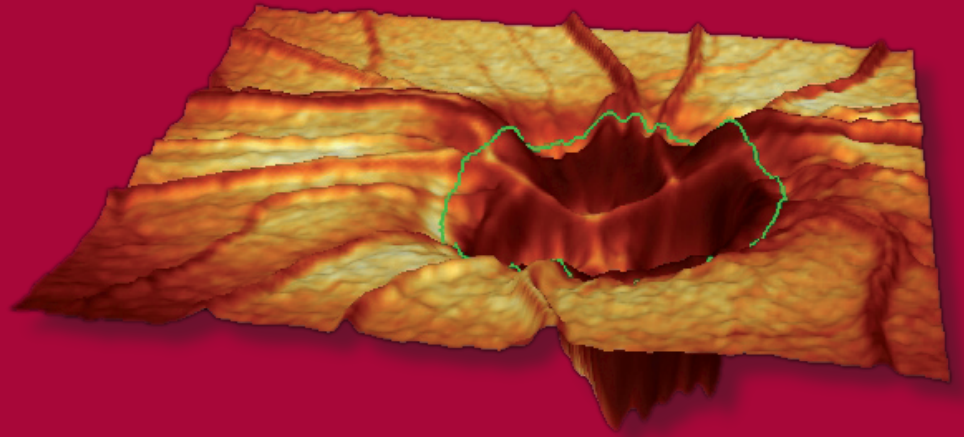


5 Steps to Draw the Contour Line



HGT

5 Steps to Draw the Contour Line

Drawing the contour line in the HRT baseline examination is a prerequisite for two- and three-dimensional description of the optic nerve head using stereometric parameters to measure the individual structures. The same boundary is involved here as in the clinical routine for defining the ratio between cup surface and disc surface. The optic nerve head is restricted by the inner edge of the scleral ring (Elschnig's-Ring).

Remember, the contour line has to be drawn only once for each eye!

Follow-up examinations are automatically aligned with the baseline examination. The contour line can be modified at any time later on. Every modification of the contour line in the baseline or follow-up examinations is transferred directly to all other examinations. Concerns have been expressed as to the subjective nature of defining the contour line. However, studies have been performed to measure the variability between contour lines drawn by different users. The findings showed that contour line placement variability with different operators has little effect on parameter data. Instead, quality of the images had the largest impact on results. (Miglior et al., Ophthalmology 2002 109:1072-1079).

Tools:

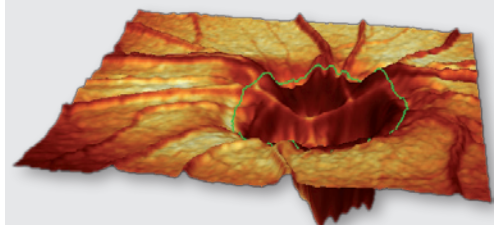
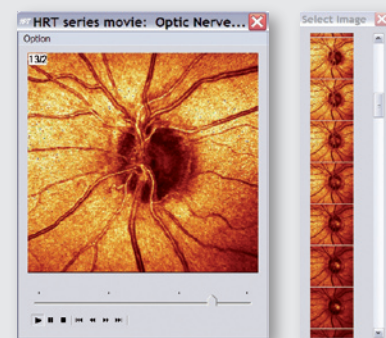
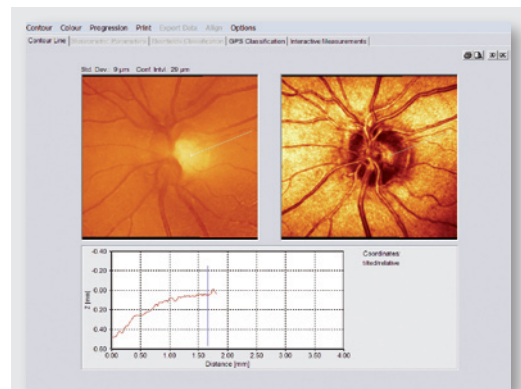
The **topography image** represents the height variations on the retinal surface - pale areas appear to be lower than dark ones. The **reflectance image** reproduces the reflectance of the retinal surface. To detect the disc margin, both the topography image and the reflectance image should be used.

If the disc margins are not clear enough in the mean reflectance image open **series movie** through a right mouse click on the topography icon in the Heyex patient window and display the **movie** next to the contour menu. Use the slider to browse through the image series. Two-dimensional confocal section images can also be displayed, using the **Contour-Select Image Series menu**. If you click on any section, the contour line can be drawn directly on the confocal image. Usually a section can easily be found in which the disc margin or parts of it are shown more sharply in comparison to the mean reflectance image.

In the **black and white view** (Color menu) this disc margin is frequently displayed with more contrast.

The **diagram** below the topography and reflectance images shows the **height profile** of the surface along the white position marker from the center of the optic nerve head to the edge of the image frame. The position marker can be moved freely across the topography and reflectance image. The surface height variation along the position marker and up to the edge of the image is shown in the bottom section of the viewer. A blue vertical line indicates the current mouse cursor position. Also the height of blood vessels will be displayed in the interactive diagram.

In the **3D view** of the optic nerve head the placement of the contour line on the disc margin can be checked. Open the 3D window by a right mouse click on the topography icon in the HEYEX image viewing window selecting "show 3D" or clicking on the 3D button in the upper right corner of the patient result window.



Accept Contour Line Placement

Moving points

An existing contour point can be repositioned by dragging it at the correct position (clicking on it and moving the mouse while holding down the left mouse button). Move the points along the disc margin so that the contour line is approximately circular or oval in shape.

Deleting Points

A right mouse-click opens the **Contour menu** to delete points individually or all at once including the contour line.

Accept Contour

Once the definition of the contour line has been completed, it can be made permanent using the menu item **Accept Contour**.

After the contour line has been accepted, the tabs for stereometric parameters and the Moorfields Classification are now active.

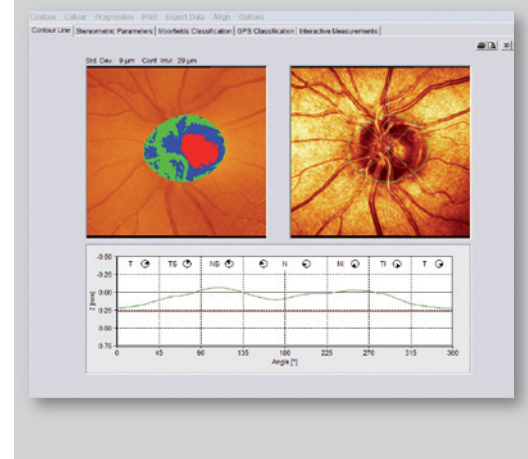
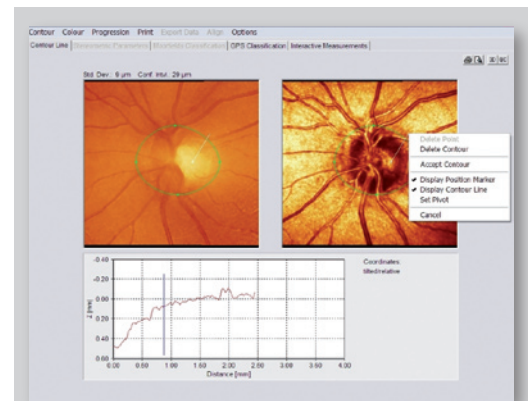
Verify Contour Line Placement

Once the contour line has been drawn (green line), a reference plane (red line) is automatically set 50 microns below the heights measured at the location of the papillo-macular bundle 350-356°. The papillo-macular bundle is known to be the most stable of the nerve fiber bundles and the last to go in glaucoma. So it is a good location to use as a benchmark. Histologically, the papillo-macular bundle is known to be about 50 microns thick at this location and so the setting of the reference plane effectively defines the base of the retinal nerve fiber layer. Everything below the line is defined as “cup” and everything above as “rim”. From the position of the reference plane we can now start to evaluate the ratio of cup to rim for each given disc size.

In the topography image we can now see the area and position of the cup (red) and rim (blue and green combined).

In the graph to the right we see the profile of the retinal nerve fiber layer (RNFL) around the disc margin as defined by our contour line (green). Typically in normal eyes this will show as a “double-hump” shape since the retinal nerve fiber layer is thickest in the inferior and superior locations.

The RNFL profile should not fall below the reference plane (red line). If it does, check the position of the contour line to be sure the disc margin is identified correctly. RNFL profiles which come close to the reference plane are likely indicative of a thinner nerve fiber at that location.



This guide was created to help the user understand the significance of the contour line as well as to recognize the disc margin and to mark it without any doubt. It is not intended to replace personalized training by a Heidelberg Engineering representative.

If you have any questions after reading through this guide, do not hesitate to call us. Hotline +49 (0) 62 21 - 64 63 64 - www.HeidelbergEngineering.com

Only 5 Steps - it's so easy!

Start with defining **four contour points** in the topography and/or the reflectance image where you can easily distinguish the disc margin at the temporal, nasal, superior and inferior borders (0, 180, 90, 270 degrees). If this is not sufficient define only two additional points between some of the first points. Usually, **not more than six points** are required to define the disc contour line.



Step 1:

Topography and reflectance image

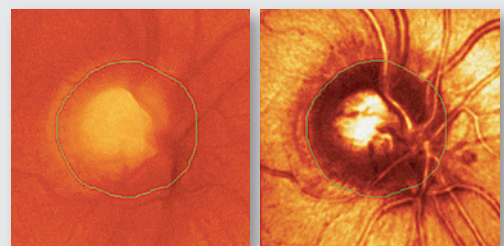
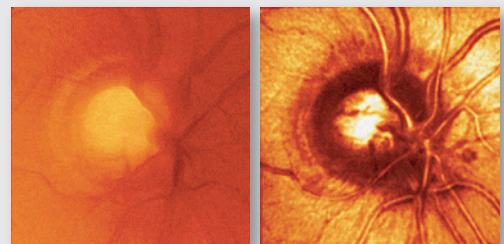
I) Scleral ring

The **scleral ring** frequently appears as a pale band. The **contour line must be placed on the inner edge of the scleral ring**.

In the graph below the topography and reflectance images the interactive height profile shows the scleral ring as a small depression or "dip". **The correct marking of the disc margins is at the maximum height inside of this depression.**

II) Peripapillary atrophy

Discs with **peripapillary atrophy (PPA)** frequently display a band with reduced reflectance between a highly reflective zone and the dark disc margin. **Place the contour line on the inner edge of this band.** Never on the outer margin of the PPA.



Topography Image

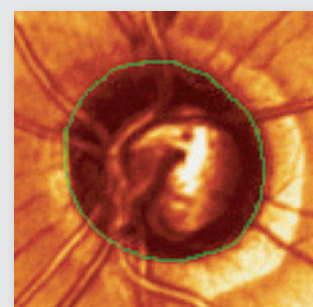
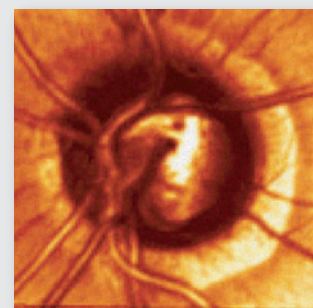
Reflectance Image



Step 2:

Dark edge

The tissue at the disc margin can have different **absorption properties** compared to its surrounding tissue. Therefore, the disc margin might appear as a **dark edge**. Especially in flat optic nerve heads browsing through the confocal scans in the **movie** enables the user to find the borders more easily in a single confocal scan.



Peripapillary atrophy



Step 3:

Symmetry

Blood vessels frequently hide the nasal section of the optic disc. The **form of the disc** is closer to a vertically elongated oval than to a circle. If no other features can be recognized use common sense and match the shape to that which can be seen more easily on the temporal side of the disc. **Symmetry considerations** should be used to continue the contour line to a physiological round or oval shape.



Step 4:

Blood vessels

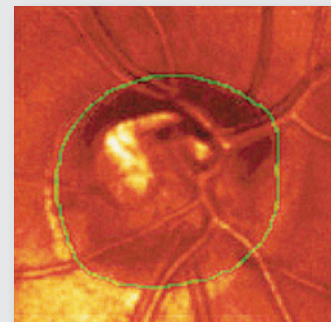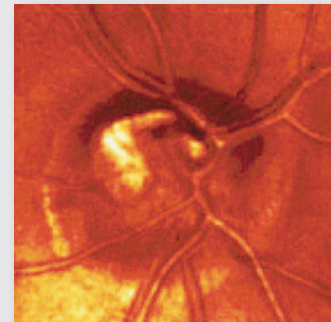Often blood vessels are visibly bending downwards at the disc margin. A **change of direction of the blood vessel** usually occurs in conjunction with a change in the reflection on the ridges of the blood vessels.



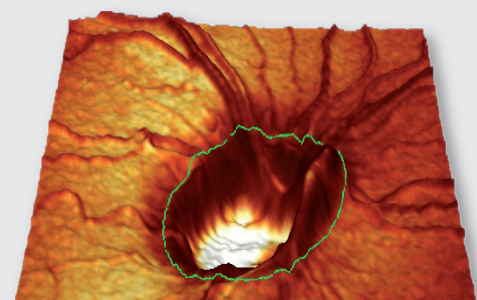
Step 5:

3D view

In the **3D view** the contour line should appear consistently on the edge of the flat retinal tissue. Make sure the contour line is not placed on sloping rim tissue or inside the cup.



Example of a tilted disc with a scleral ring



3D view

Note:

This is particularly important in the area of the papillo-macular bundle between 350° and 356°, where the reference plane is set from the contour line. When in doubt, place the contour line just outside the disc margin rather than too far inside the margin.



Corporate Headquarters

Heidelberg Engineering GmbH · Tiergartenstr. 15 · 69121 Heidelberg · Germany
Tel. +49 6221 6463-0 · Fax +49 6221 646362 · www.HeidelbergEngineering.com

US Office

Heidelberg Engineering, Inc. · 1499 Poinsettia Avenue, Suite 160 · Vista, CA 92081
Tel. +1 760-598-3770 · Fax +1 760-598-3060 · www.HeidelbergEngineering.com